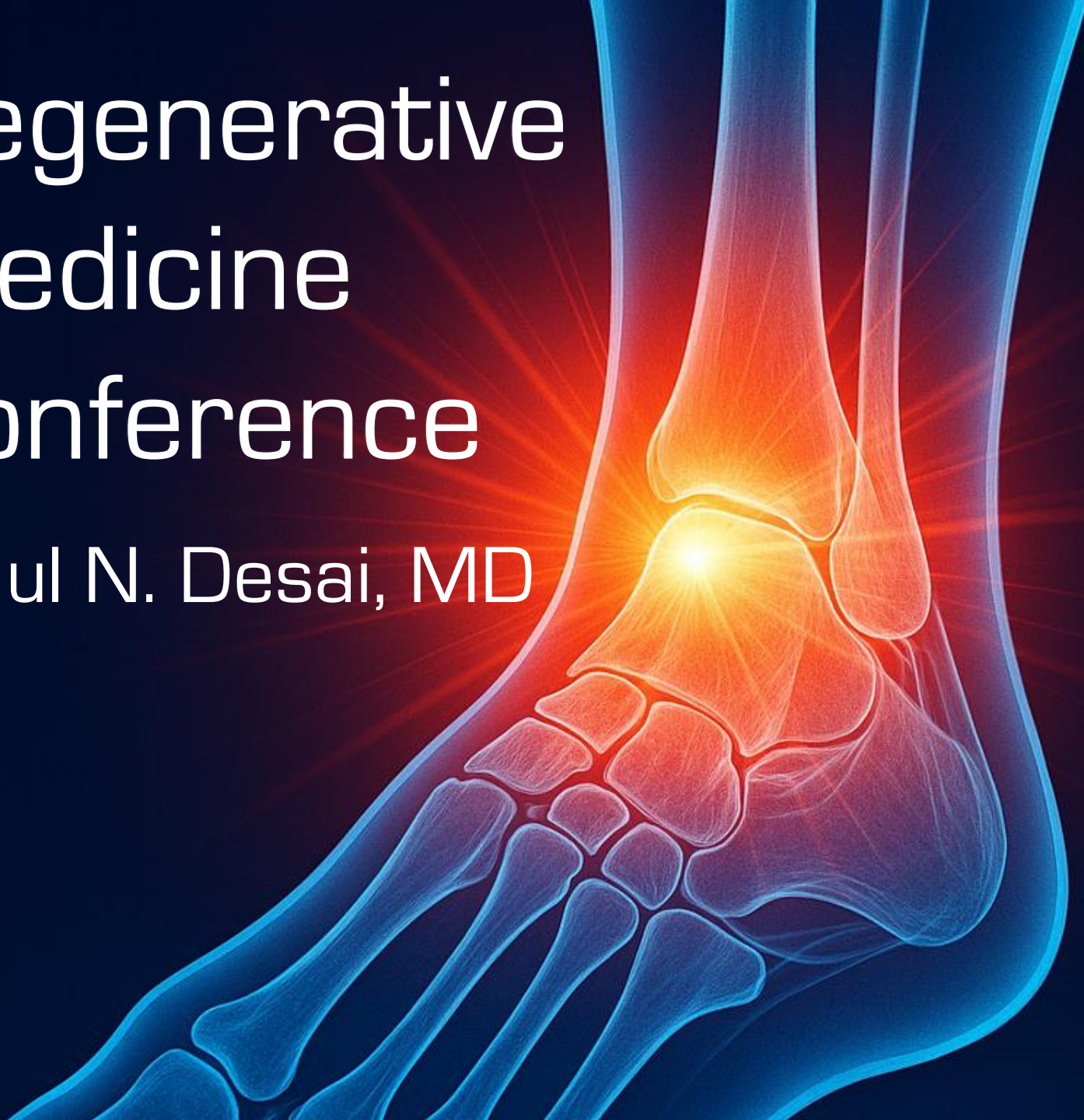

Regenerative Medicine Conference

Rahul N. Desai, MD



Disclosures

- RedVive Health - CMO and Founding Member
- Consultant – Arthrex
- Advisory board – Tendonova

Our talks are about
the
POSSIBILITIES!

OrthoBiologics &
Photobiomodulation

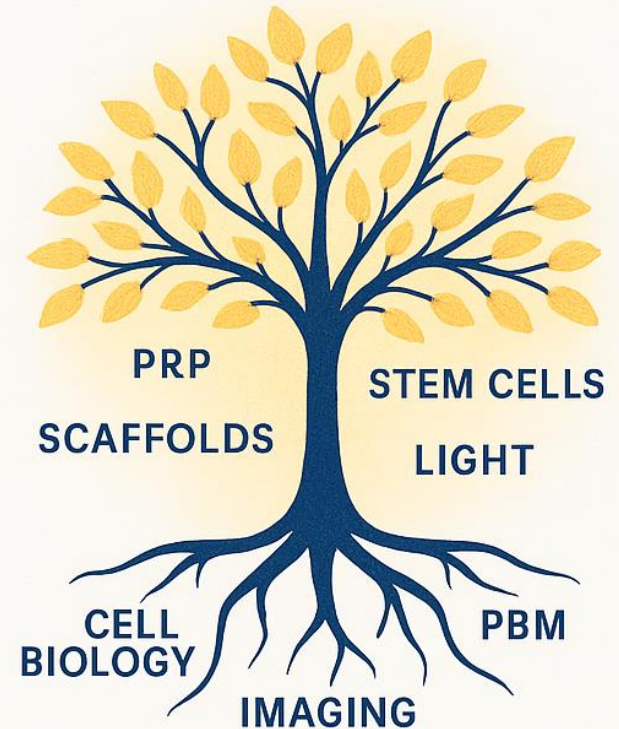


The Purpose of This Lecture

This lecture is not about “which product is best.”

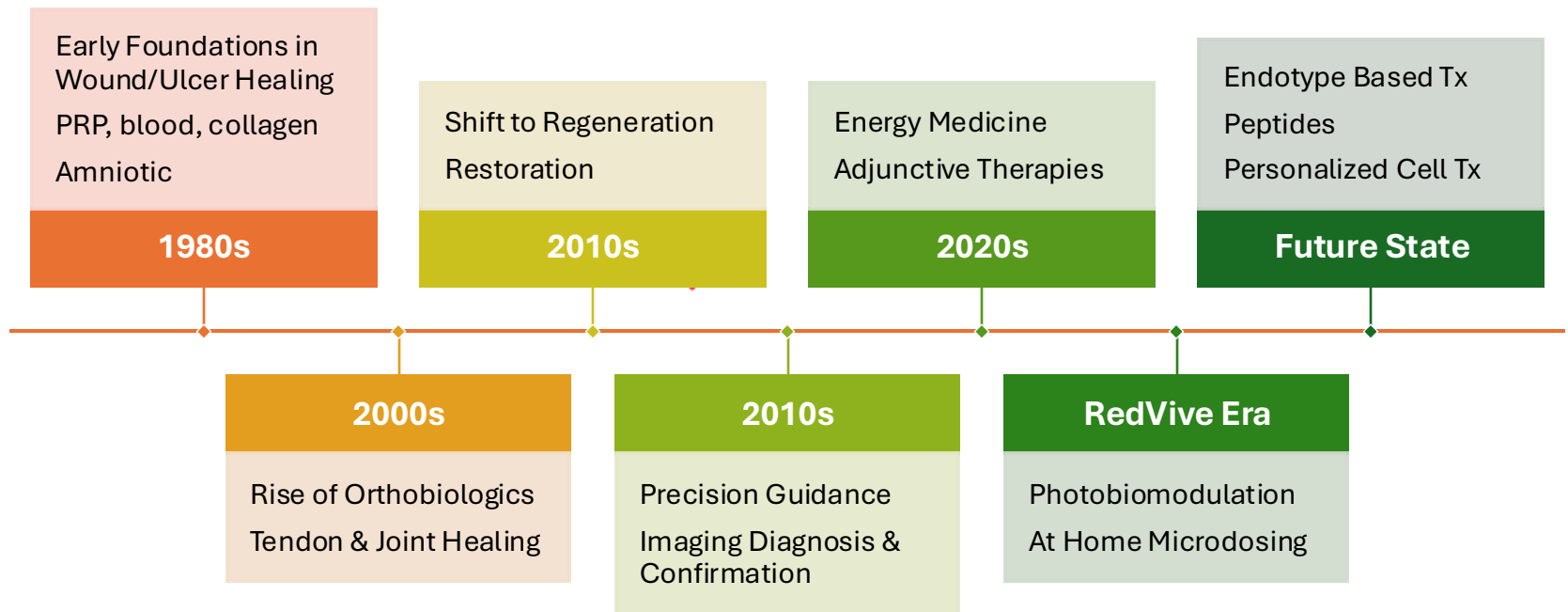
Instead, it’s about building a foundational understanding of regenerative medicine—so you can make informed, indication-specific choices for your patients.

- Understanding core principles of cellular and tissue regeneration
- Learning to match the right biologic or technology to right pathodlogy



Grow your foundation
before choosing your branch

Timeline of Regenerative Medicine – Autologous Products



My Story: From Radiologist to Regenerative Specialist



Diagnostic & interventional radiology
→ specialized in spine & joints



First exposure - Limits of steroids & surgery → search for biologic alternatives



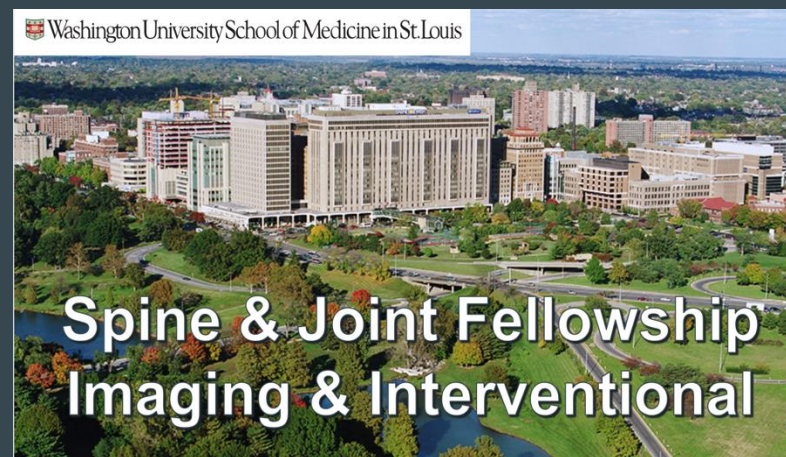
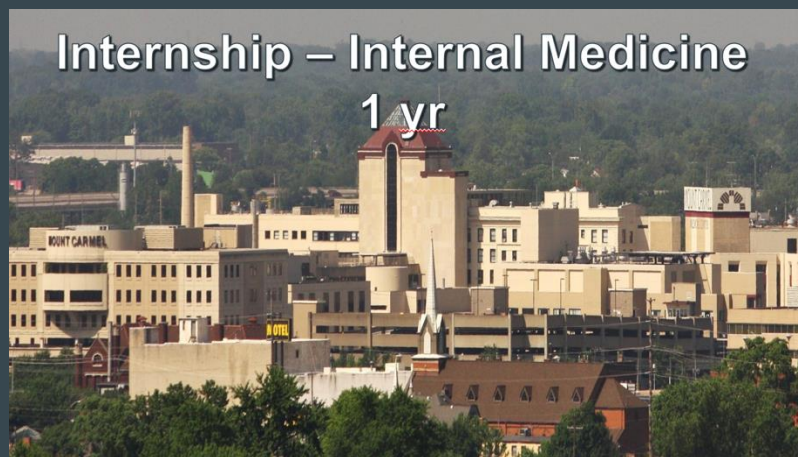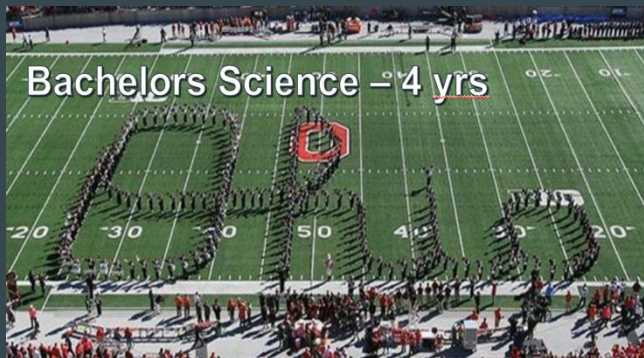Early adoption: Among first radiologists to use imaging-guided PRP & stem cell injections



Precision model: Precision diagnosis, precision biologics, precision delivery”



Impact: Thousands of image-guided regenerative cases, publications, global lectures, advisory roles



14 years of school & training!!!



I was REALLY GOOD AT:

1. FIGURING OUT WHAT WAS WRONG WITH
SOMEONE

2. PRECISELY PLACING A NEEDLE AND
MEDICINE INTO THE INJURED AREA

BEFORE REGEN



Physiotherapy



Medications –
NSAIDS, Narcotics,
Pain Relievers



Surgery

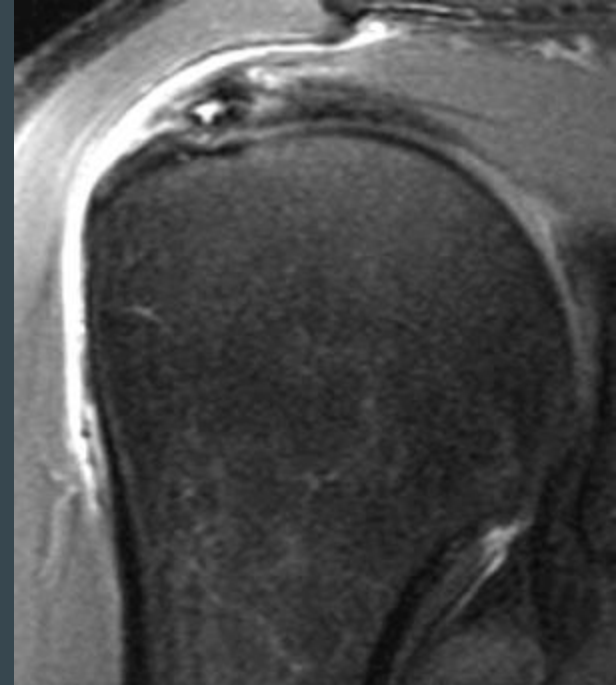
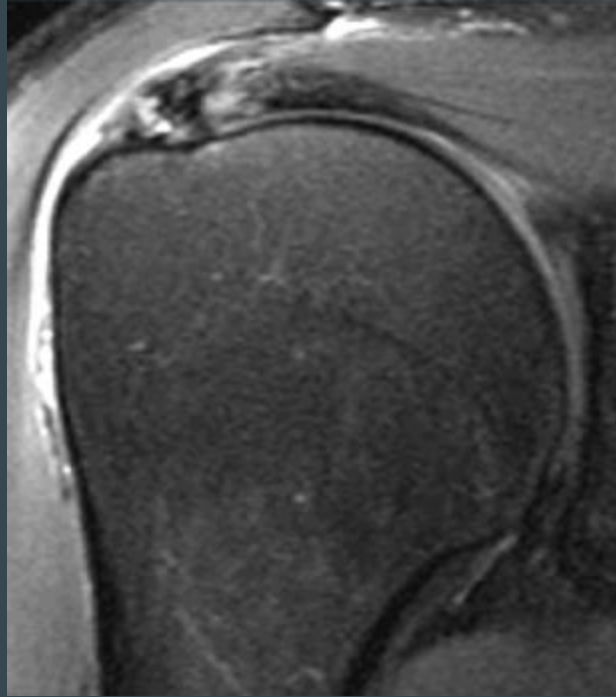
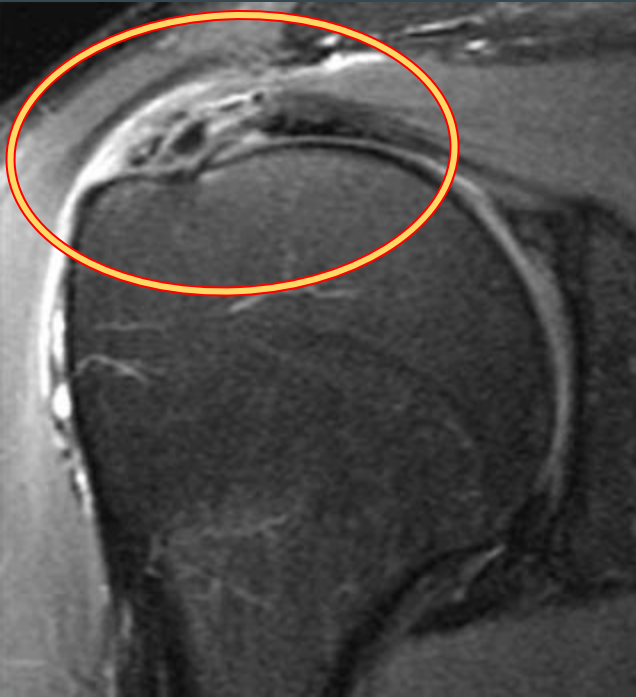
Alternative Medicine
Therapies



Steroid Injections



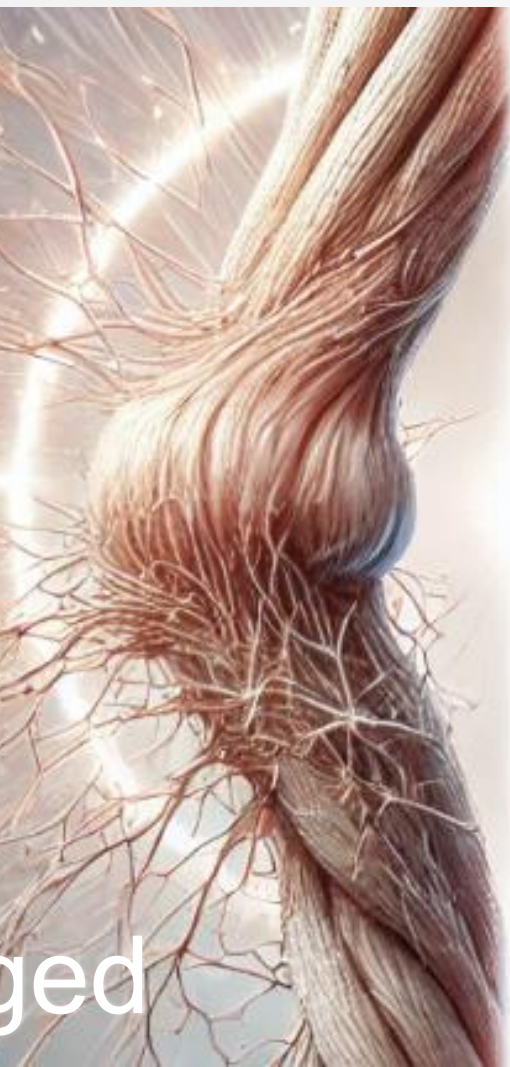
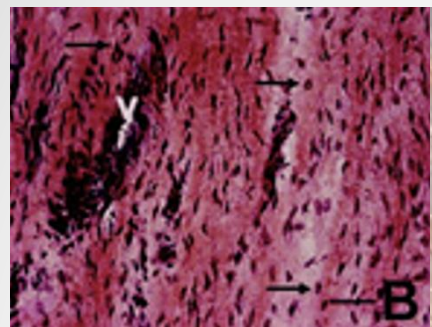
Male With Shoulder Pain and Calcific Tendinitis of Partial Tears Supraspinatus Tendon





TAKING THE LEAP

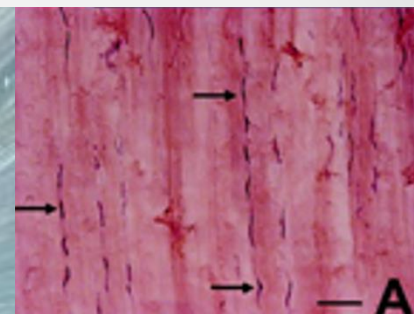
2009



Damaged

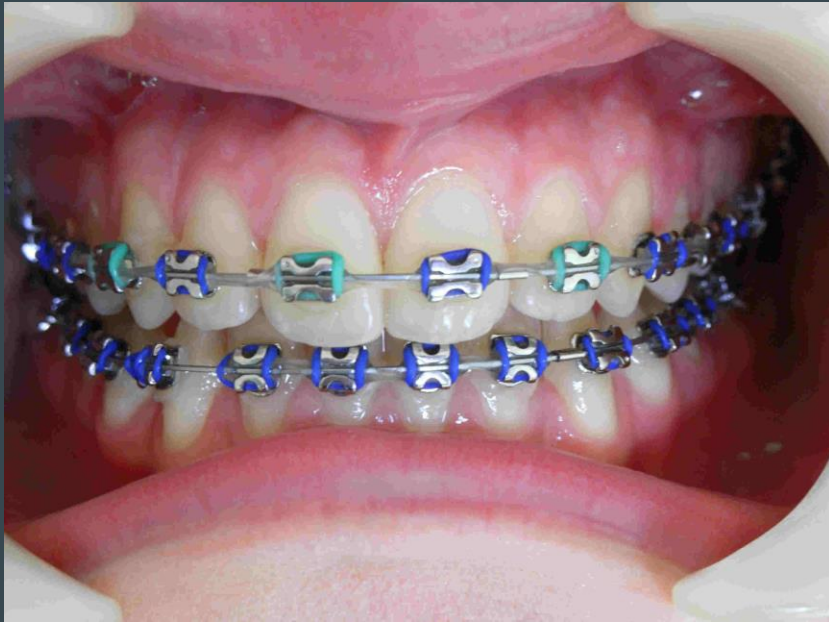

Healing



- 30 years of experience

Safety Profile



Successful Regenerative Medicine Therapy

Precision Diagnosis

History, Physical Exam,
Diagnostic Imaging &
Injections

Precision Diagnosis

Precision Biologics

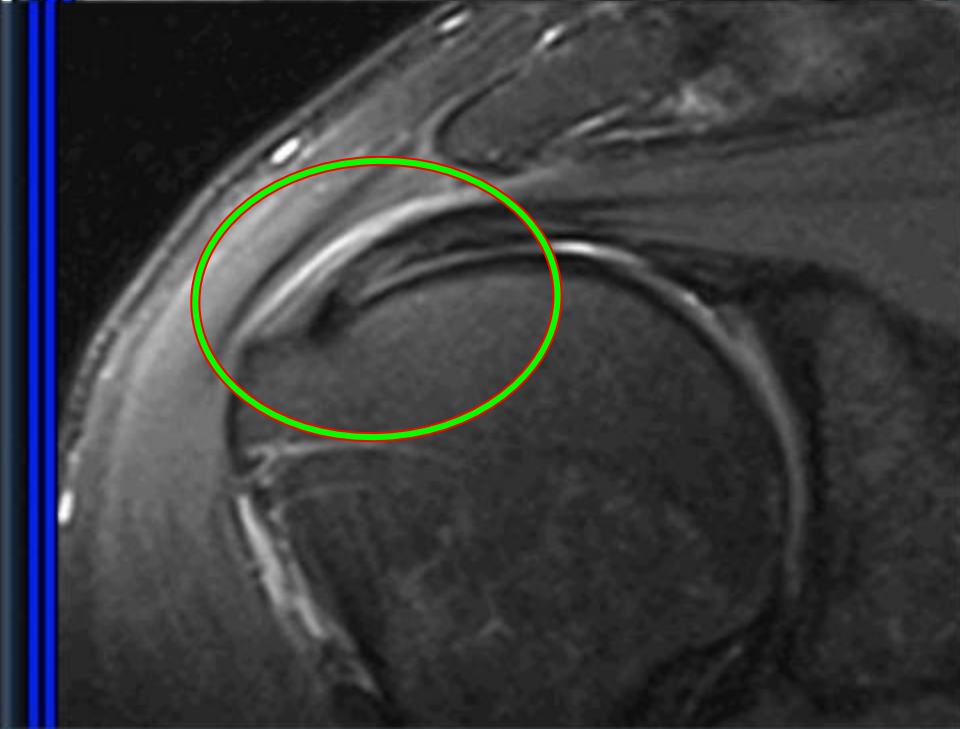
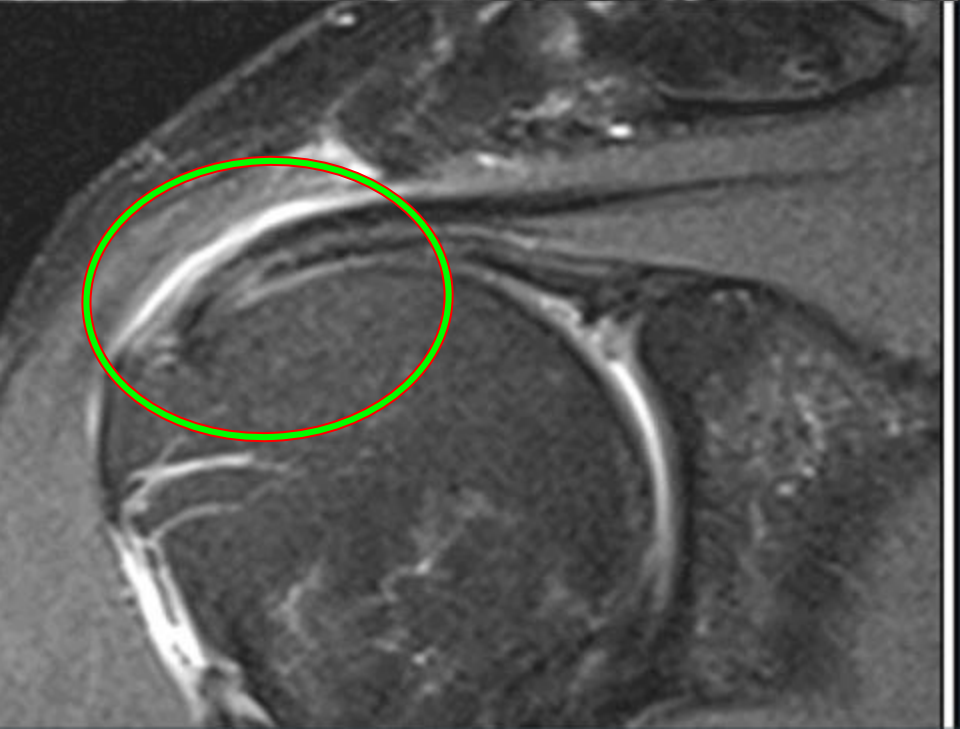
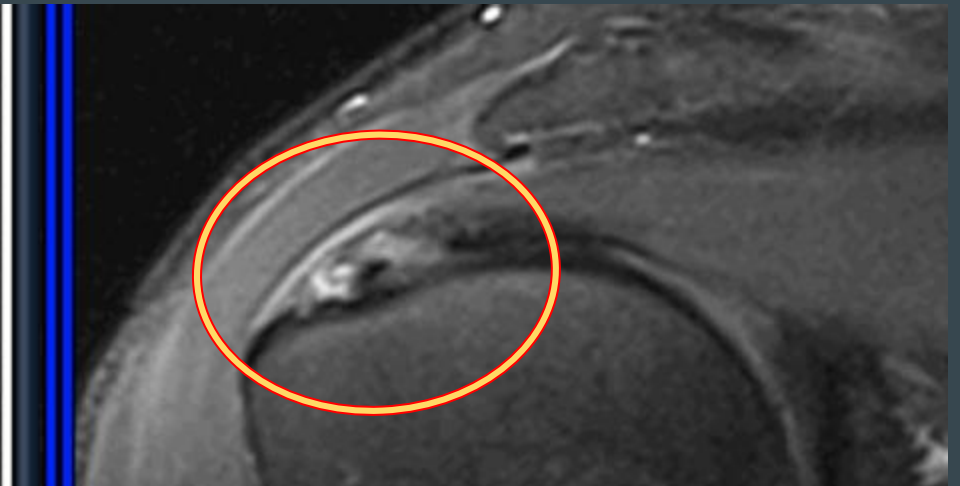
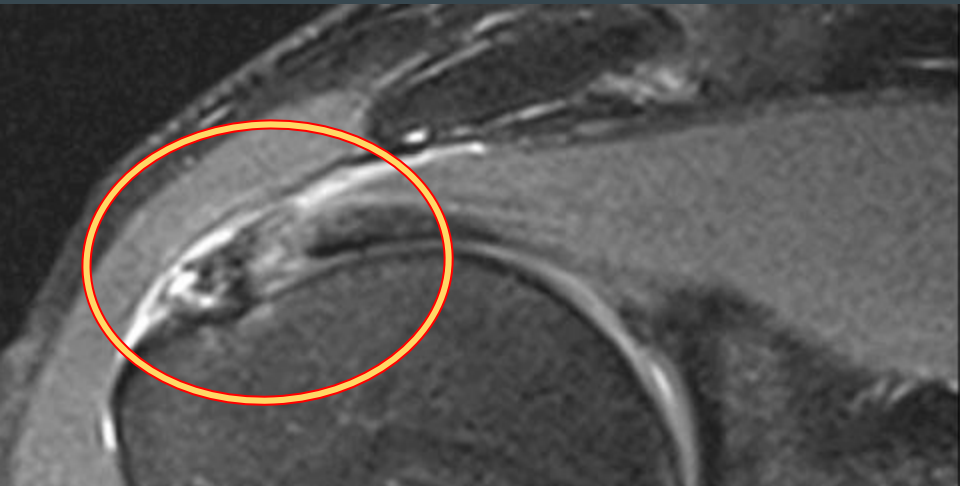Precision Delivery

Precision Delivery

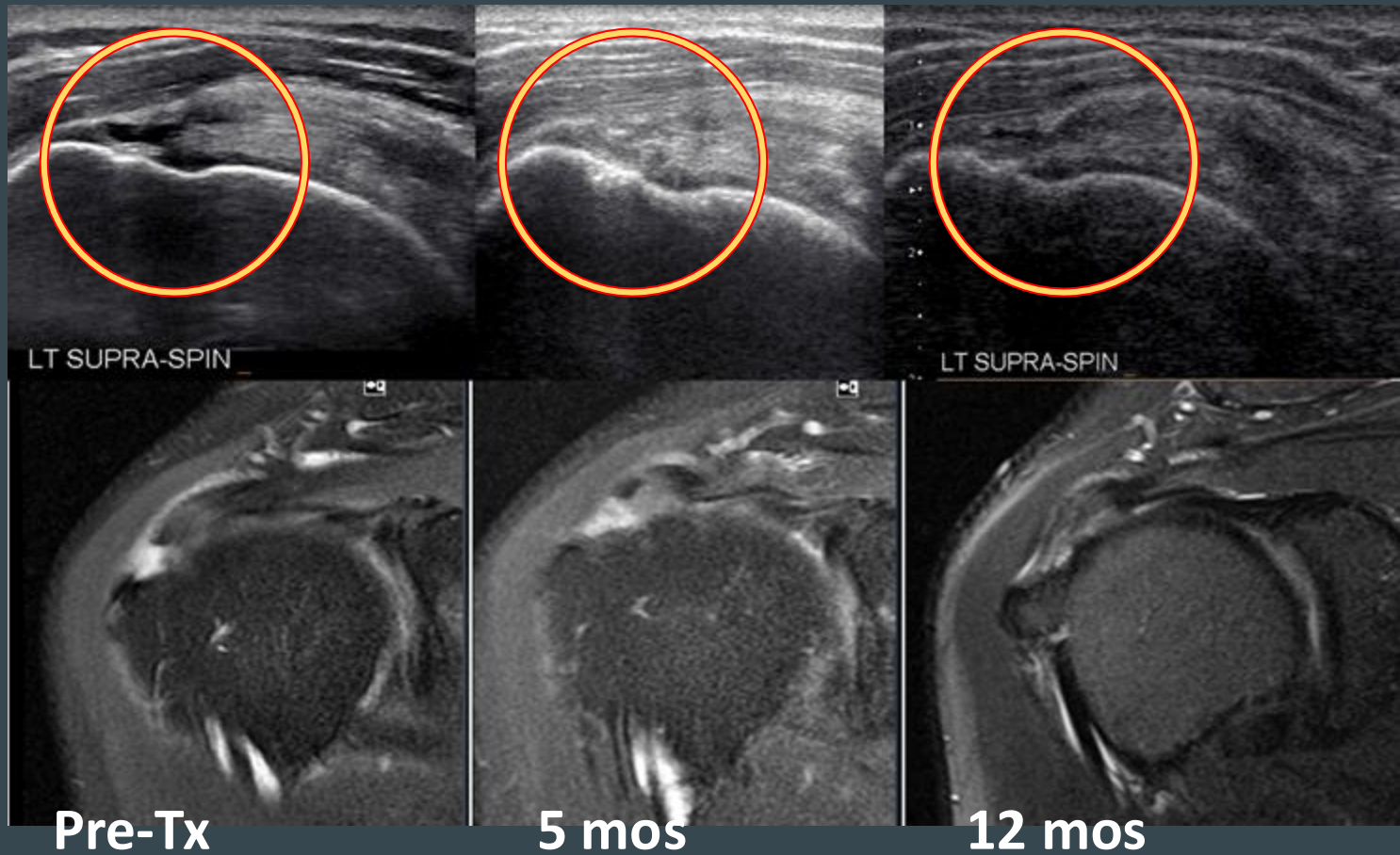
Image guided placement of
needle/therapy into injured
tissues

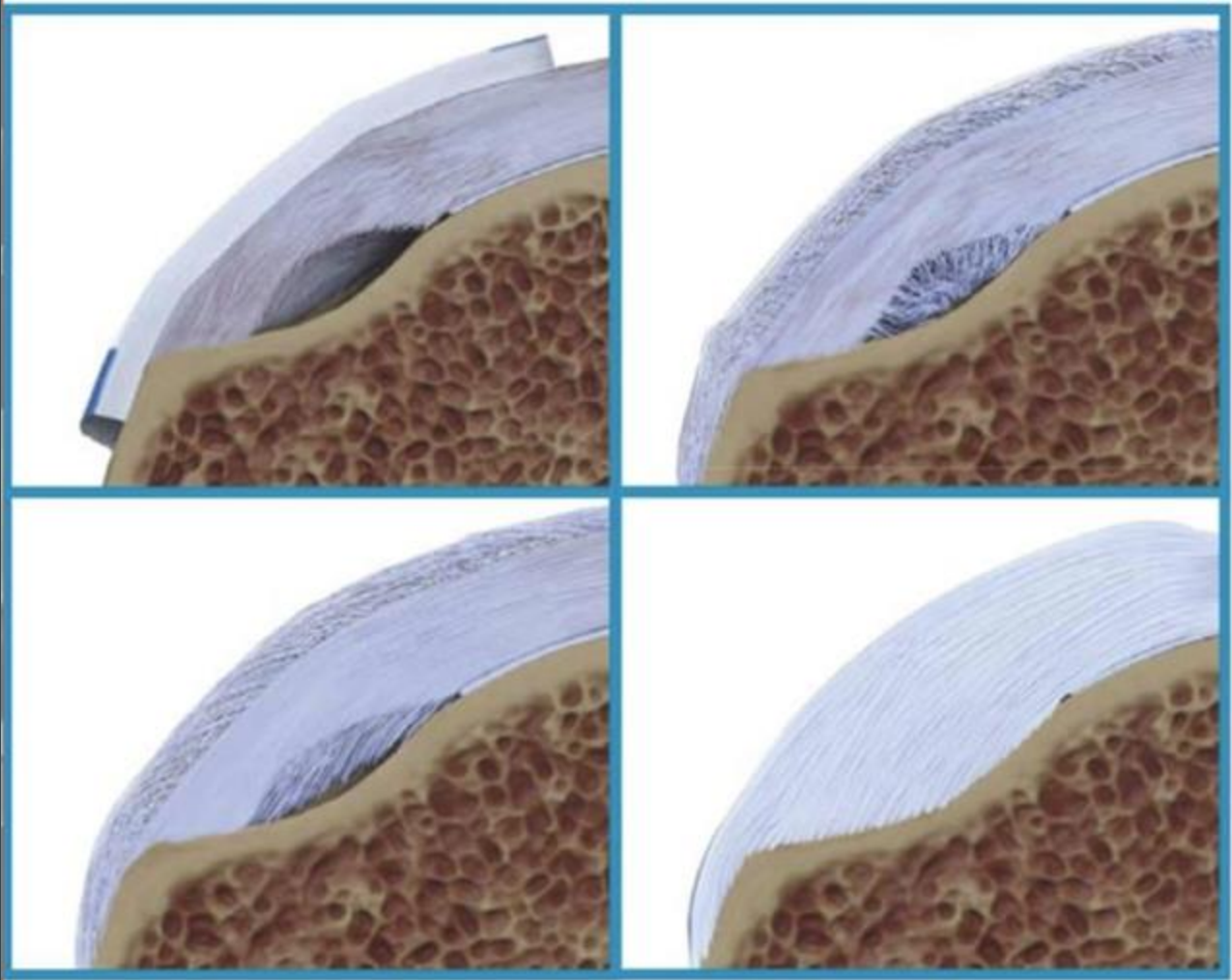
Precision Biologics

The best biologic for the
injury or disease process

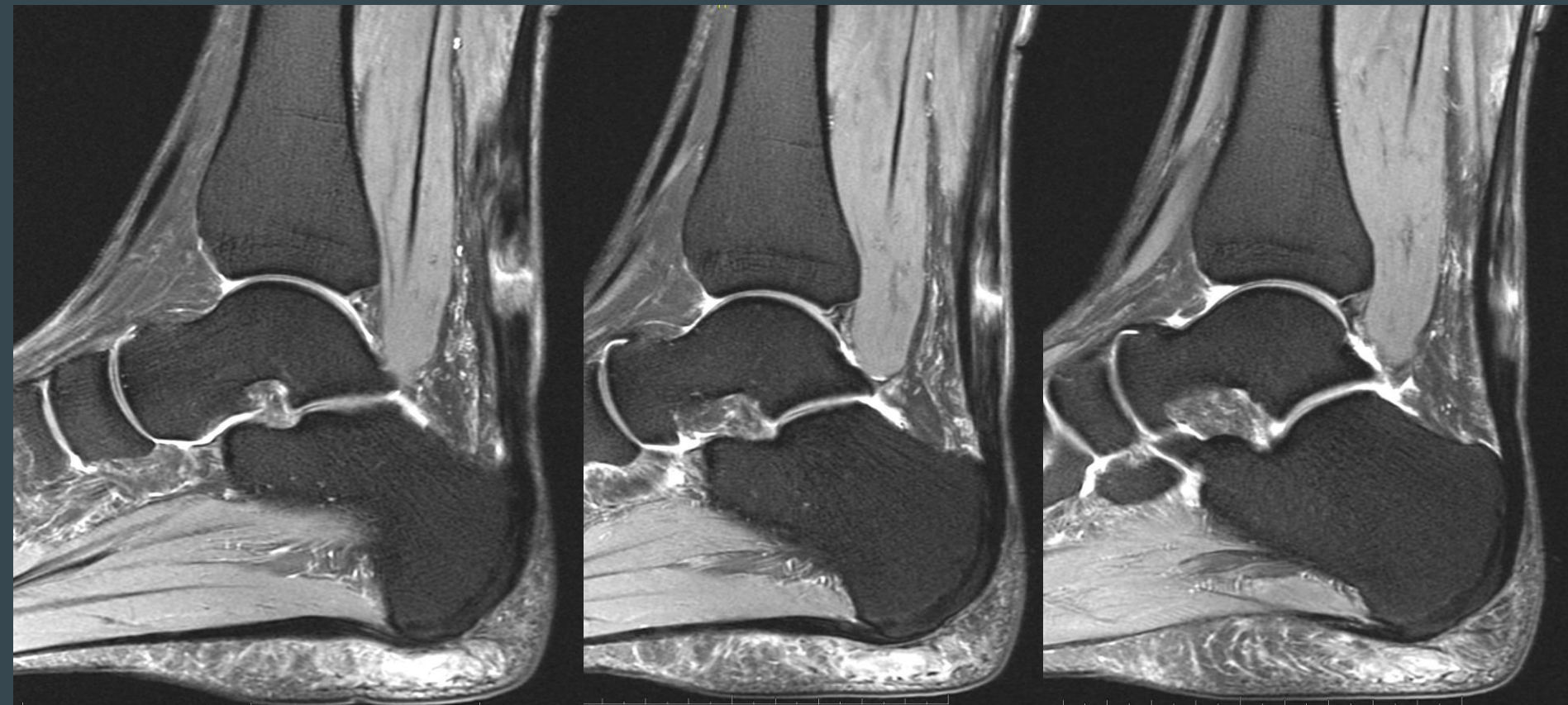

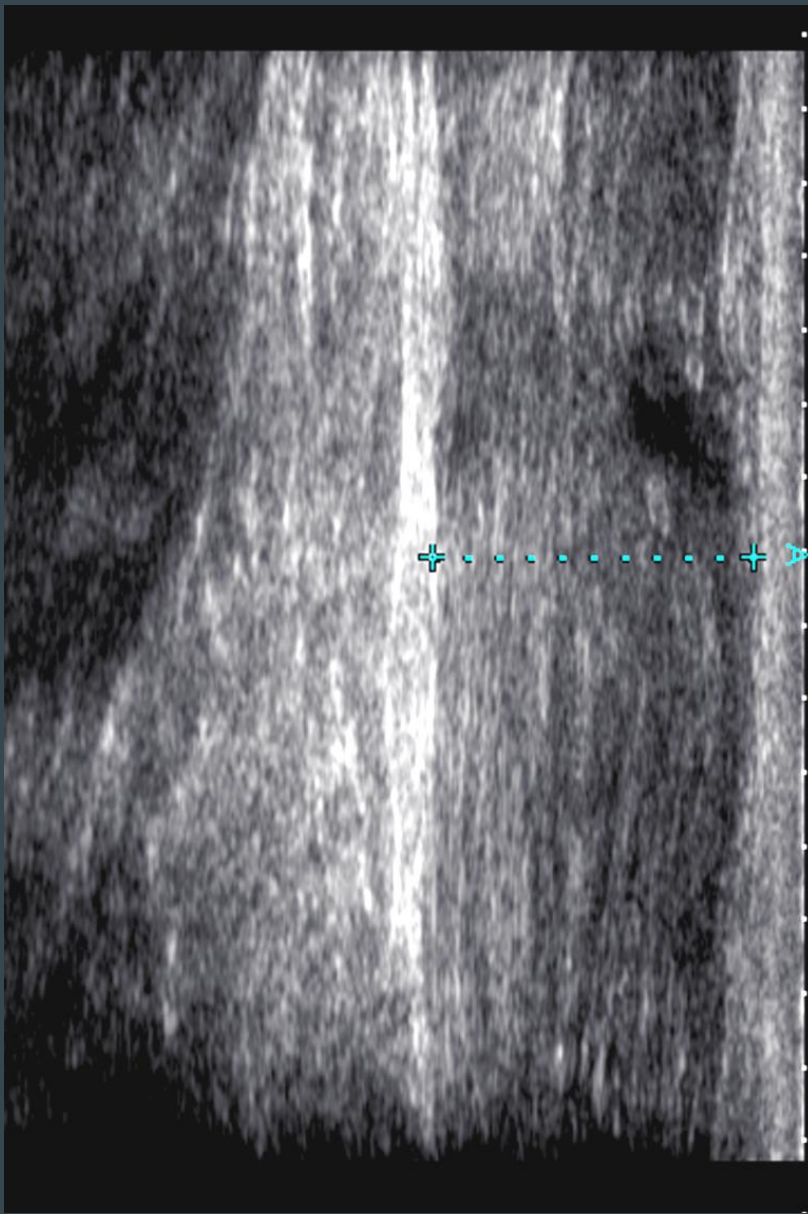
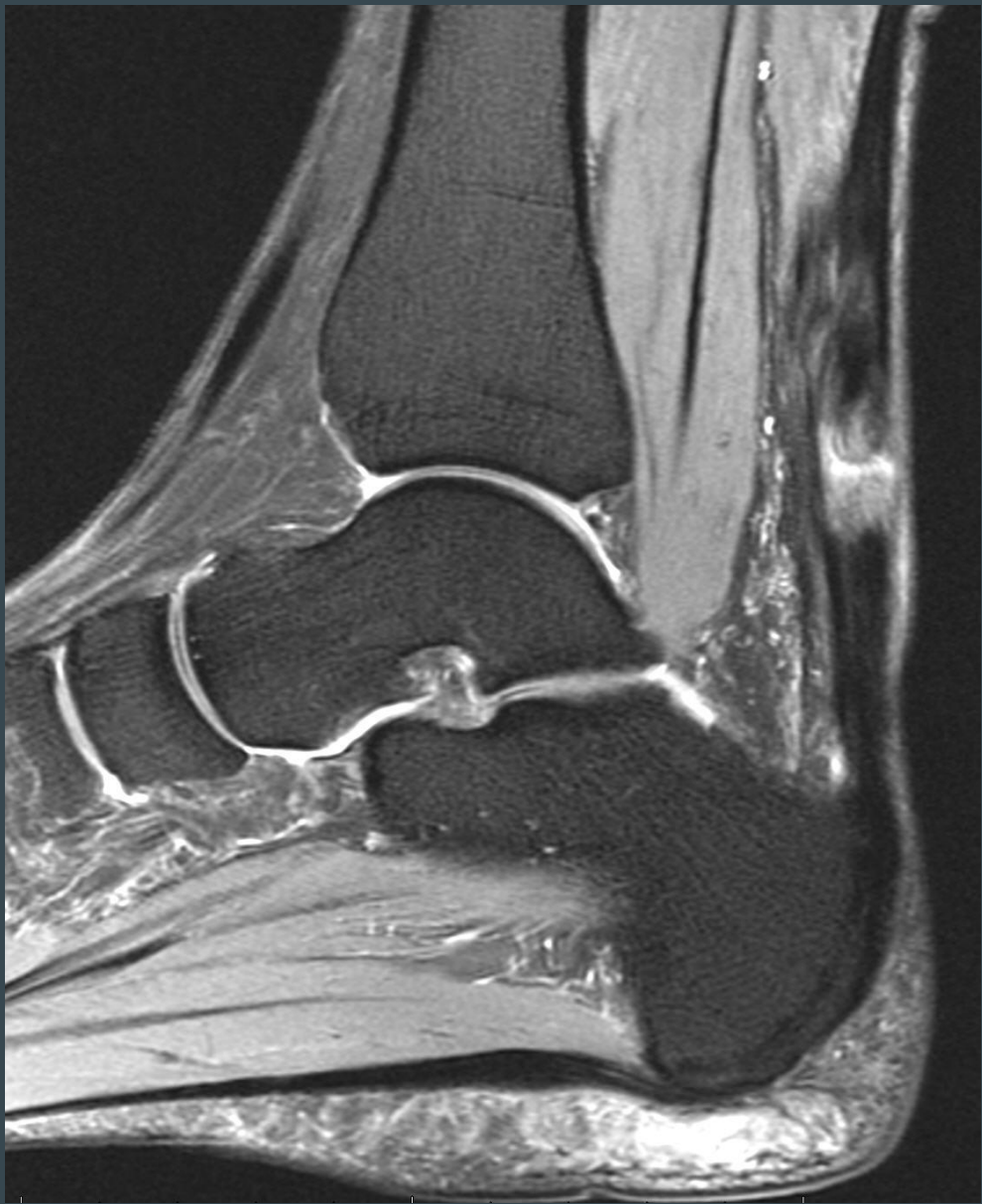Combination therapy PRP + mdHACM





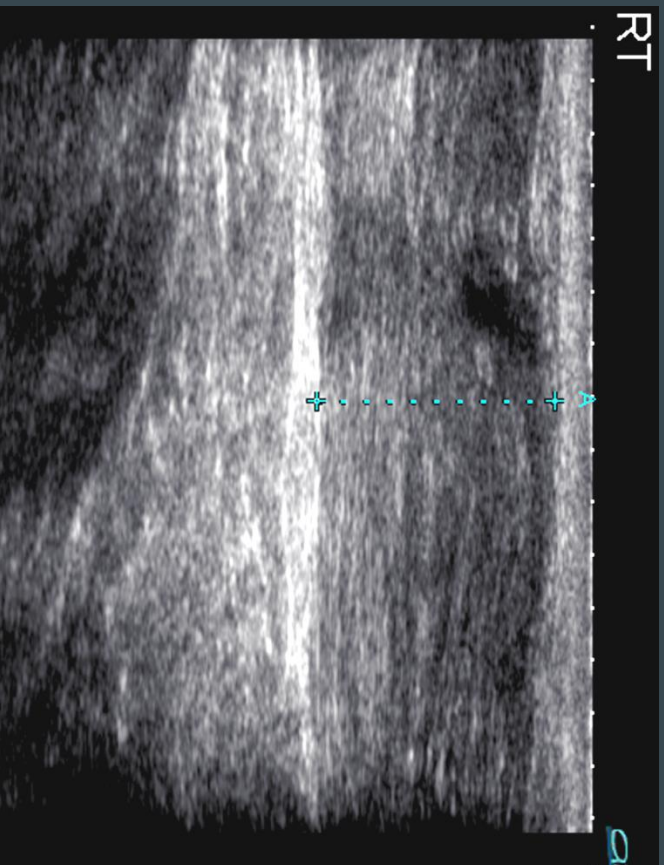
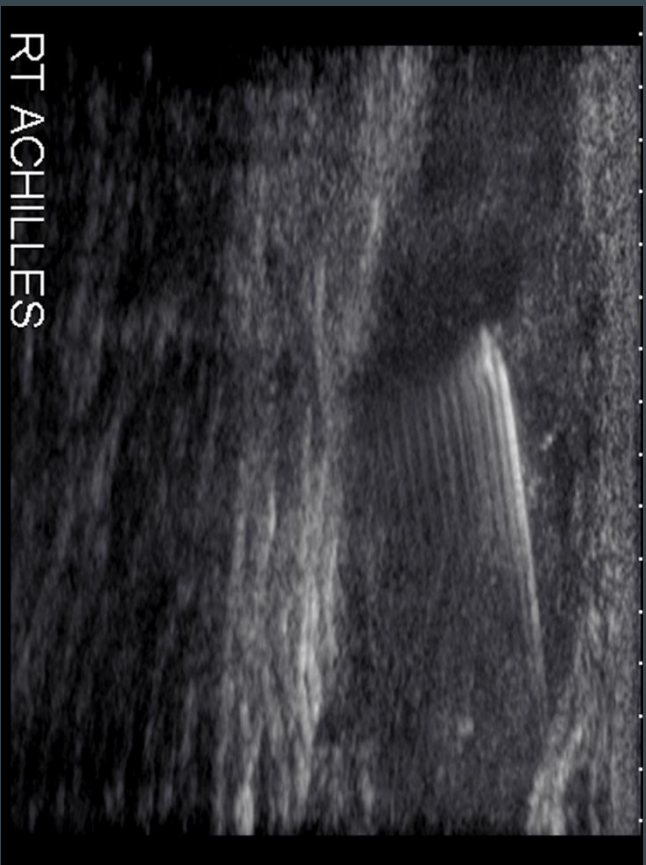43 yo female w/achilles tear



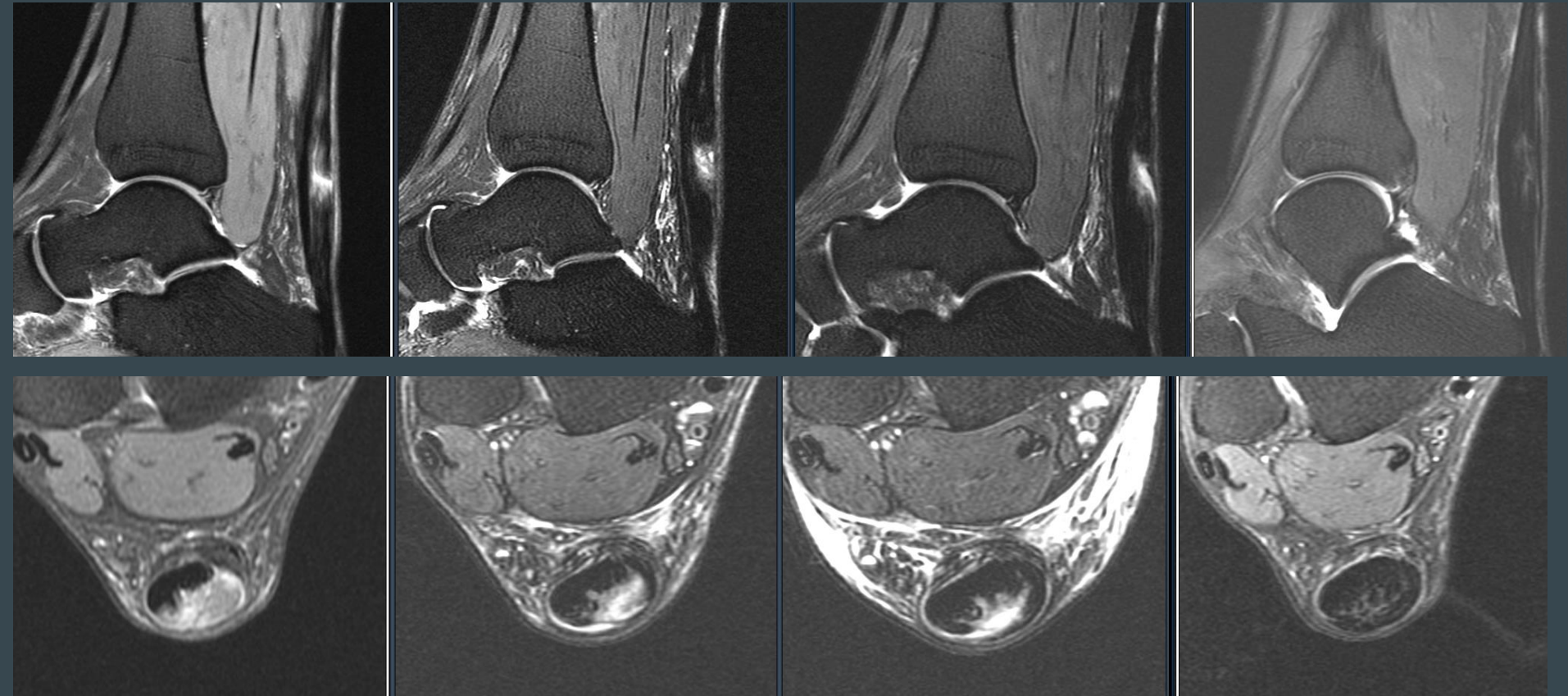


RT

a

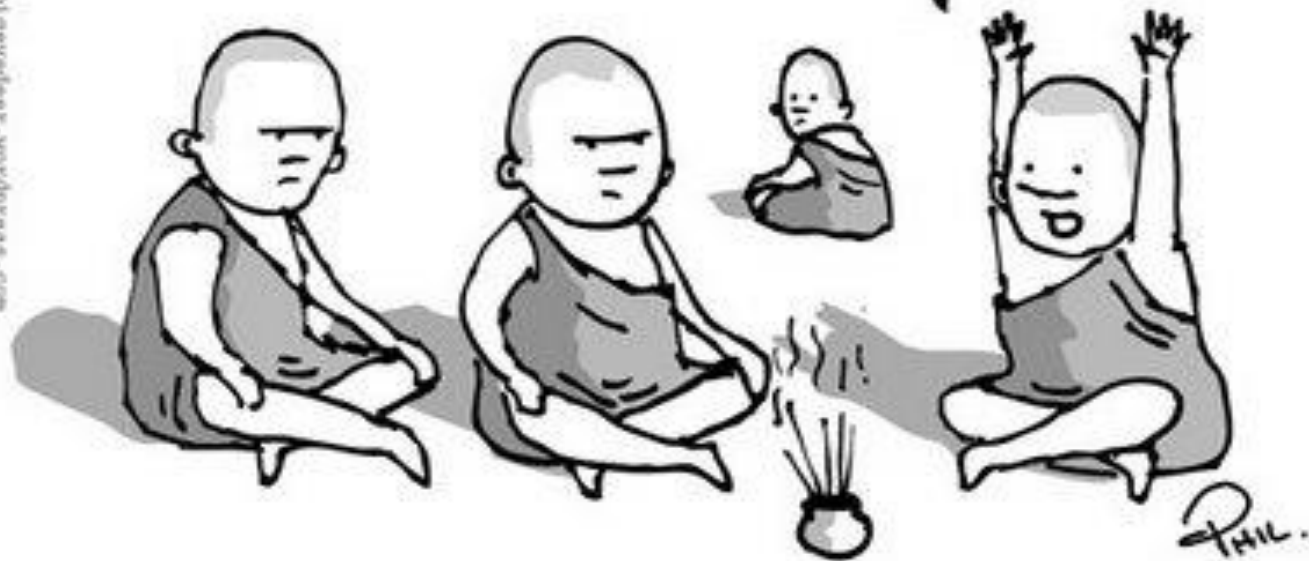

70% Achilles Tear – 4 mos interval



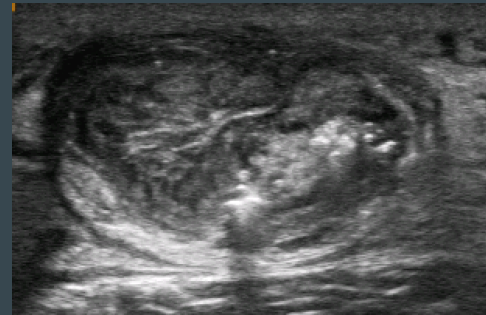
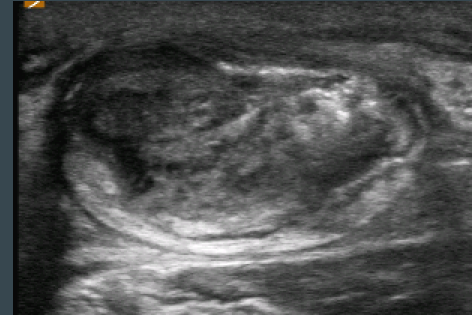
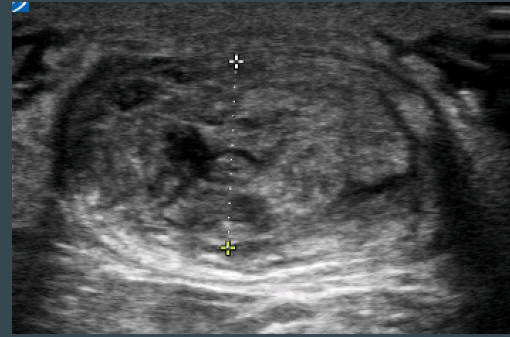
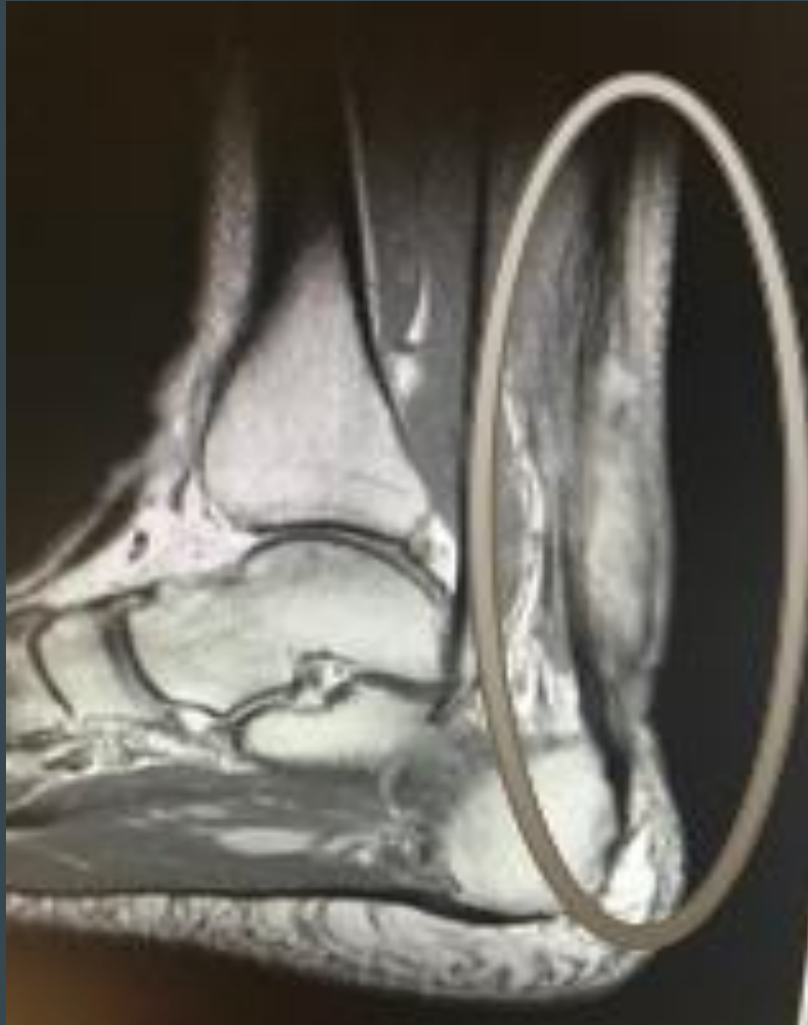Two PRP treatments approximately 2 months apart

OH YEAH! First to reach enlightenment... Right here, people! WOOOO BABY! Eat my dust, ladies!

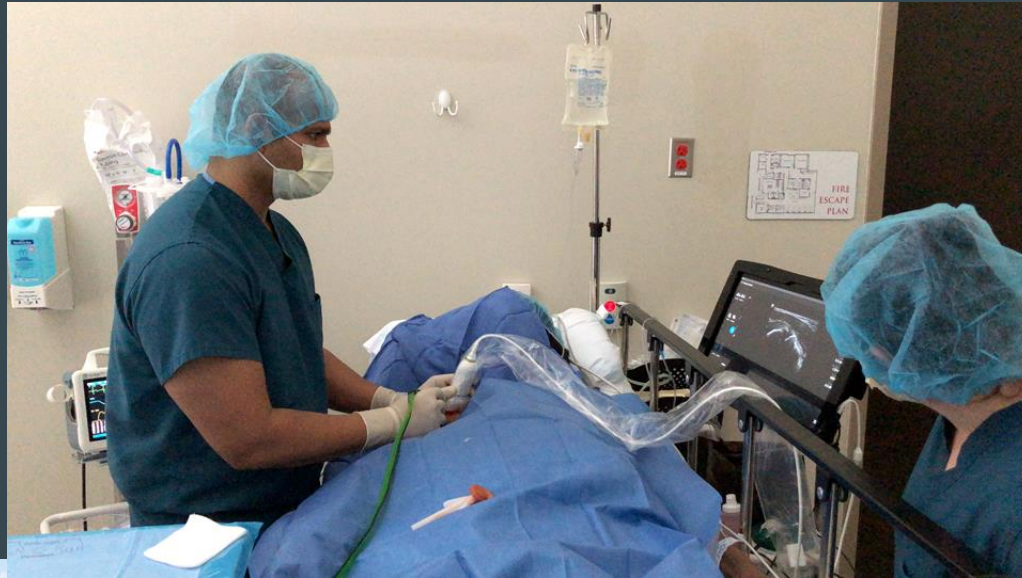

PRP/Platelet Rich Plasma

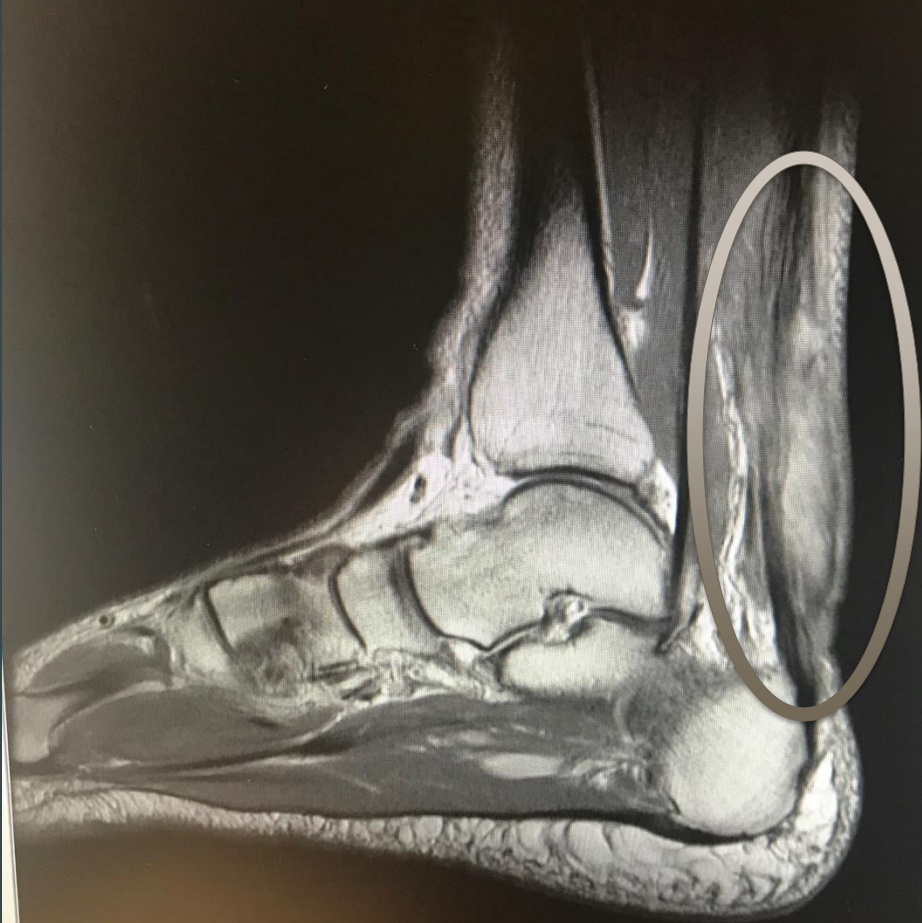



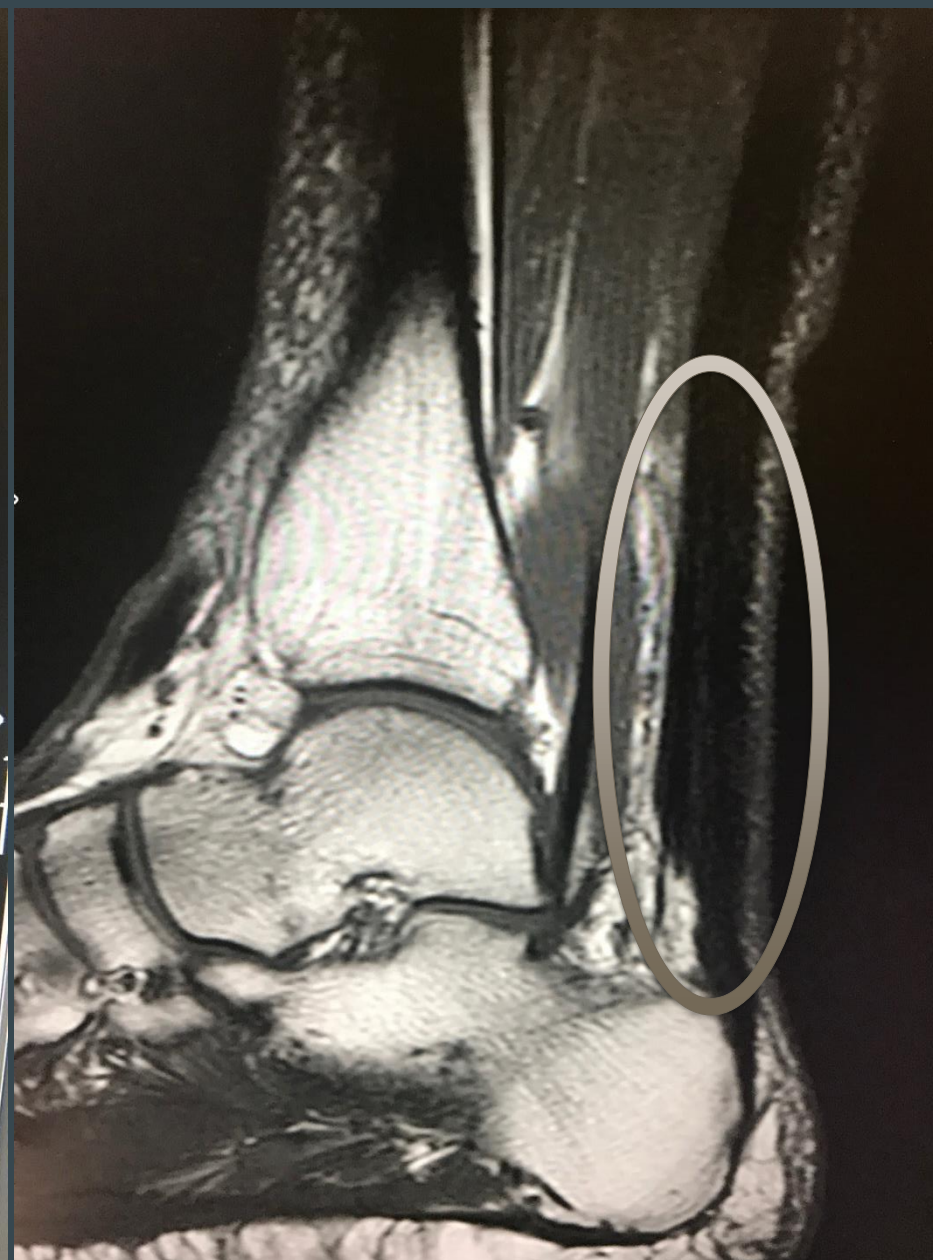Tenex Debridement Demolition and remodeling



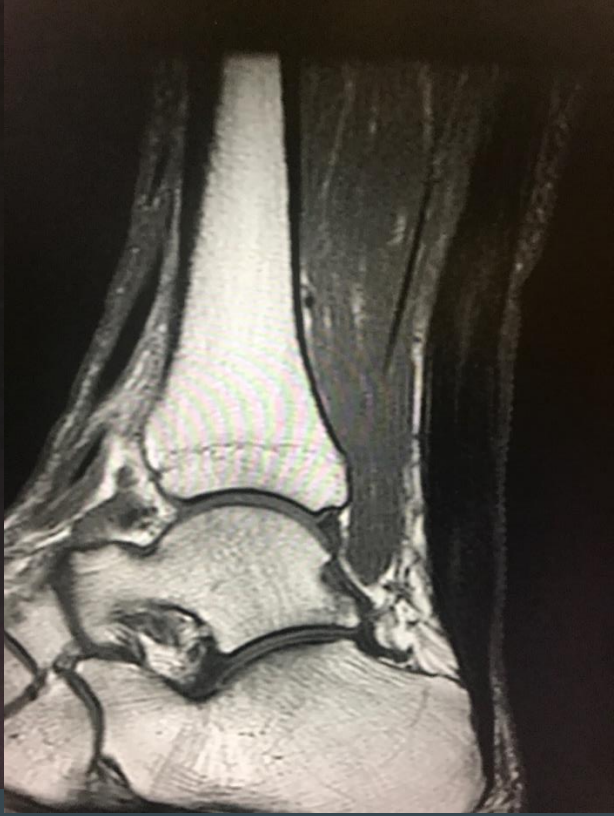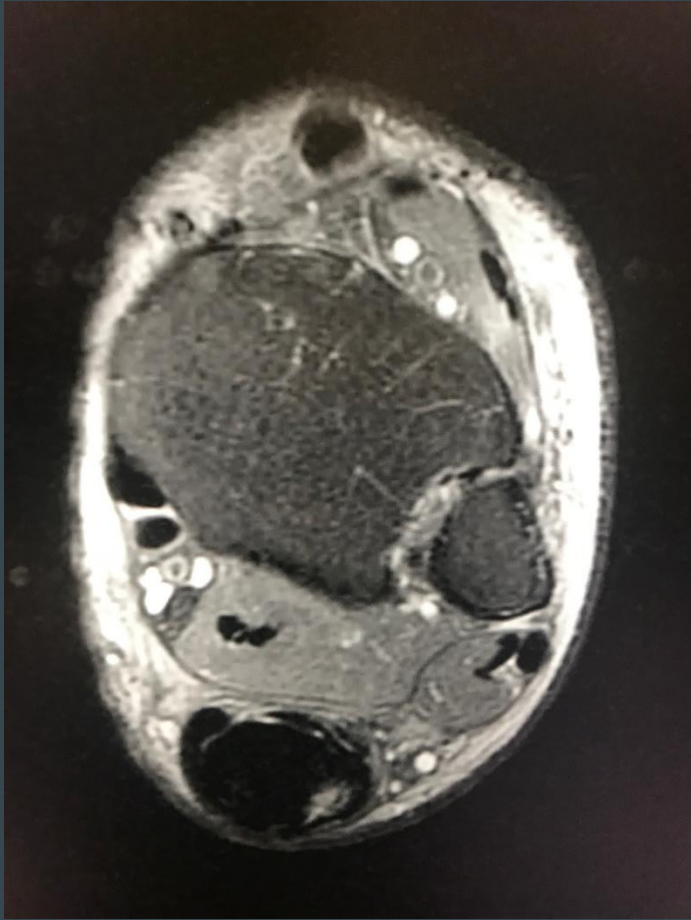
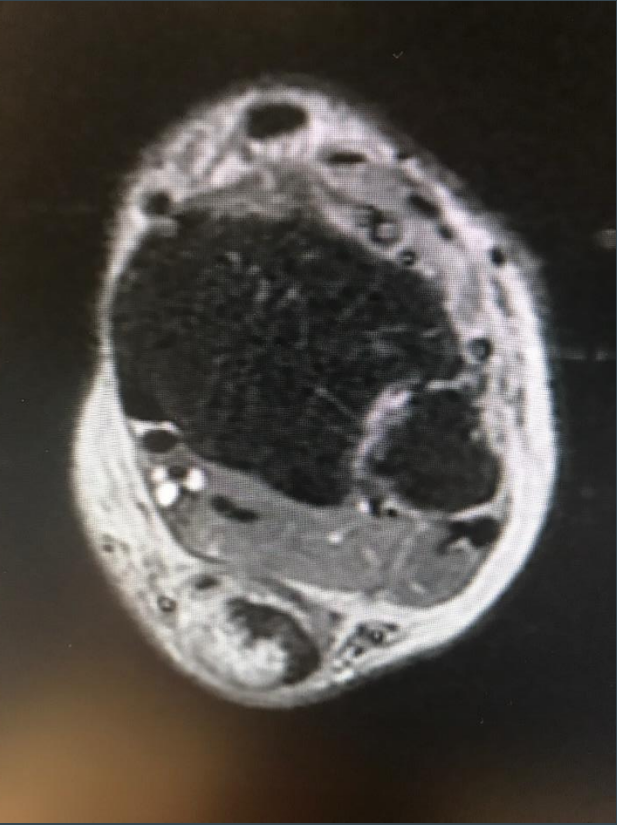
1633.34
24.08
1



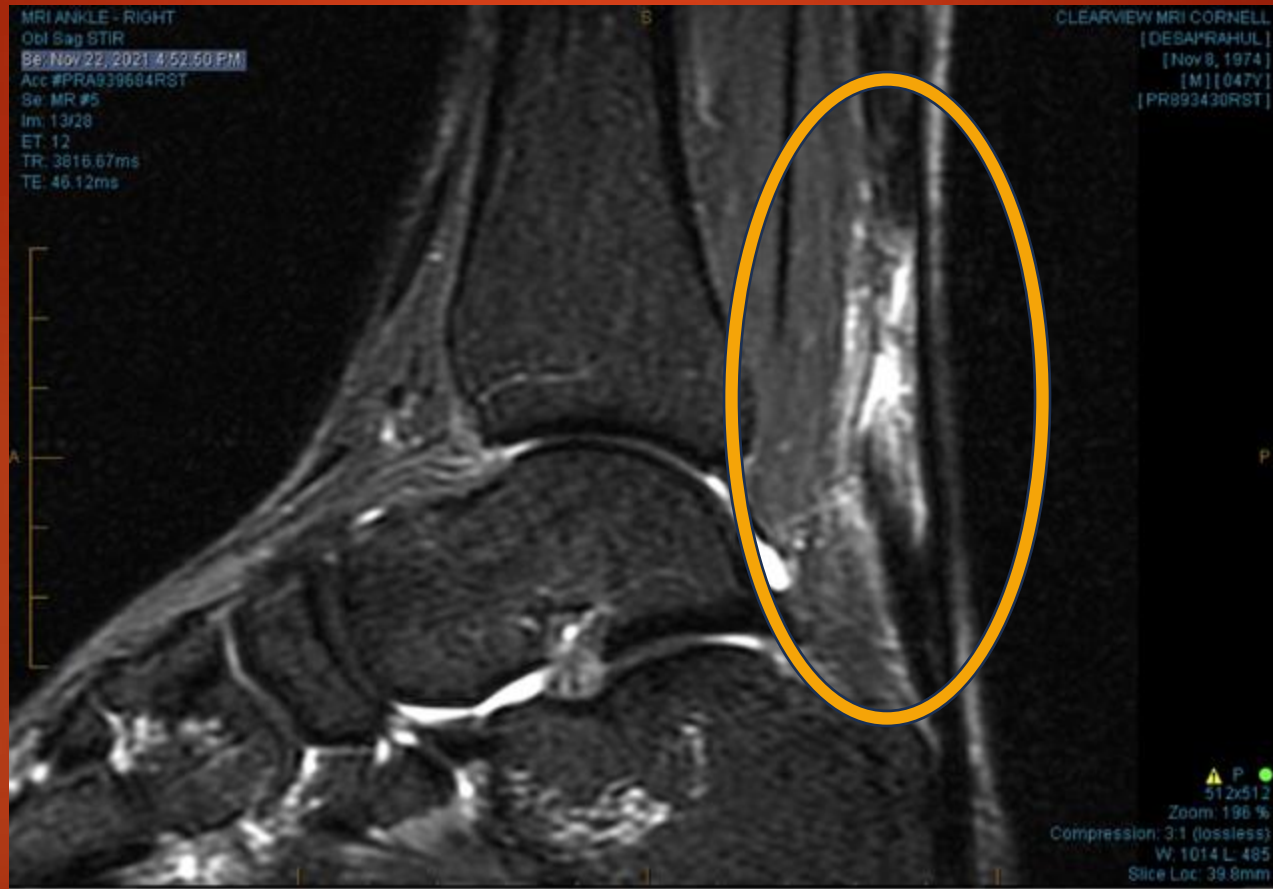
P



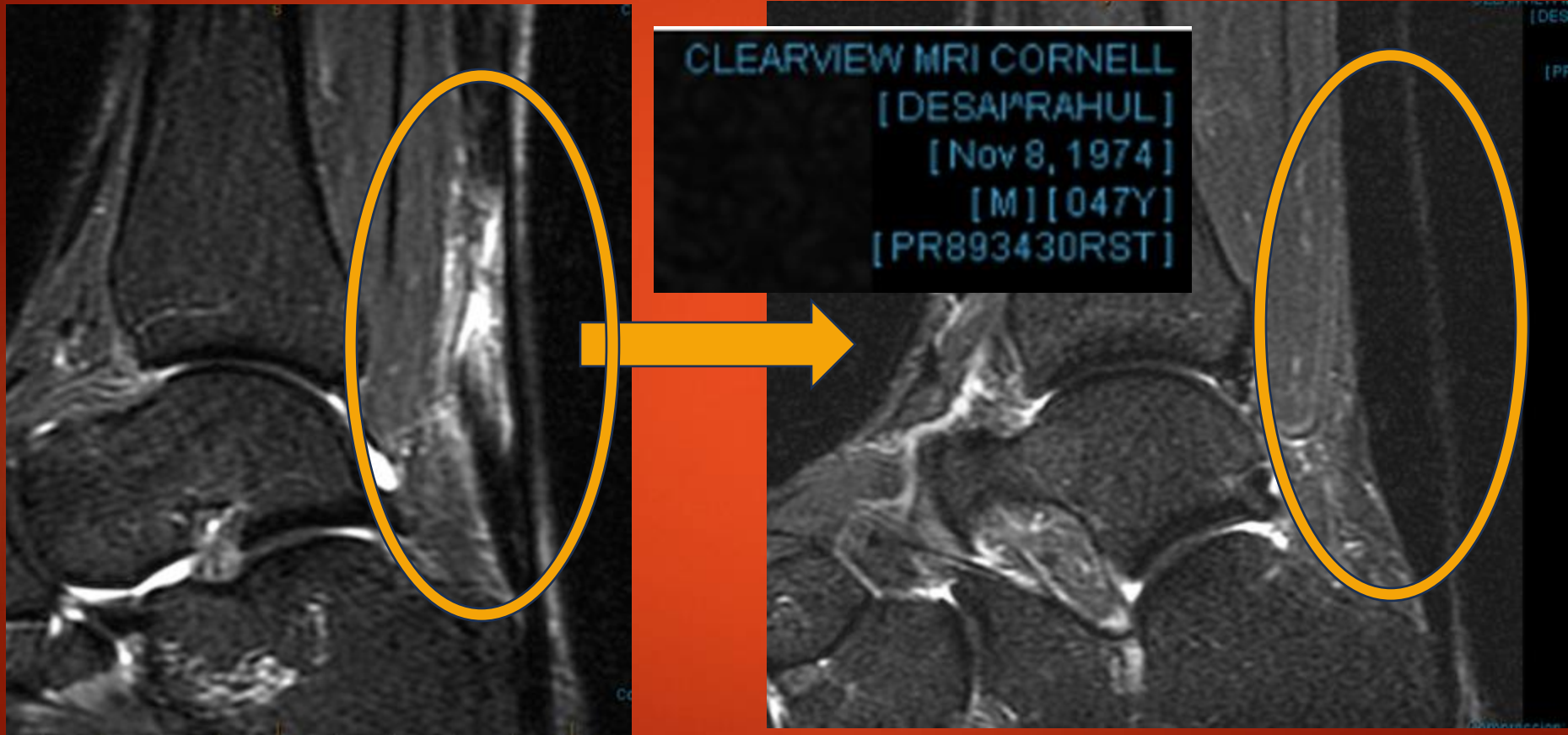
FFS
Series no: 3
FOV: 200



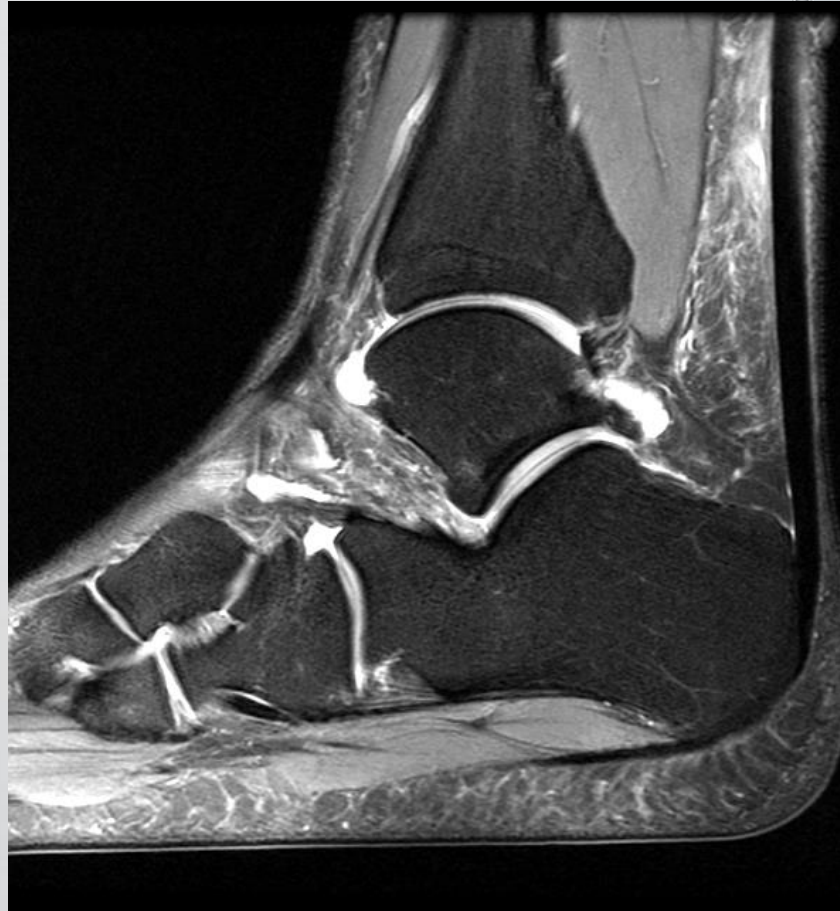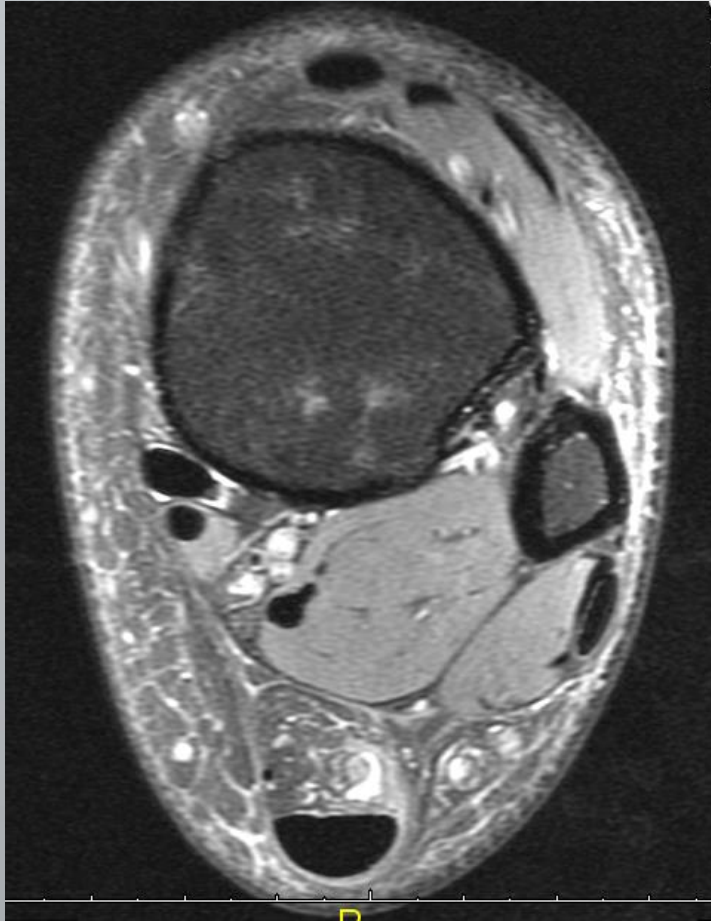
47 yo m achilles tendinopathy & tear

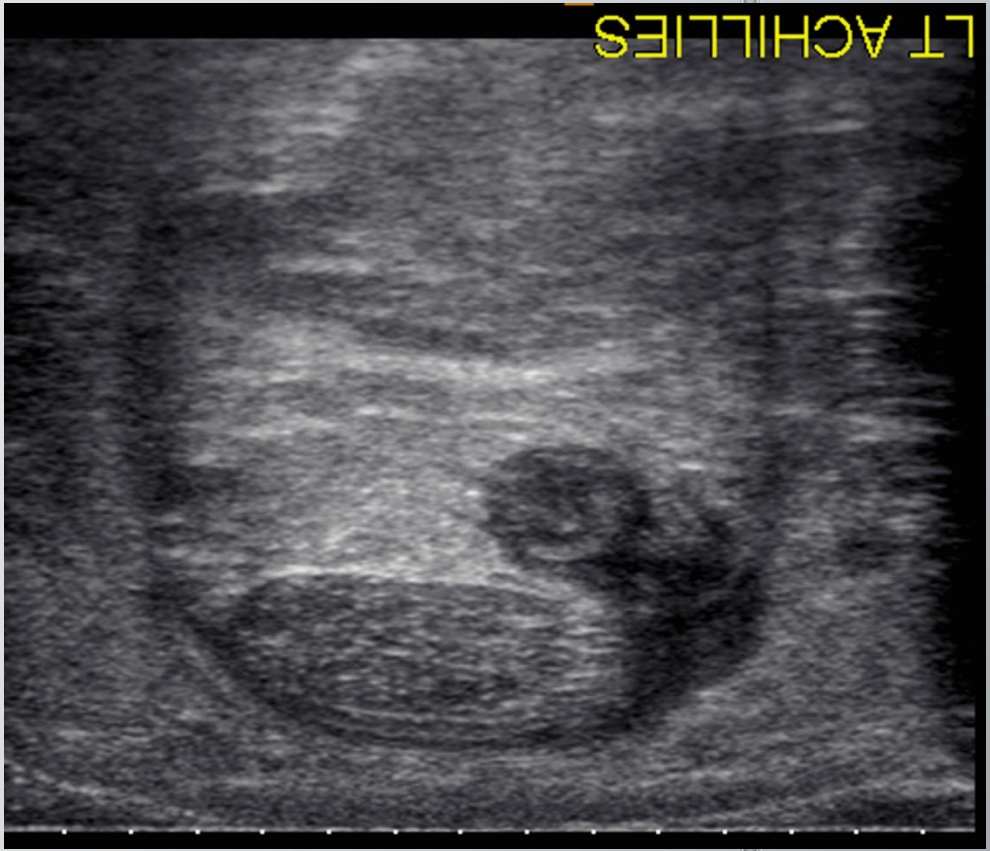
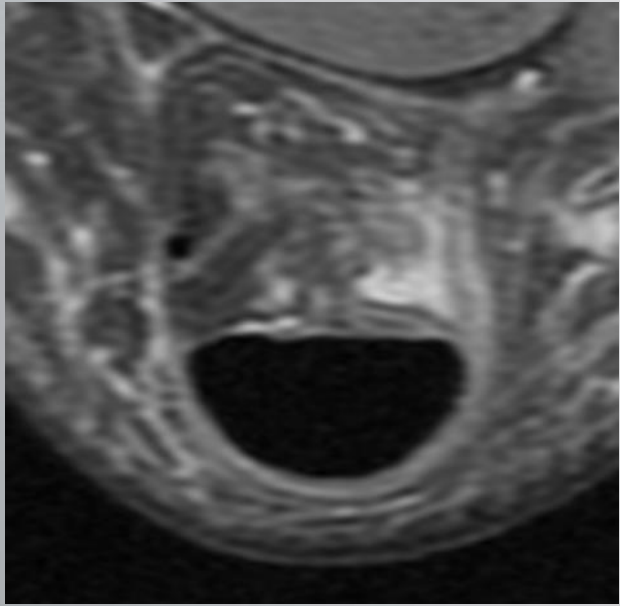
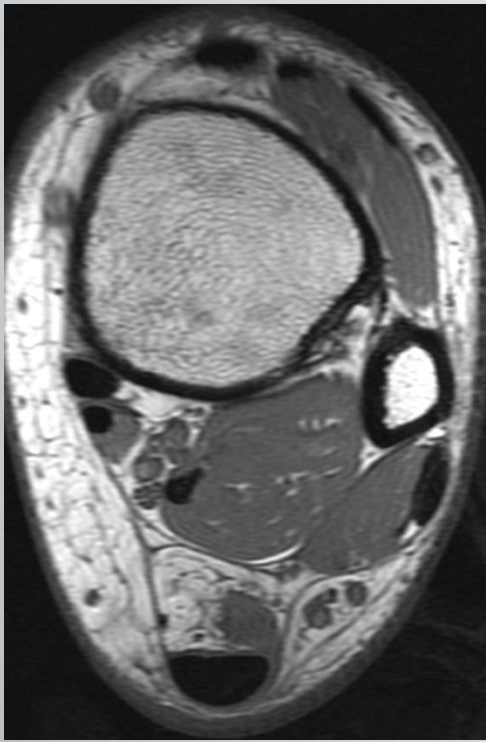


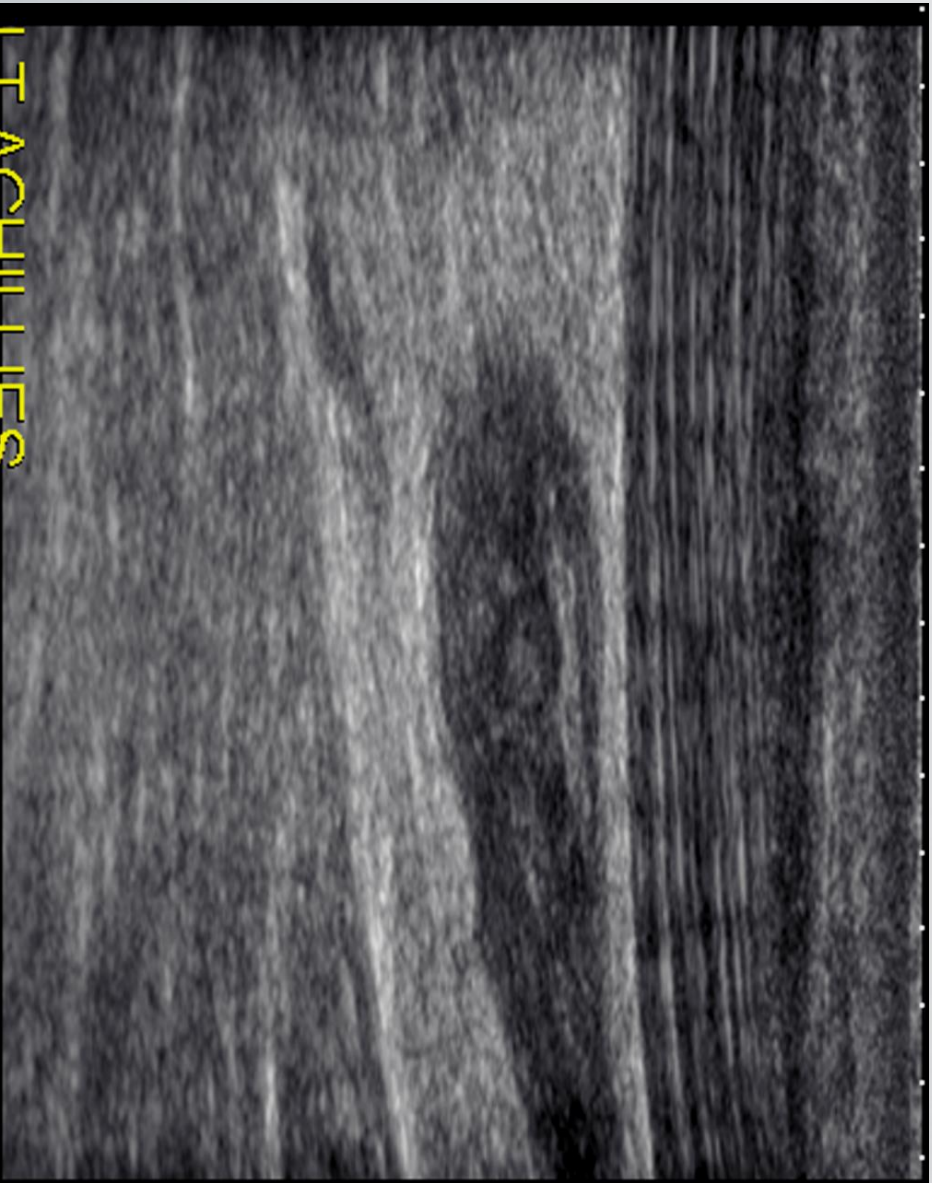
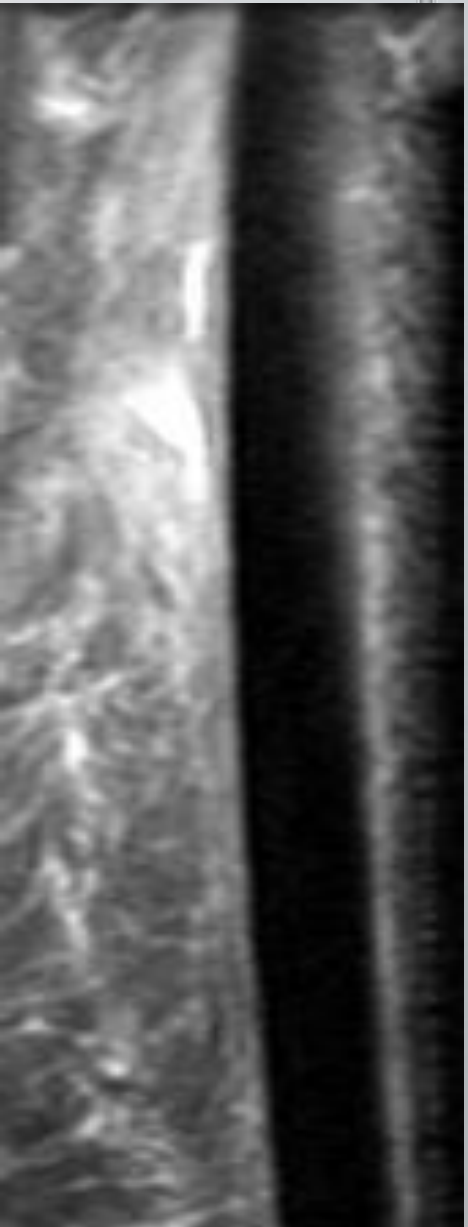
Autologous Intra-lesional BLP



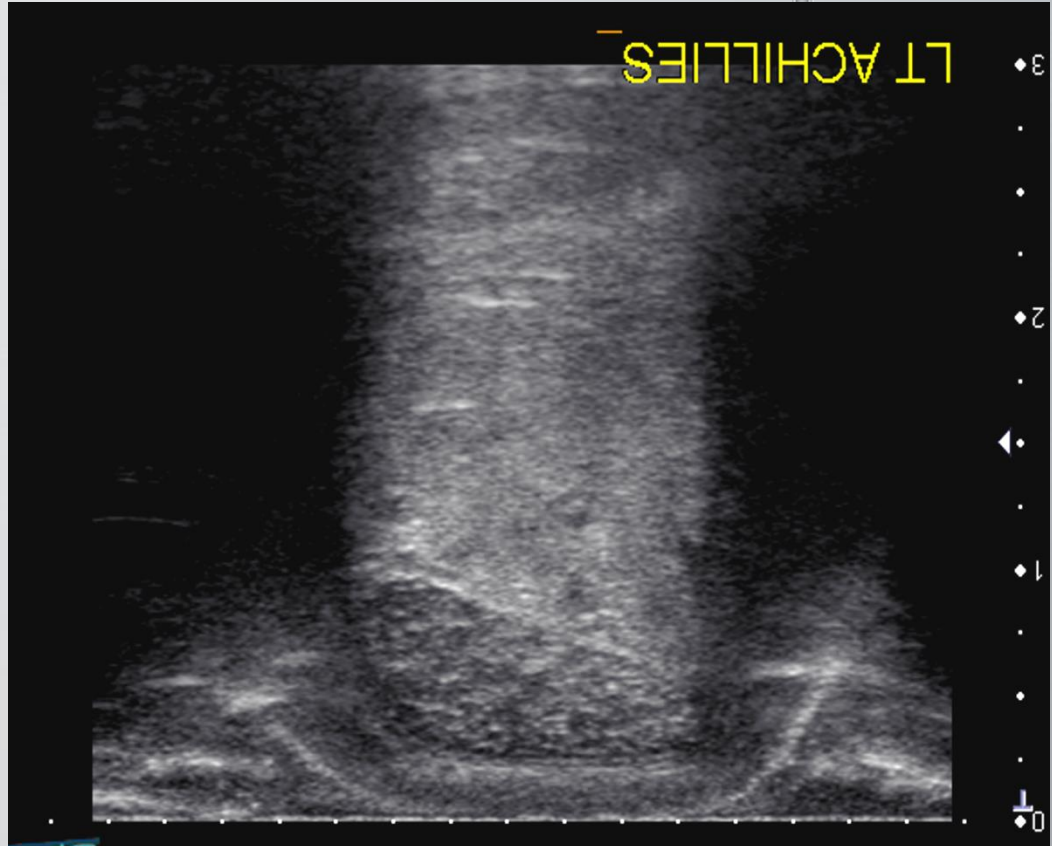
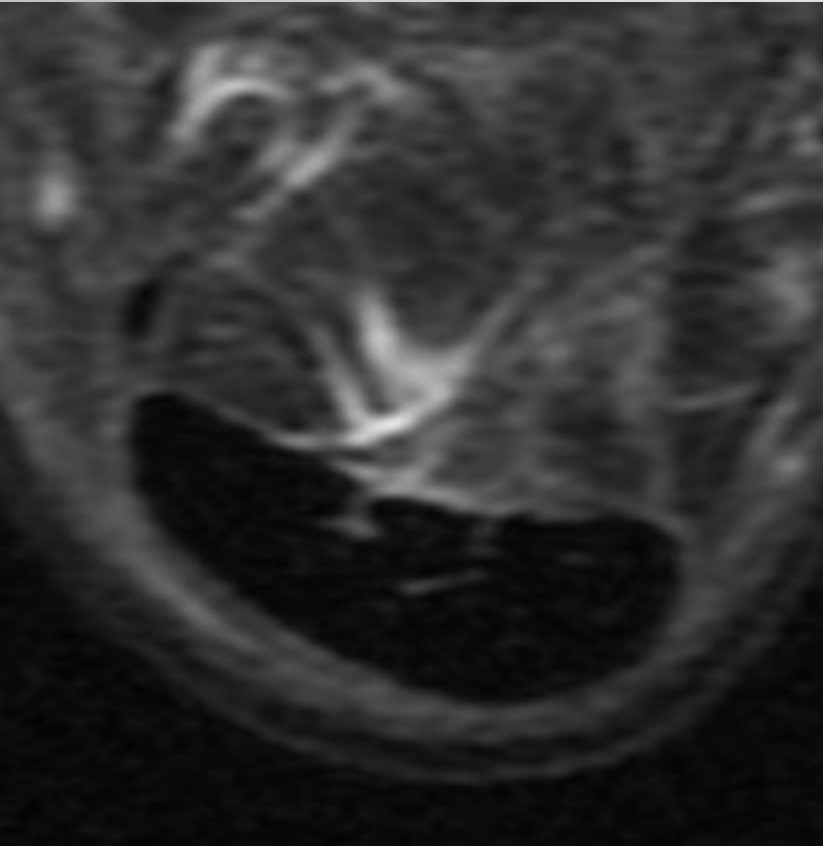
35 yo runner

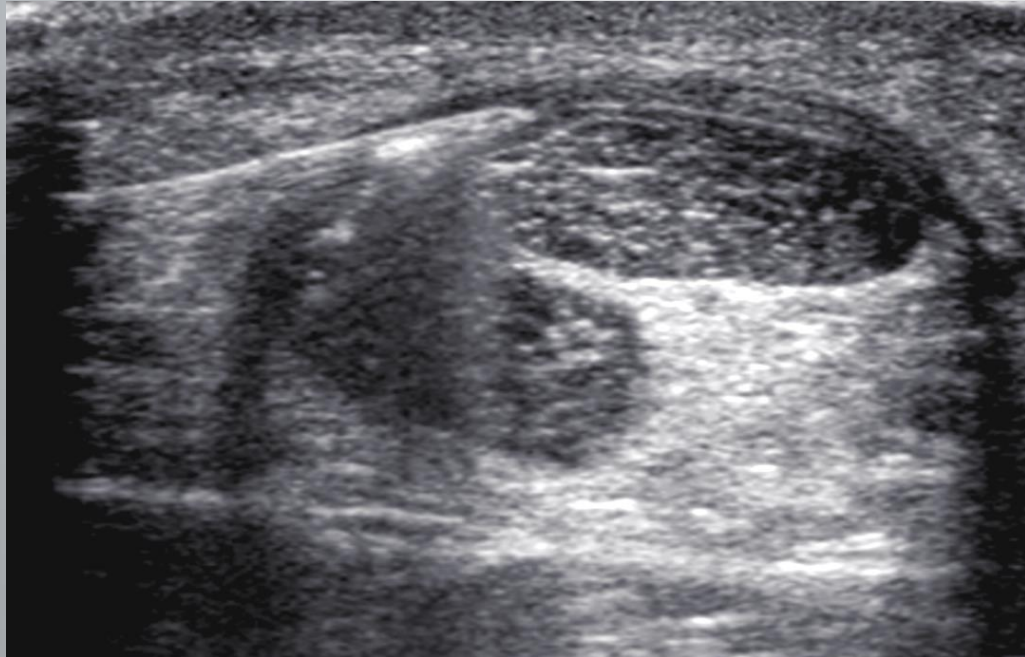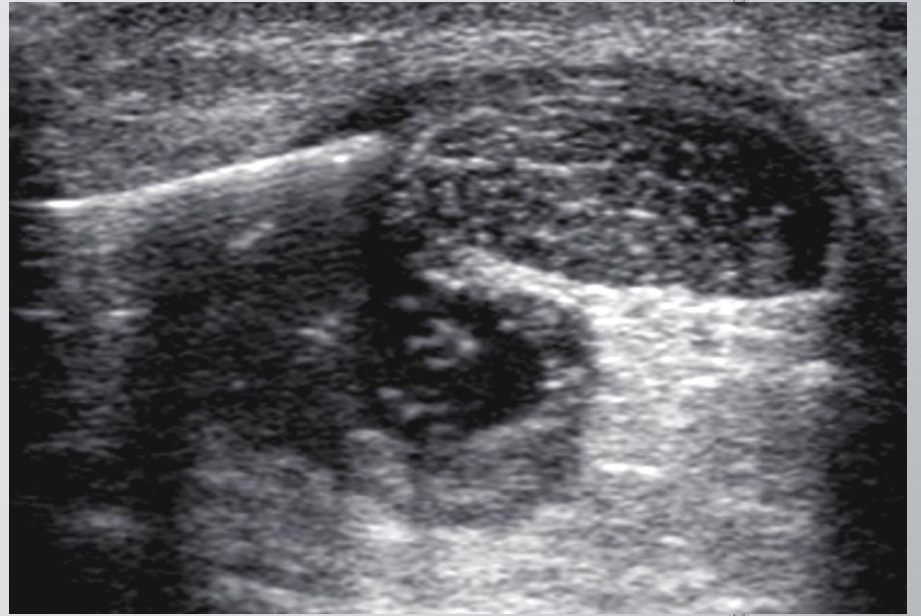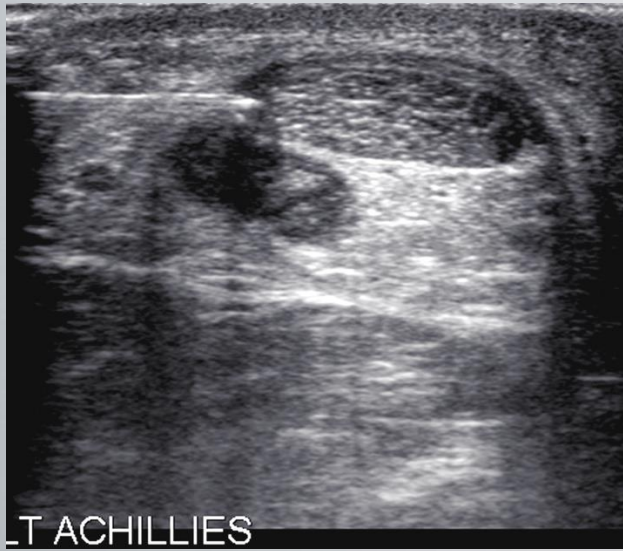




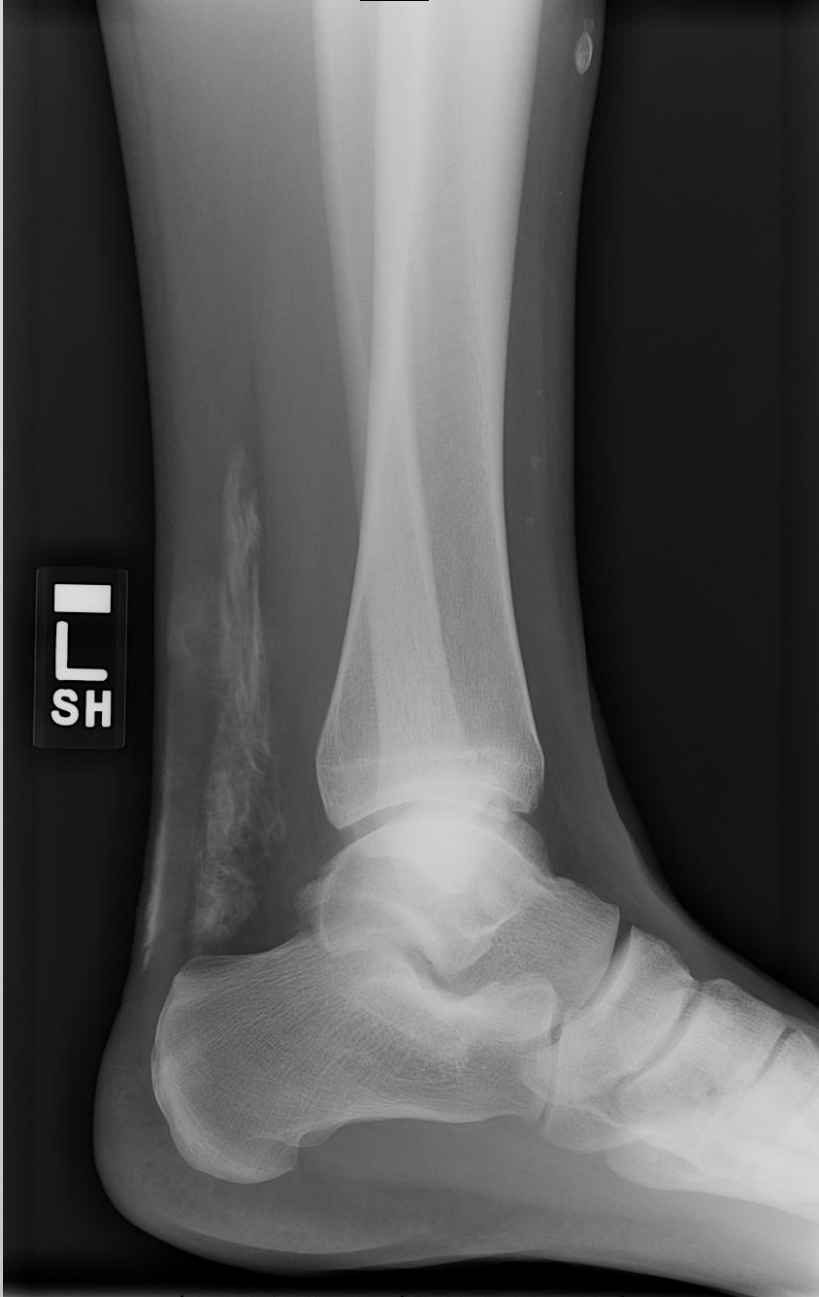

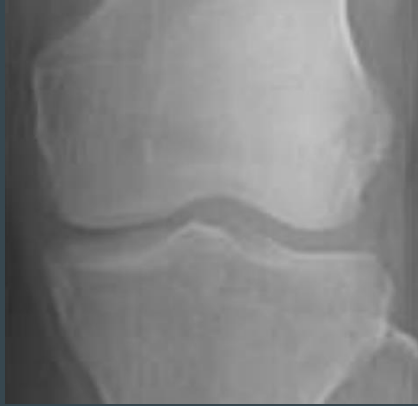LT ACHILLIES

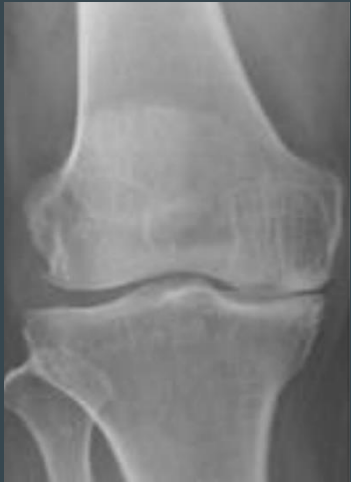







Growth Factors

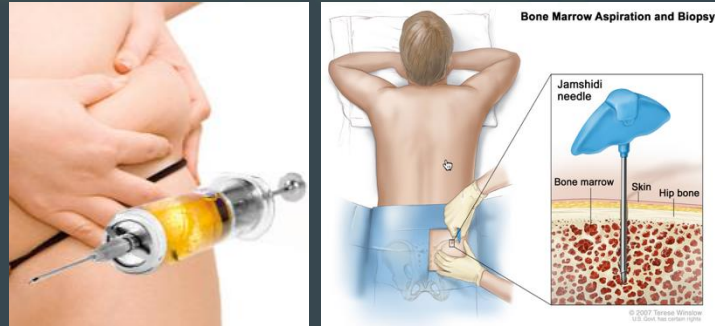


Cell Therapy

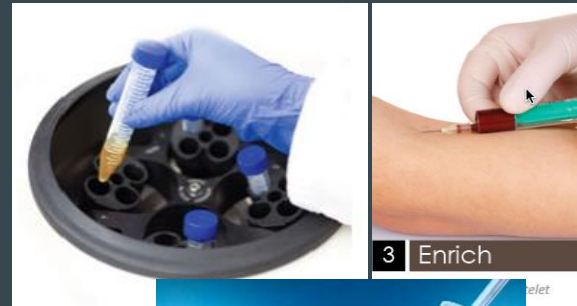

CELLULAR THERAPY

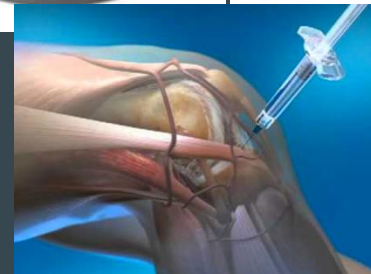1



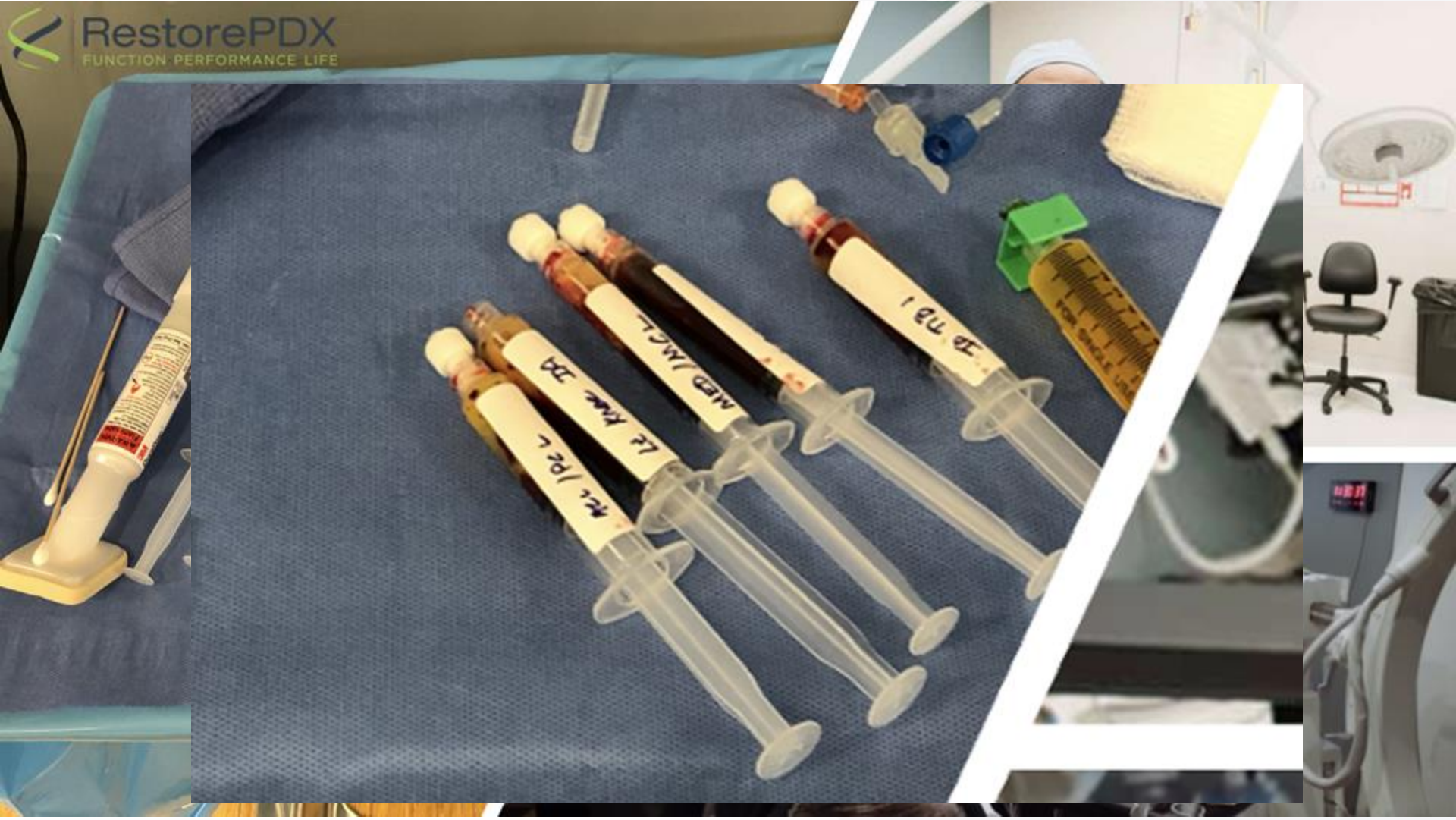2



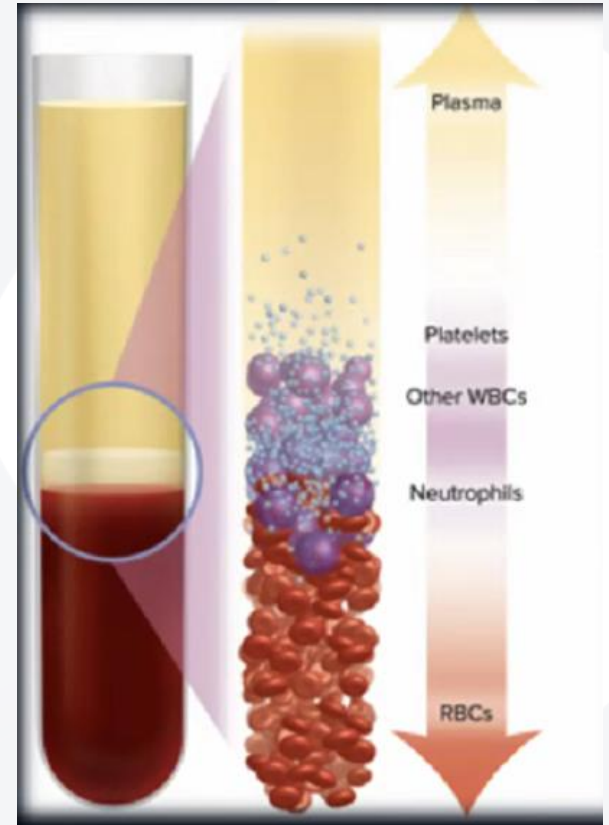
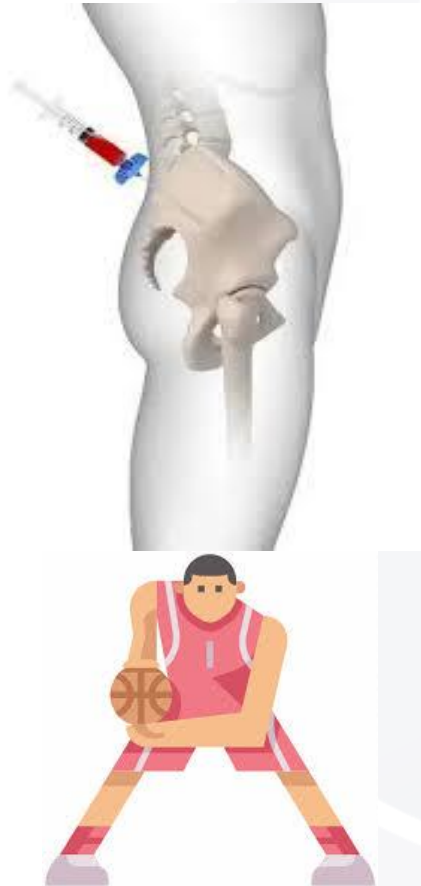
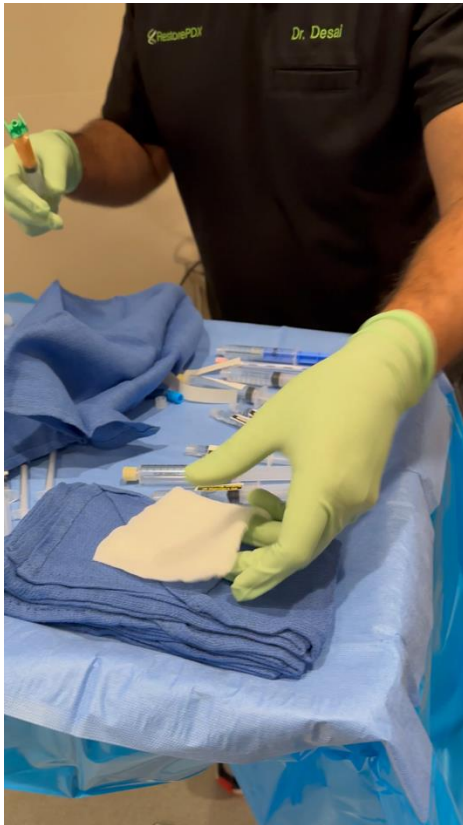3

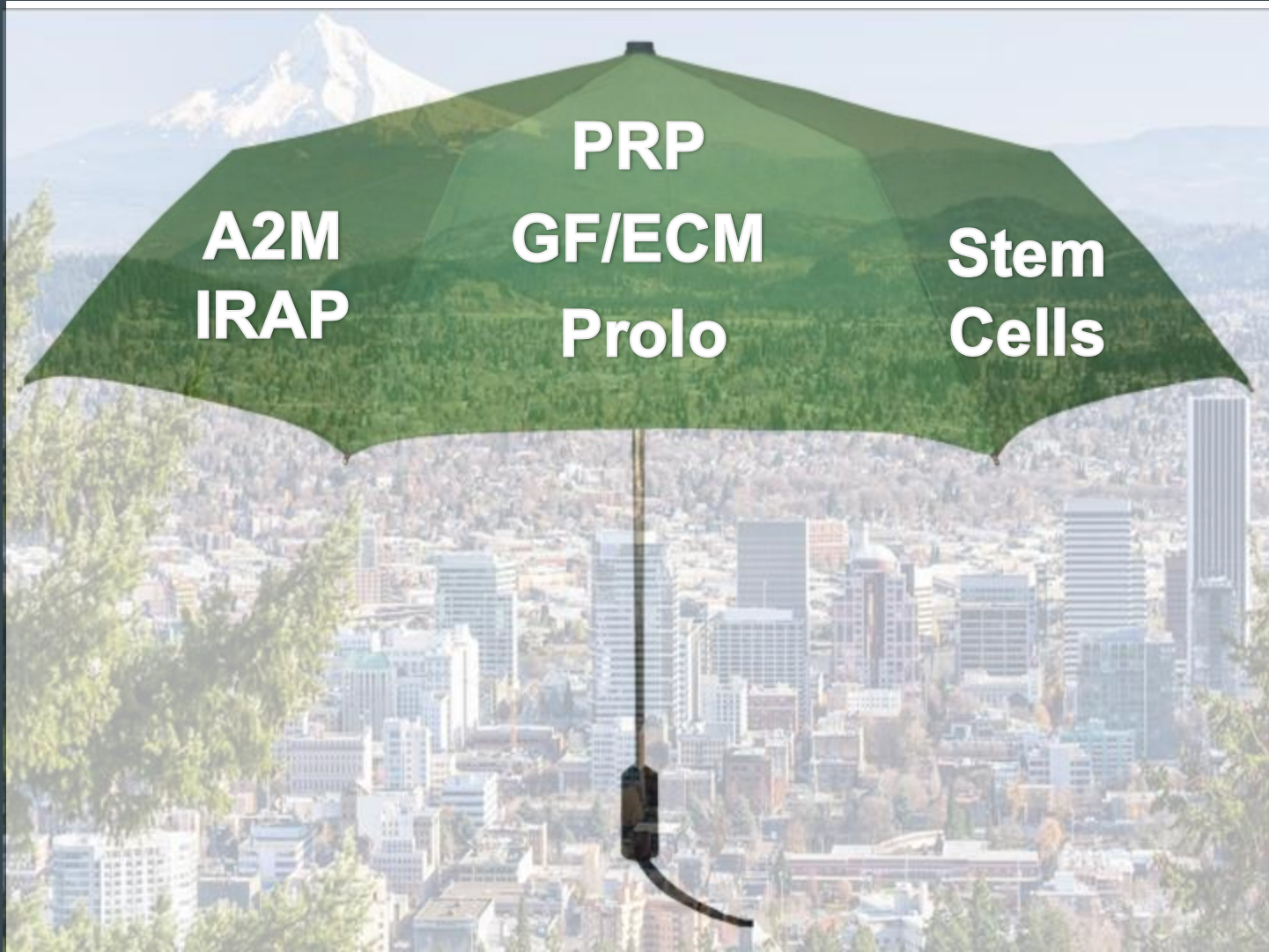






Triple Threat





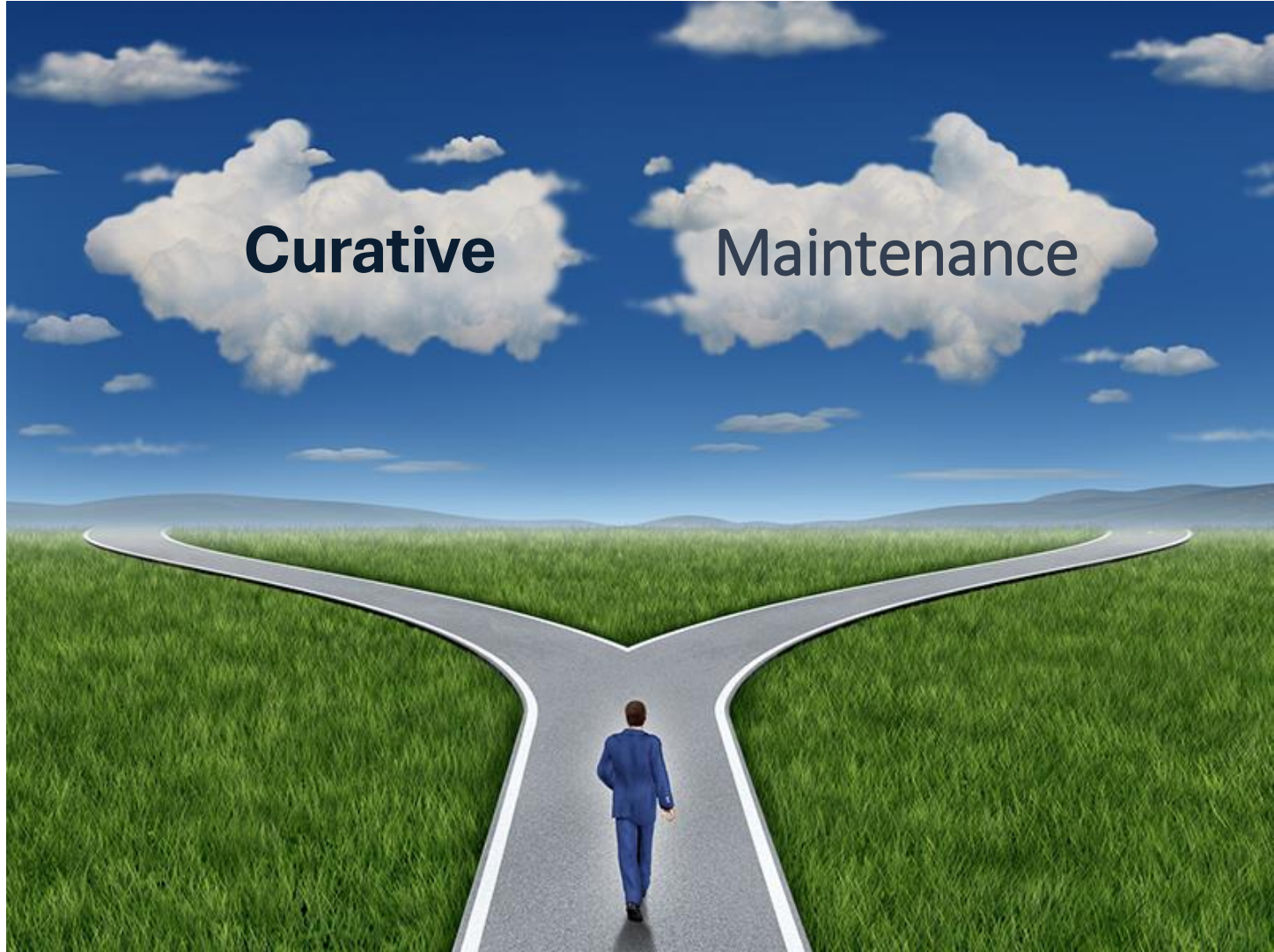A2M
IRAP

PRP
GF/ECM
Prolo

Stem
Cells

Curative

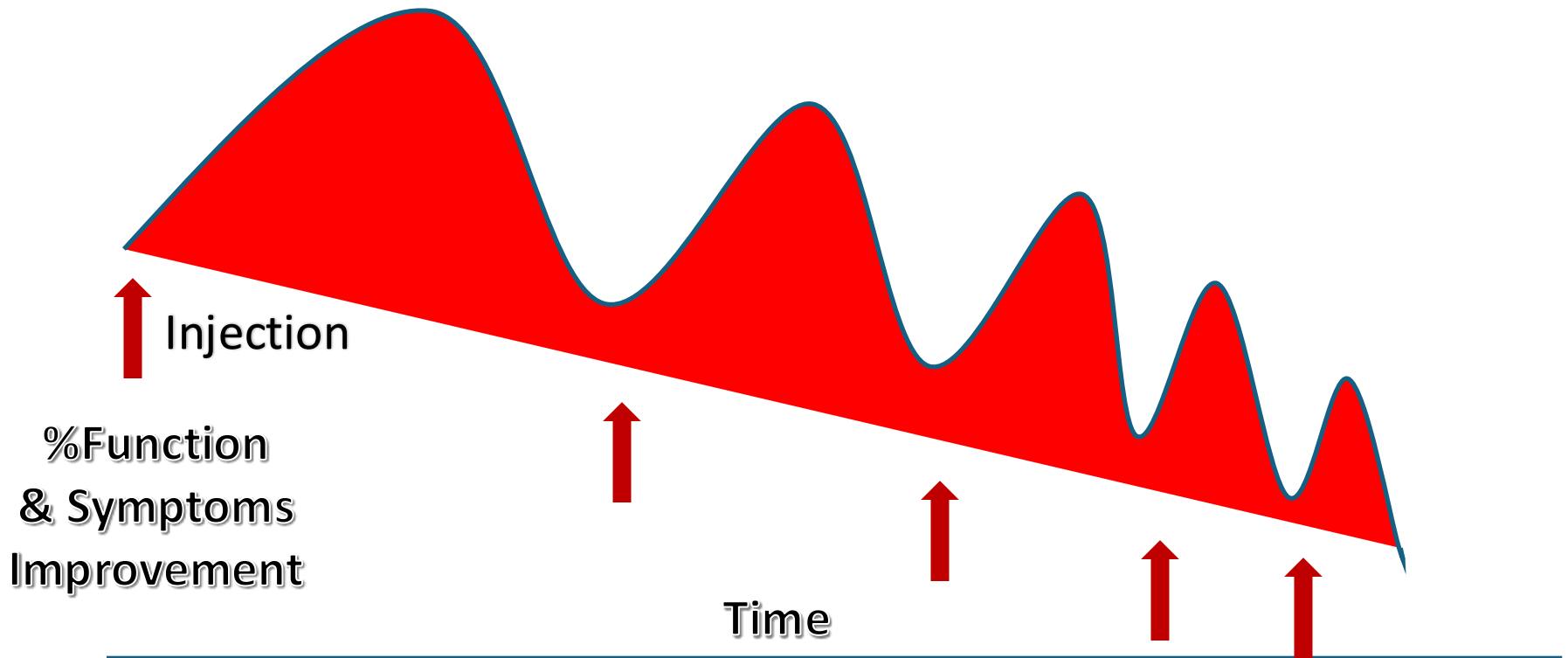
Maintenance



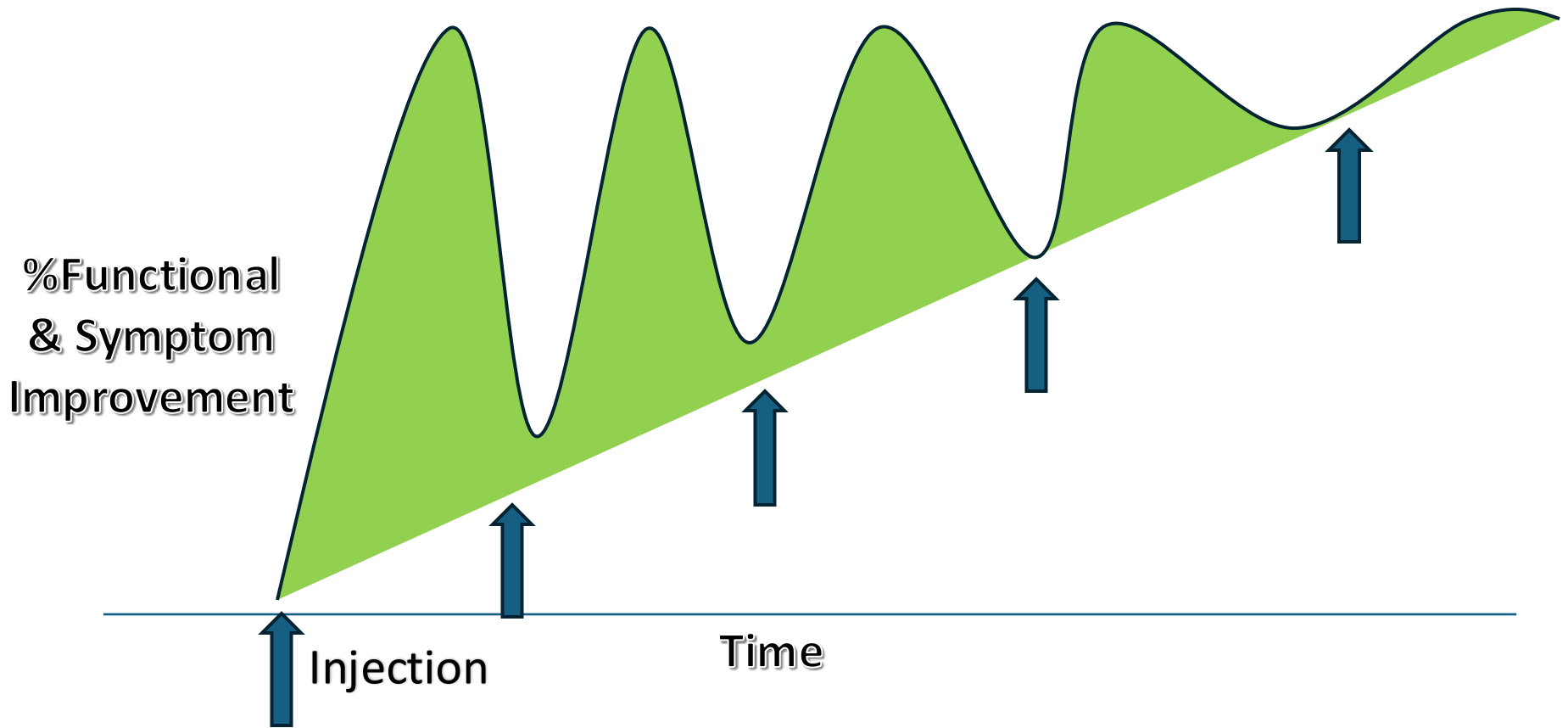


Close only
Counts in
Horseshoes,
Hand-Grenades
and.....
STEROIDS

Steroid Diminishing Returns

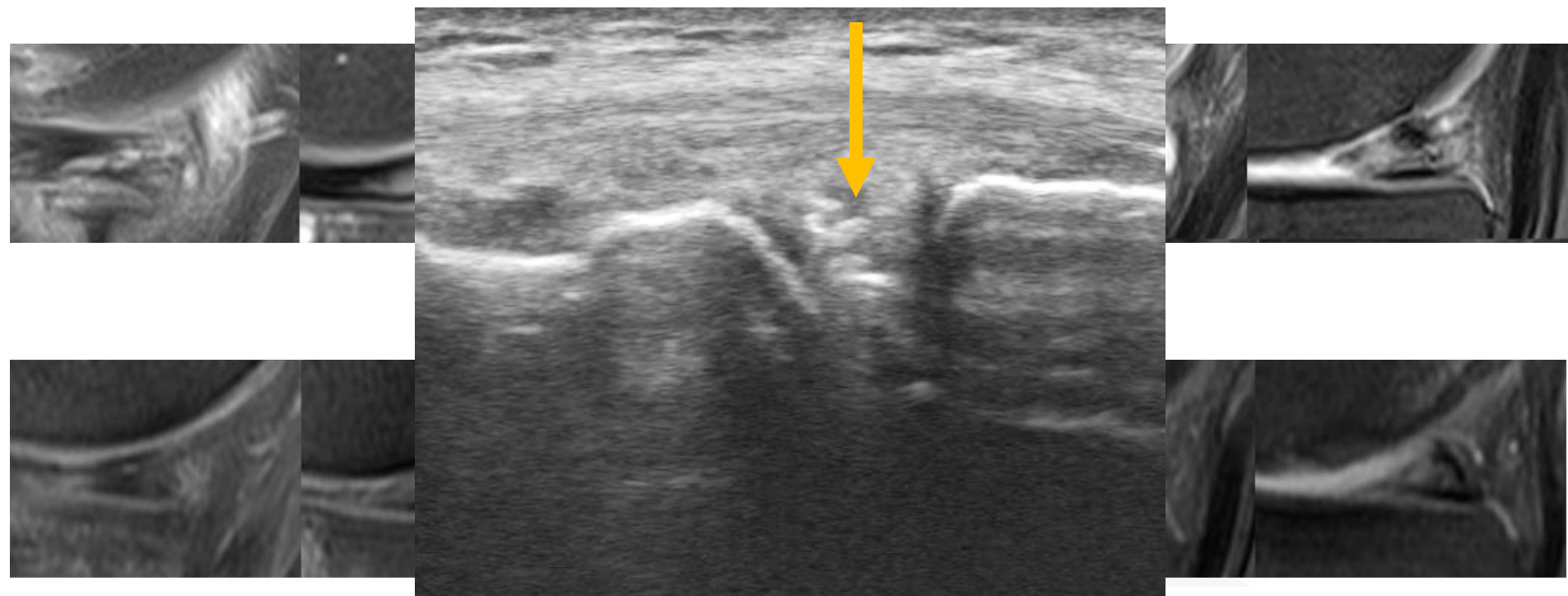


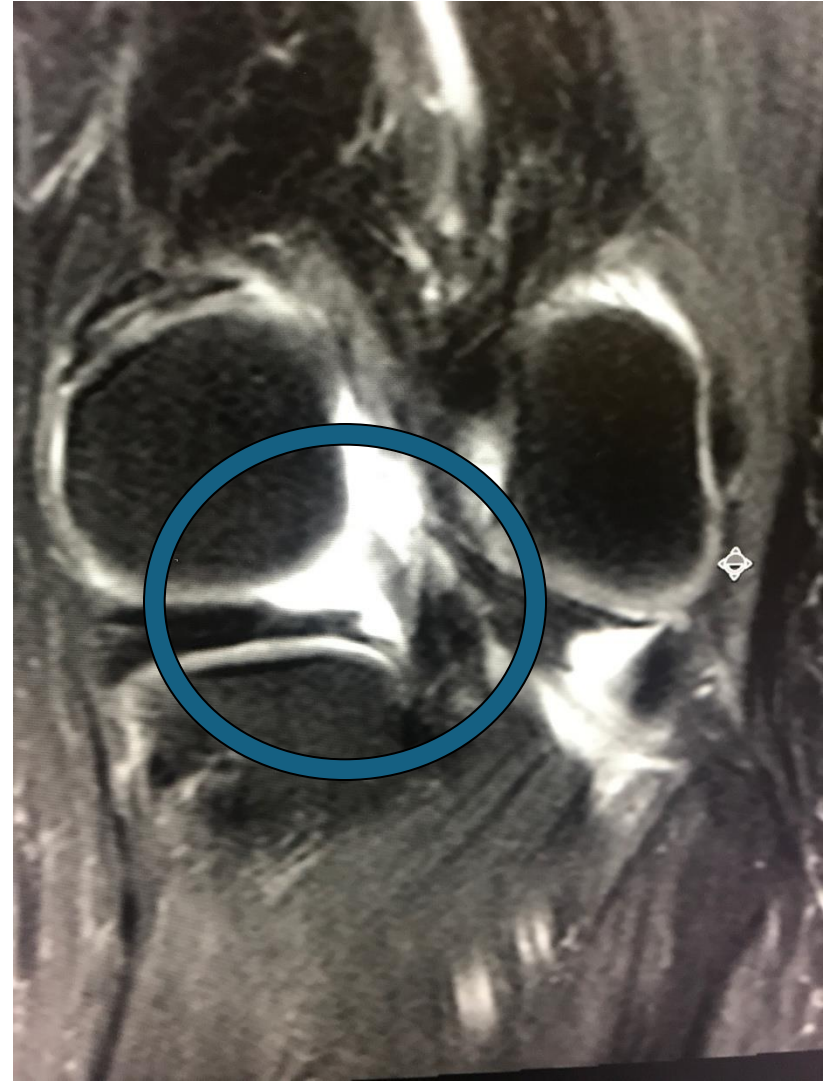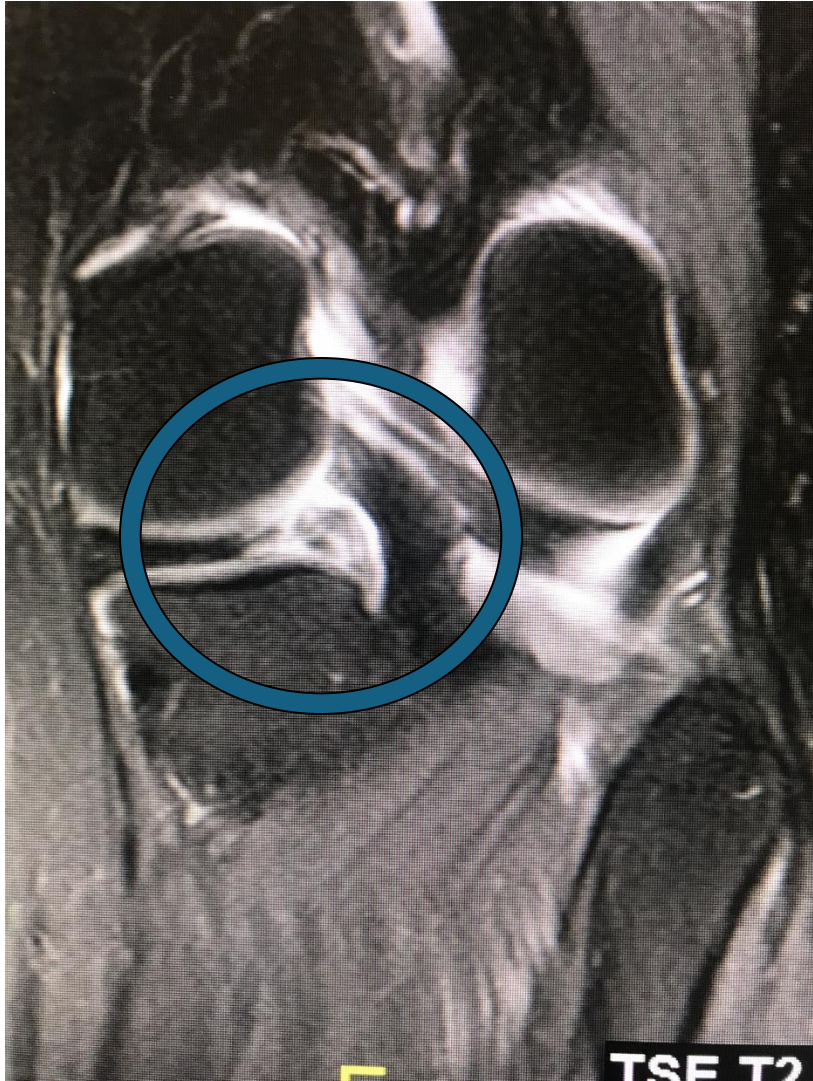
Regen Cumulative Benefits

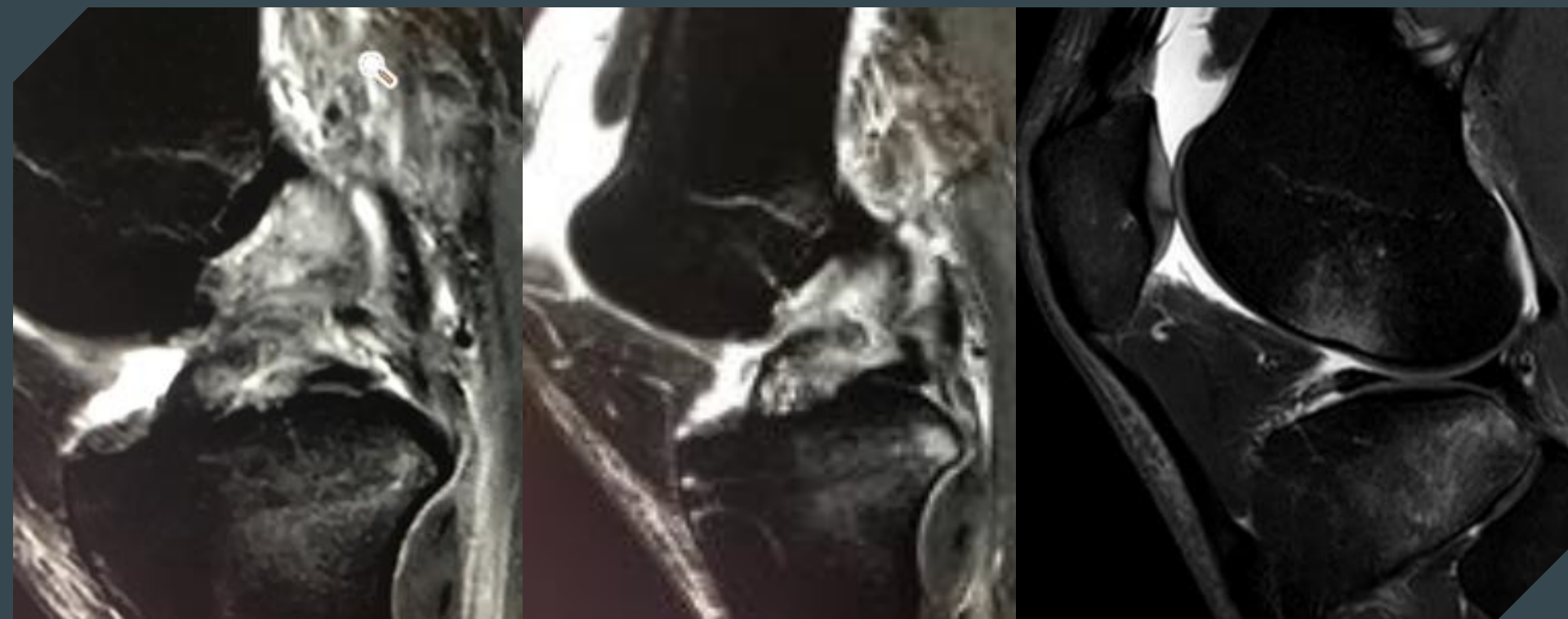


Our Talk is about
the
POSSIBILITIES!

Intra-Mensical Therapy








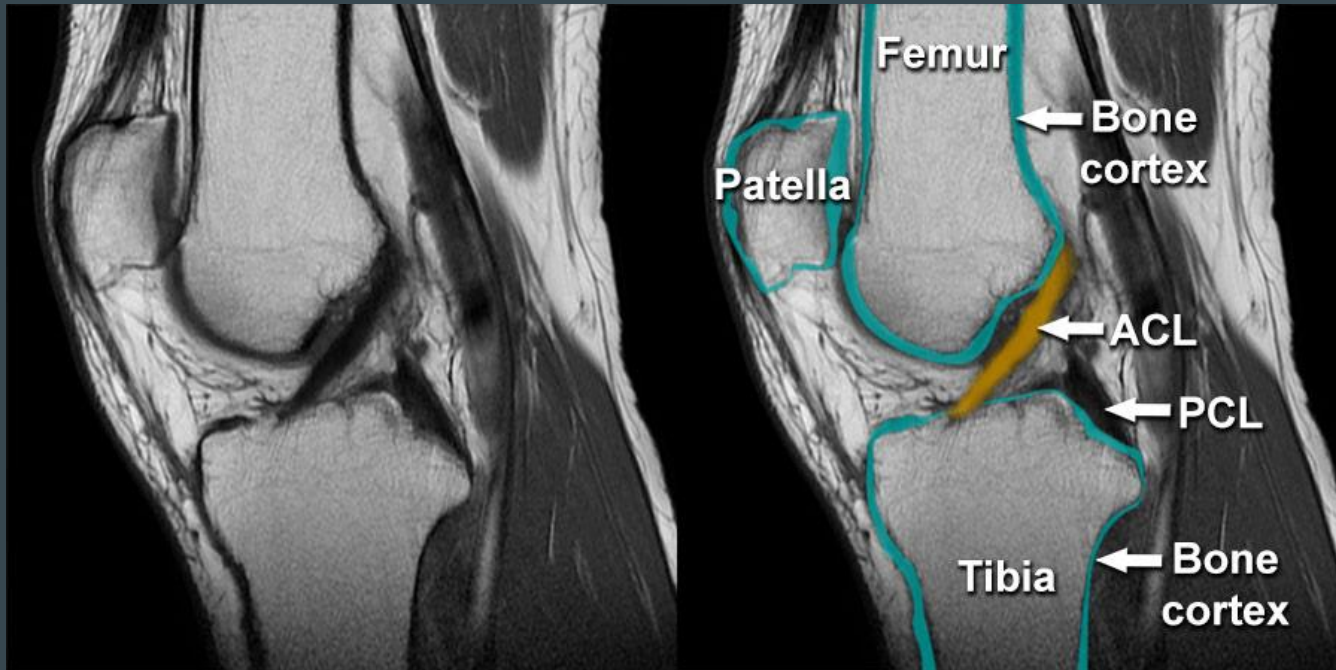
Complete ACL tear?

Ligament & Tendon Healing Biologically Active Scaffold

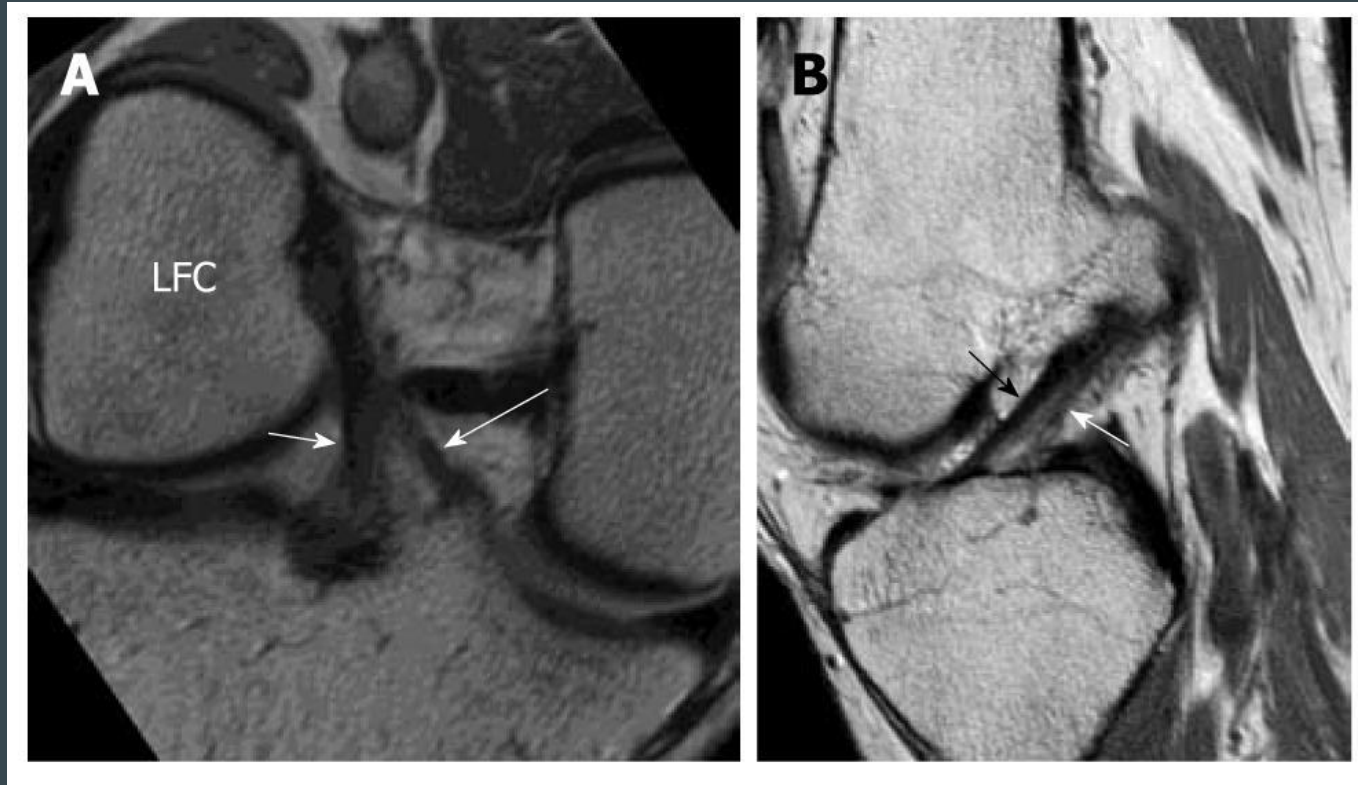
53



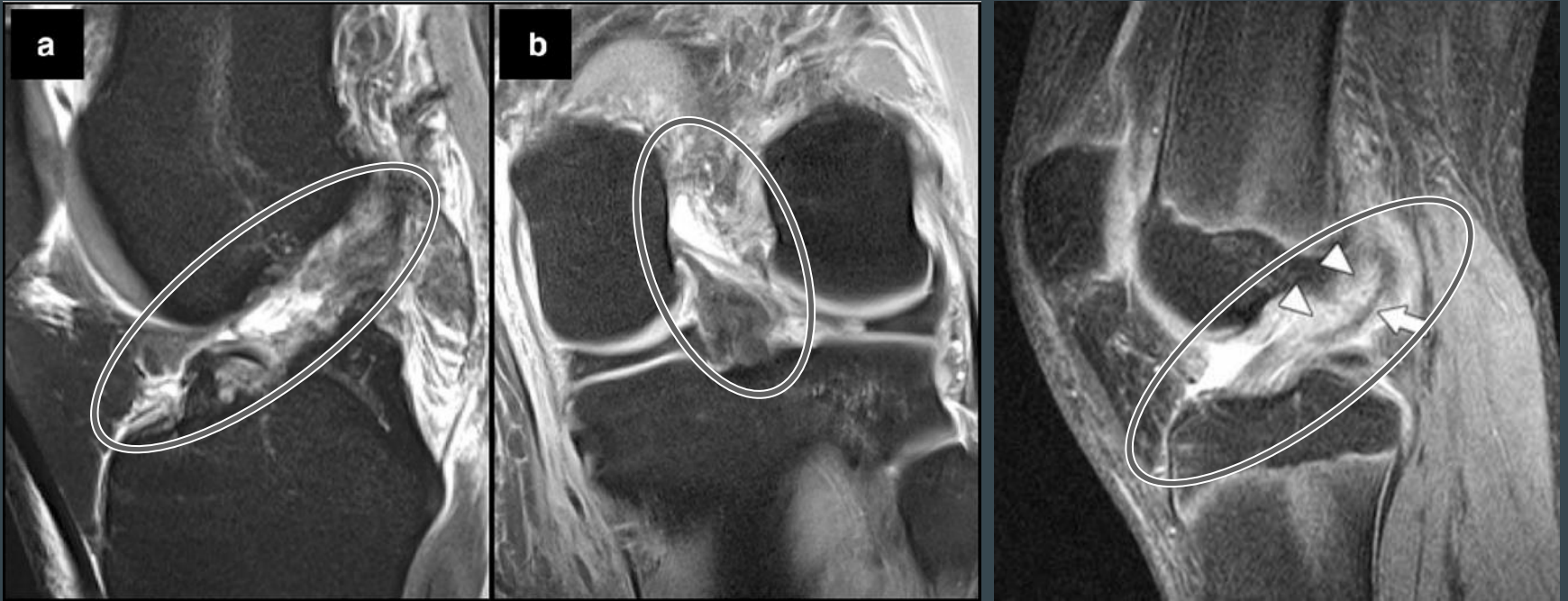
Normal



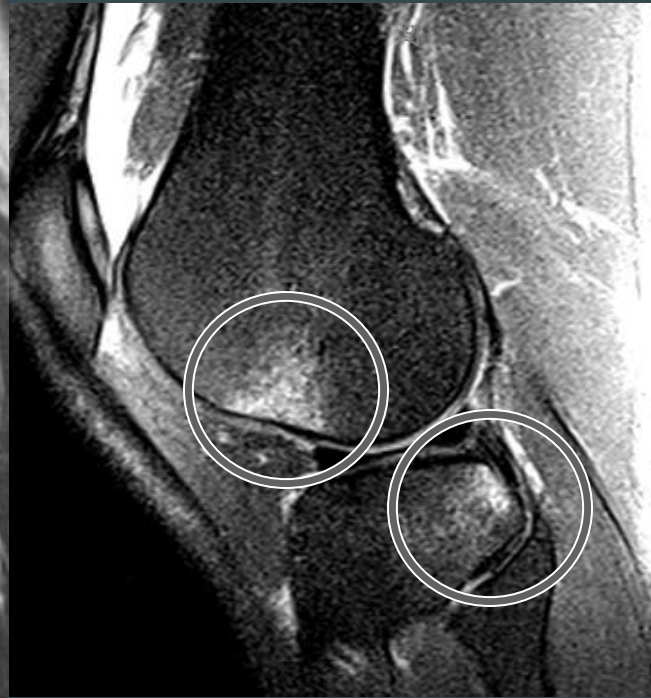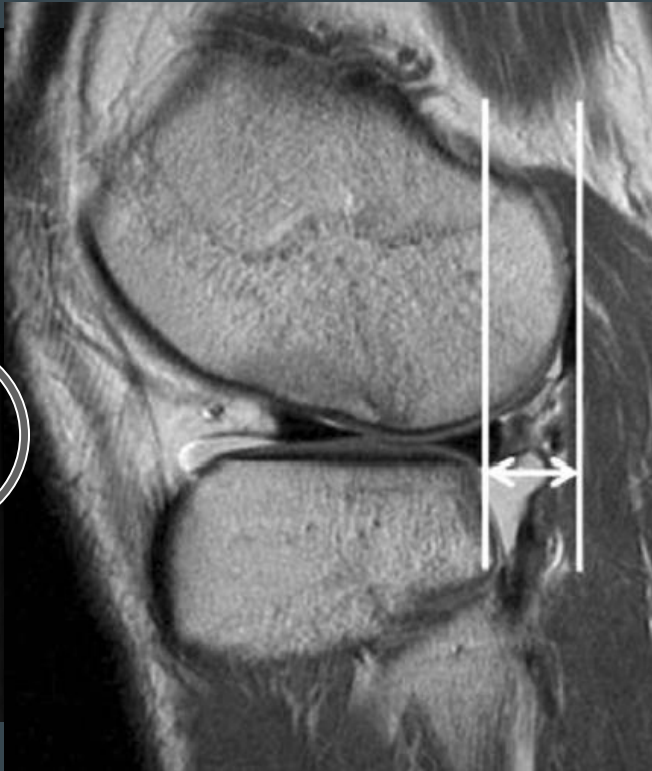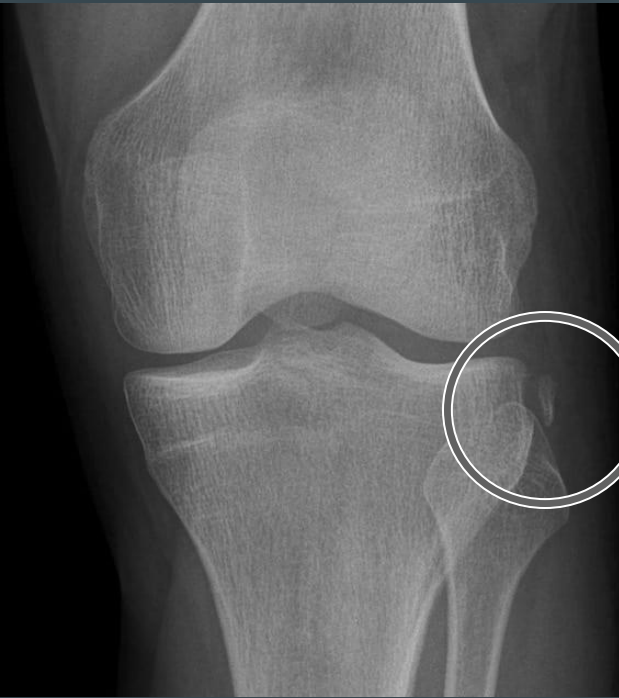Oblique Coronal and Sagittal Planes



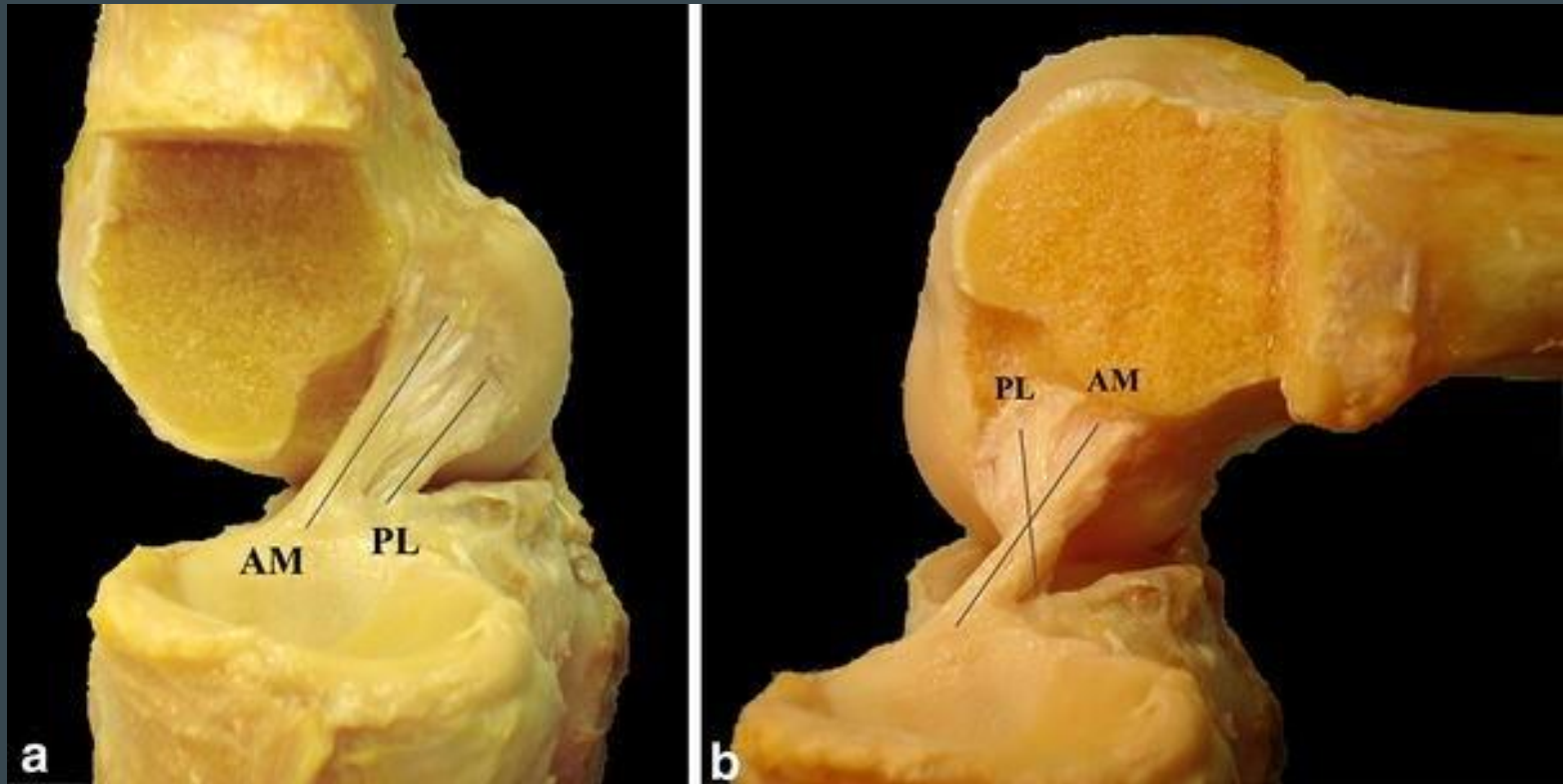
Primary Sign

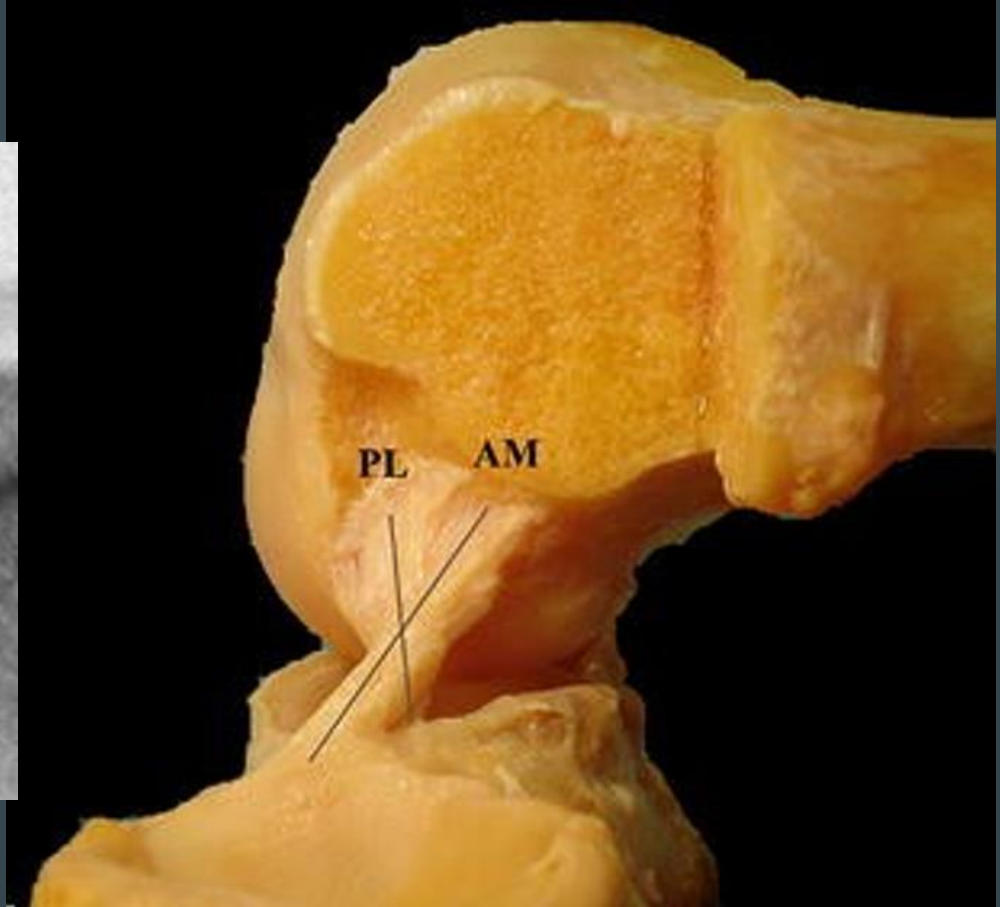
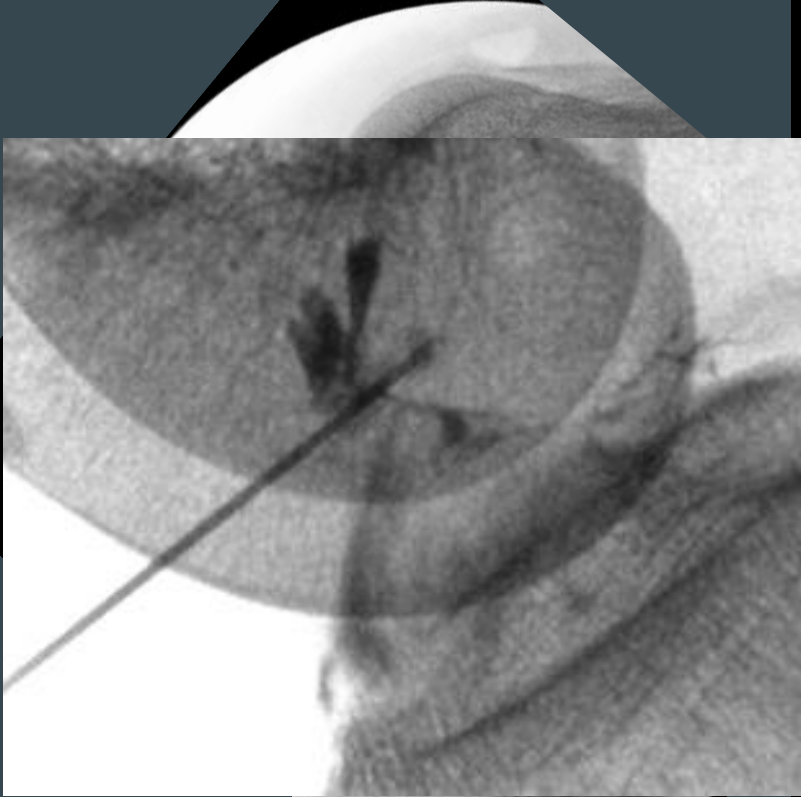

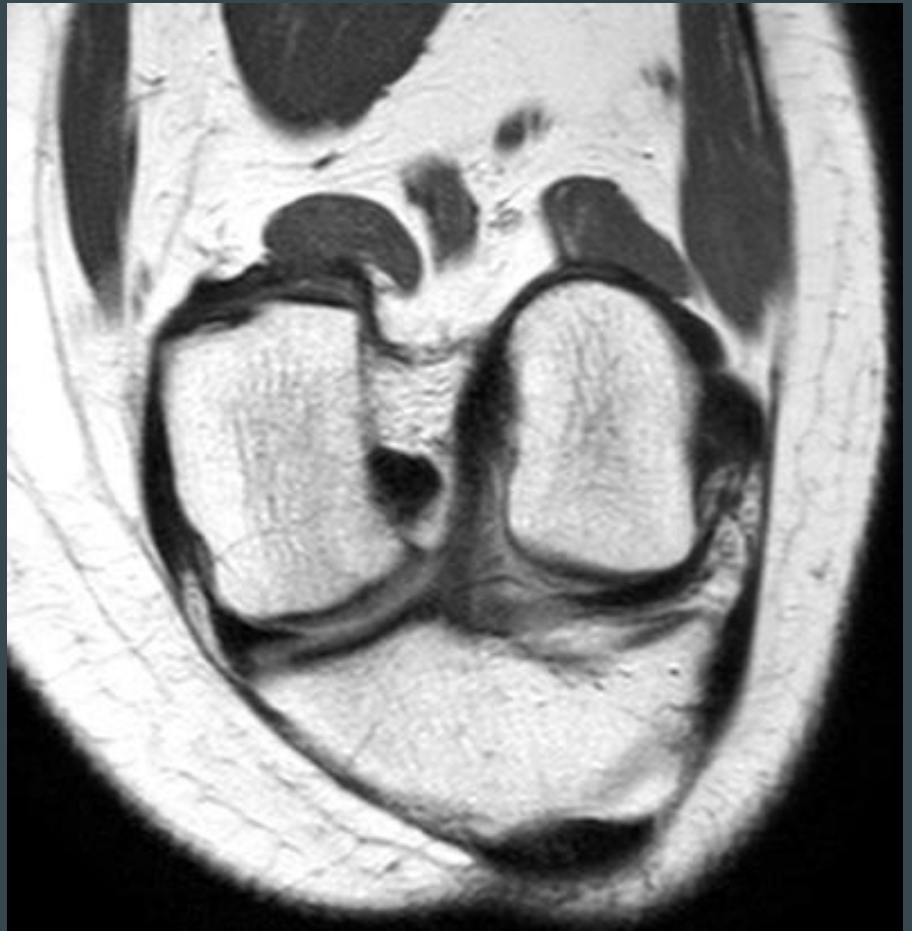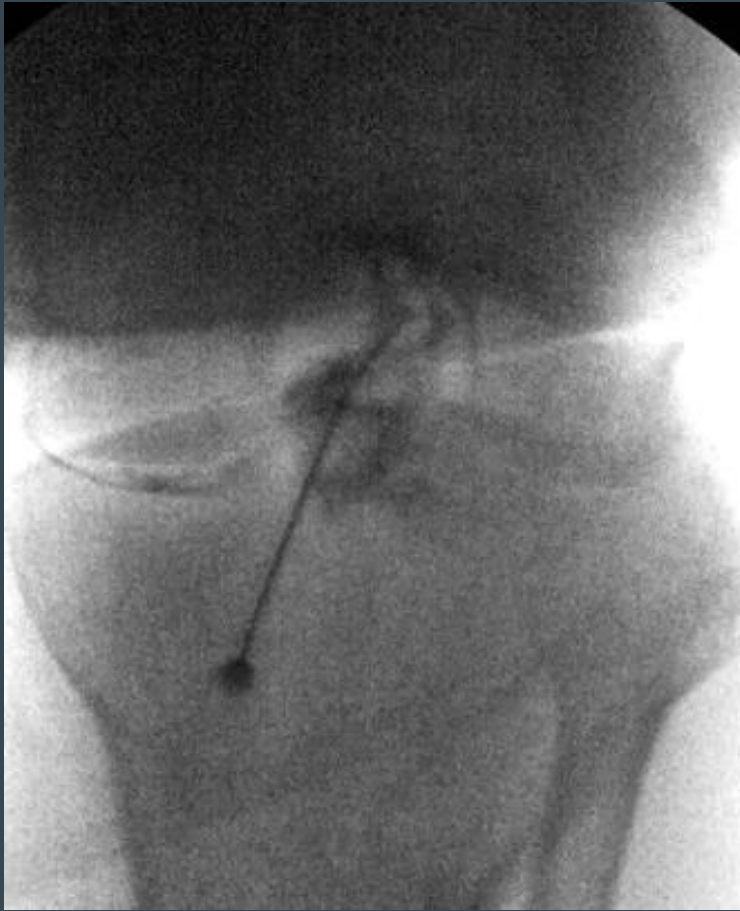Secondary Signs



ACL double bundle – straight & flexed knee





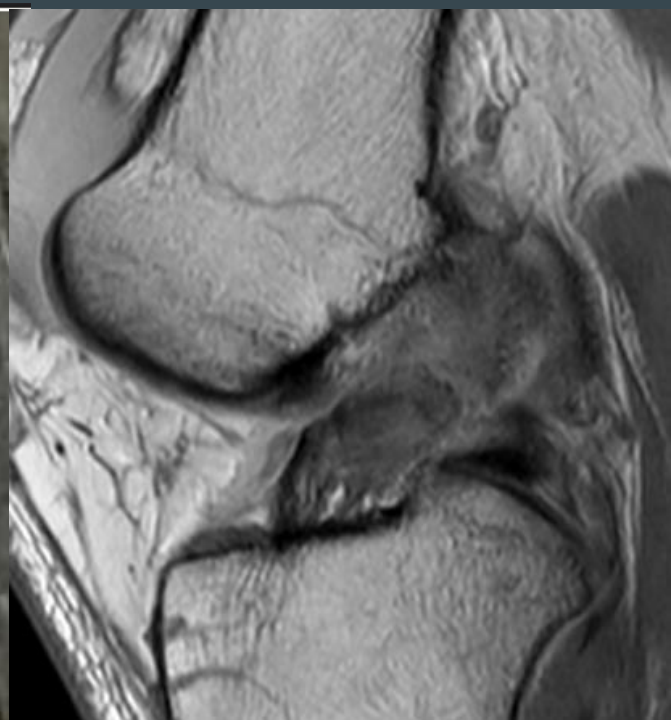
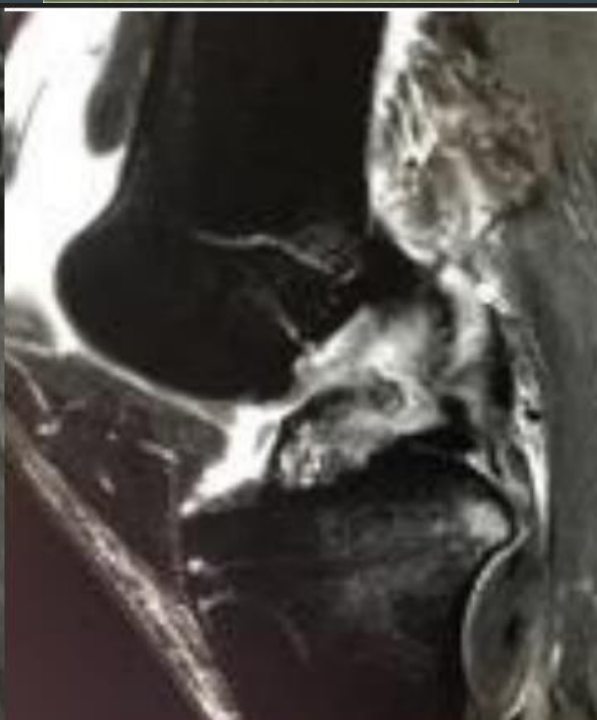
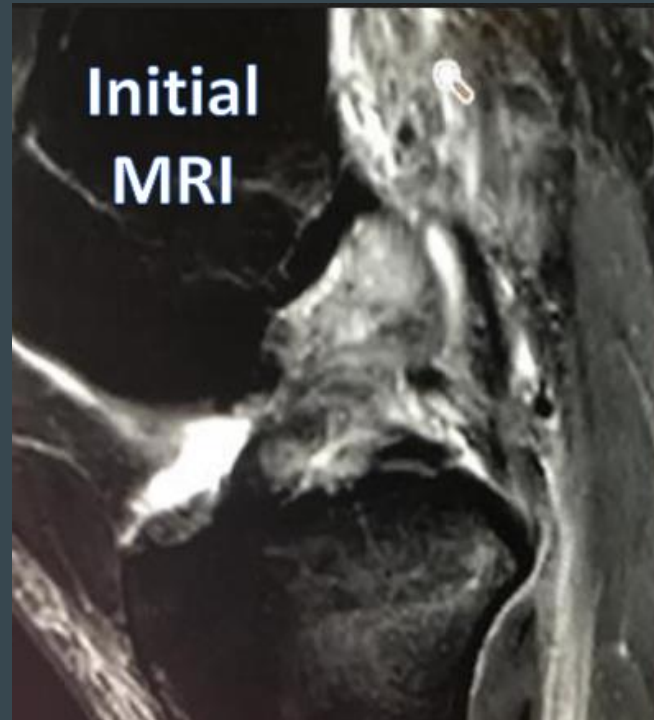

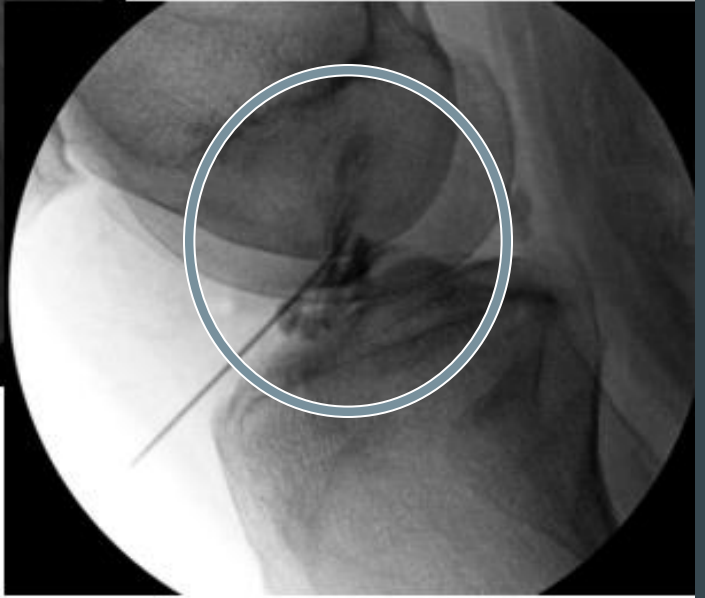
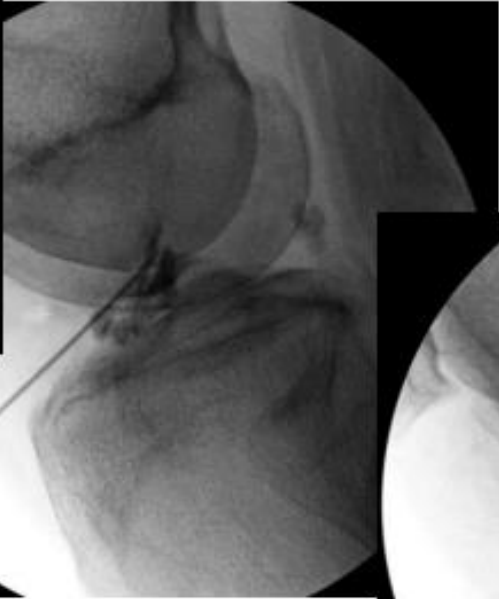
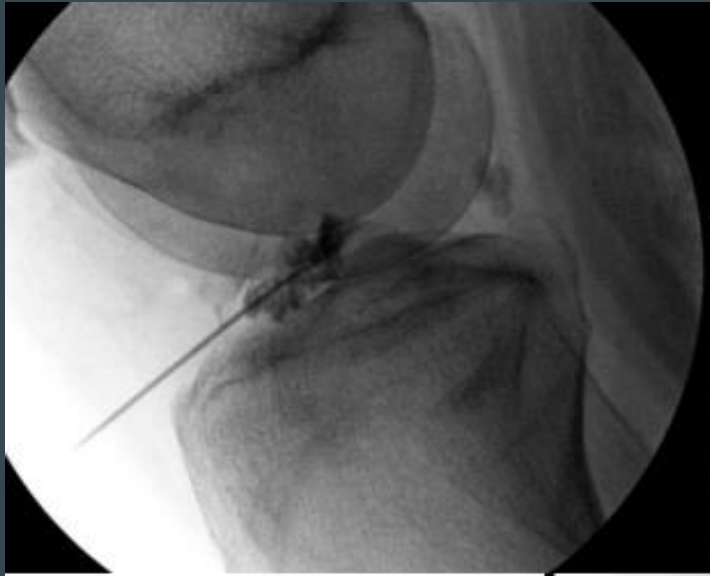
32 yo female

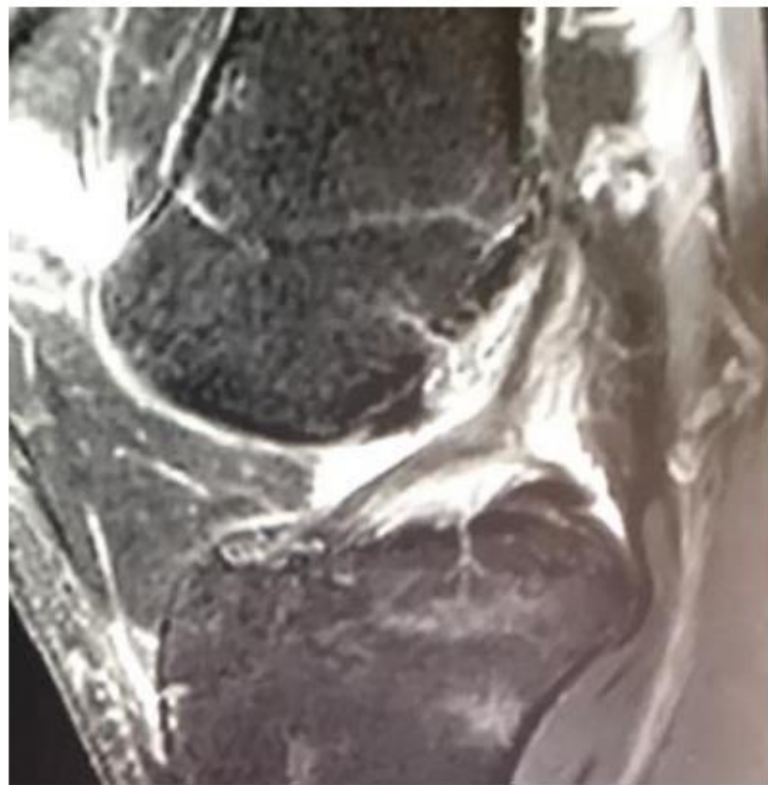
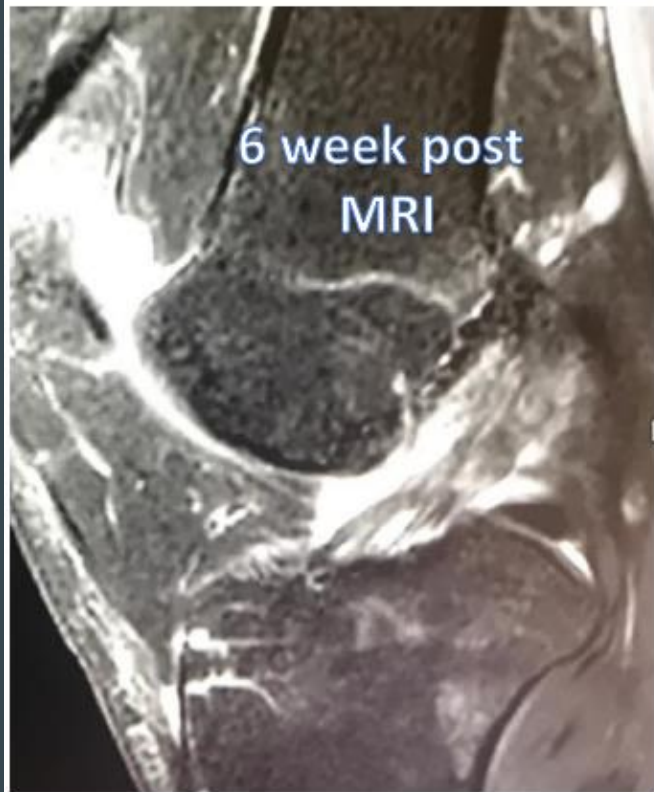


61

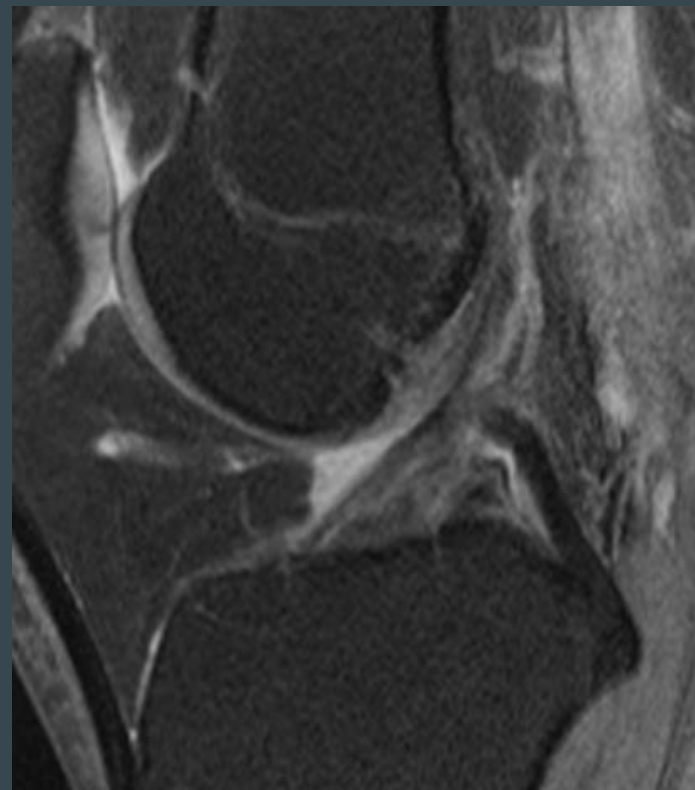
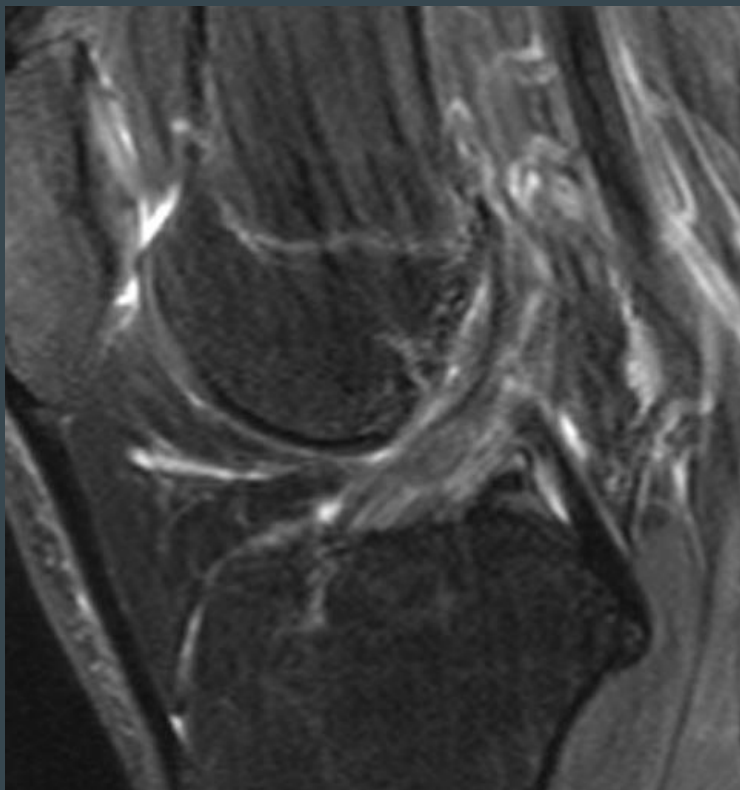
Initial
MRI







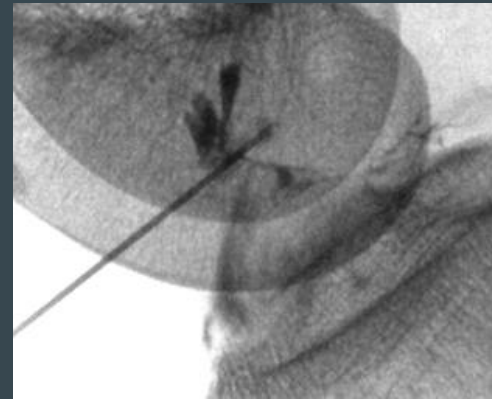
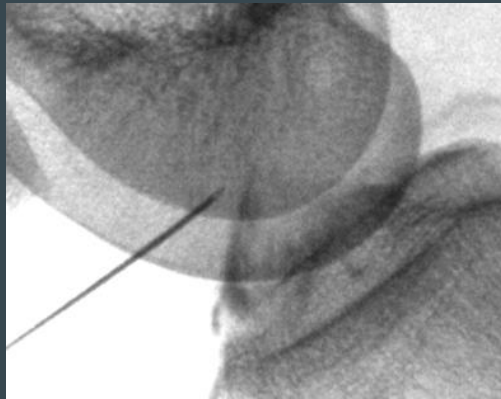
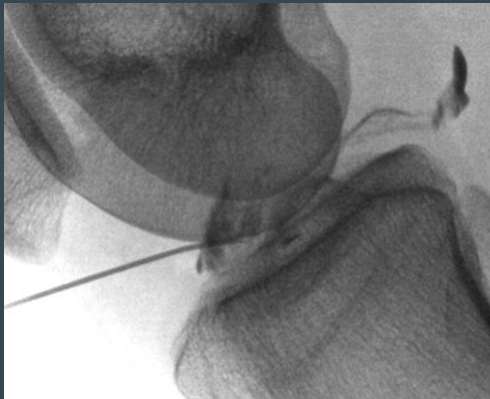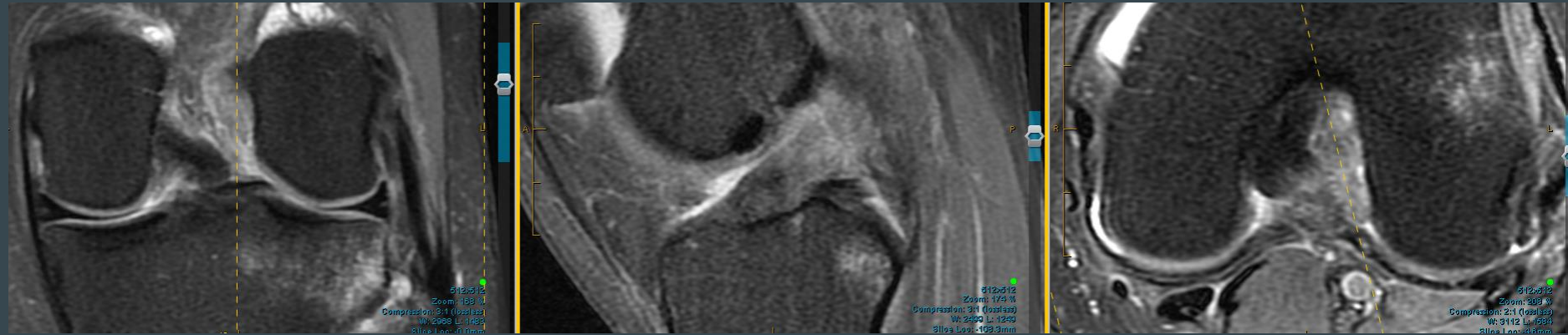6 month post-procedure



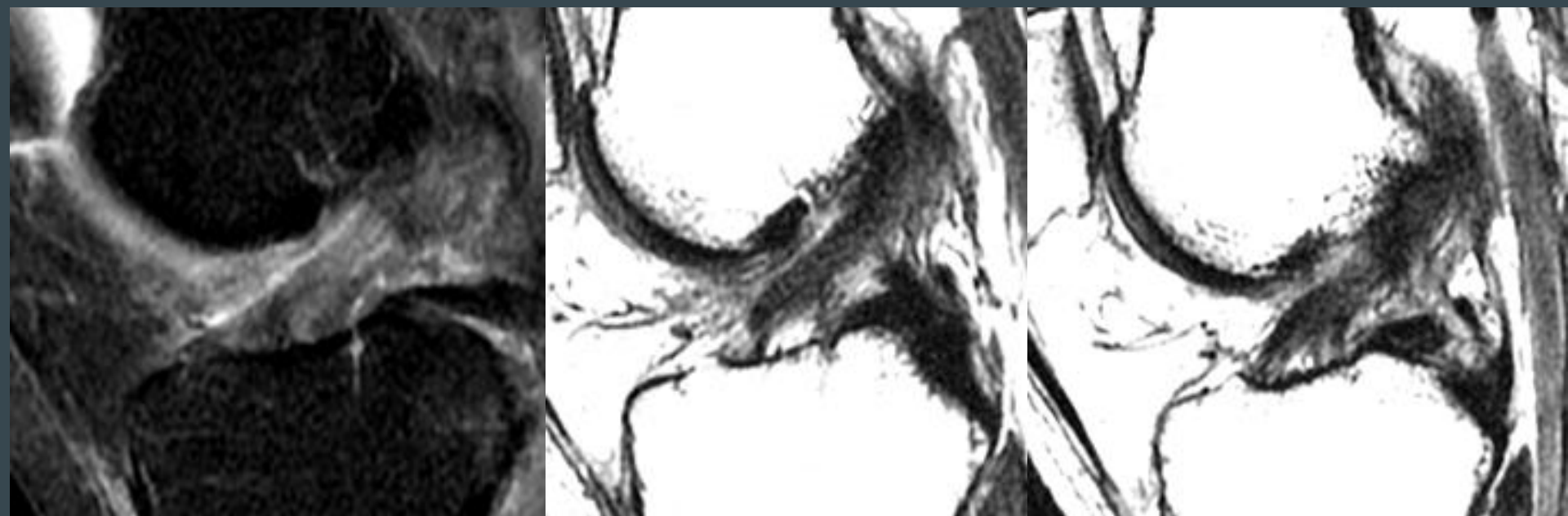40 yo Ski injury



Oct 25, 2018 MRI Nov 28, 2018 Treatment



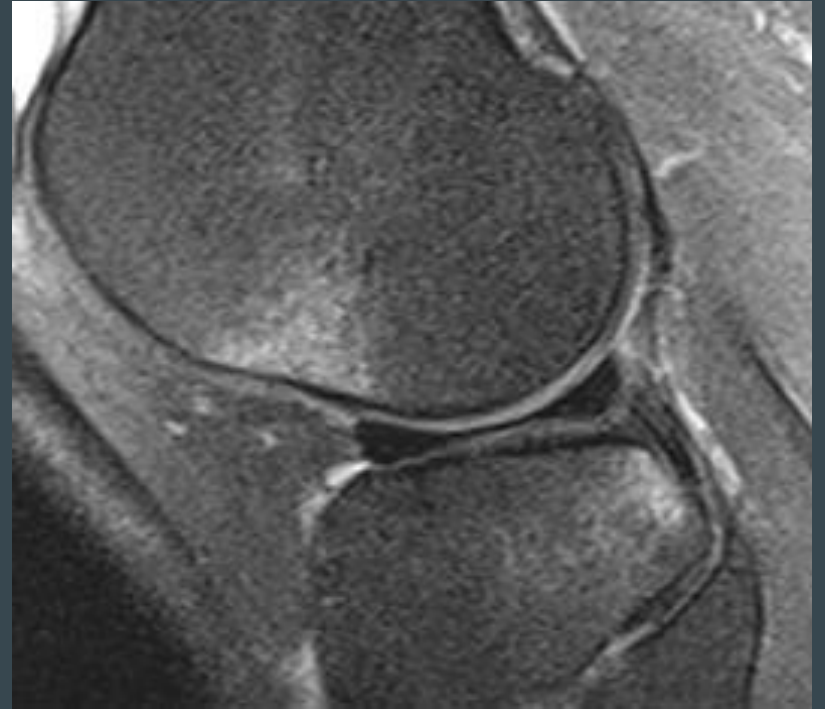
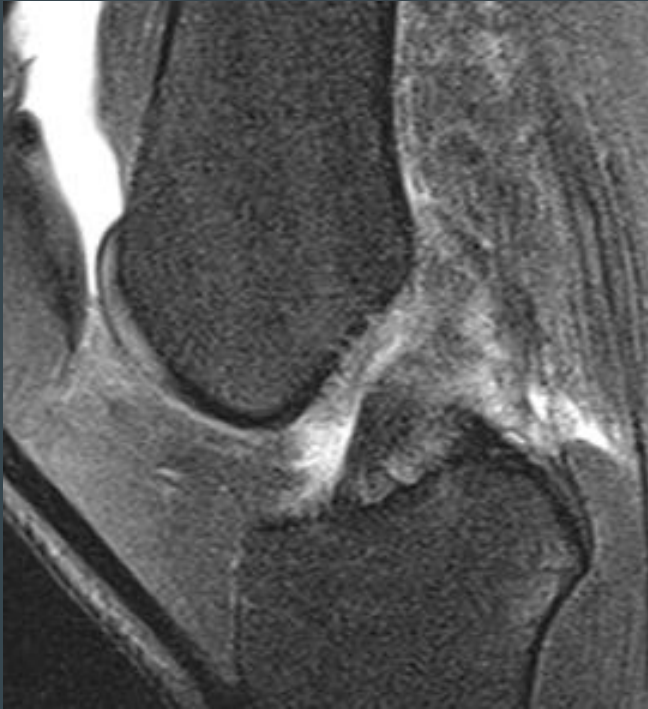April 15, 2019



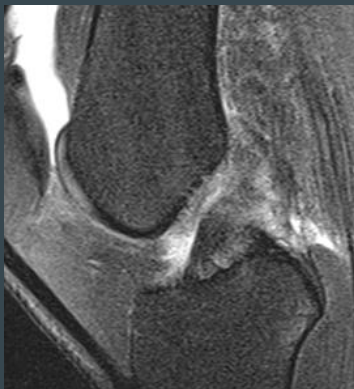Another Ski Injury



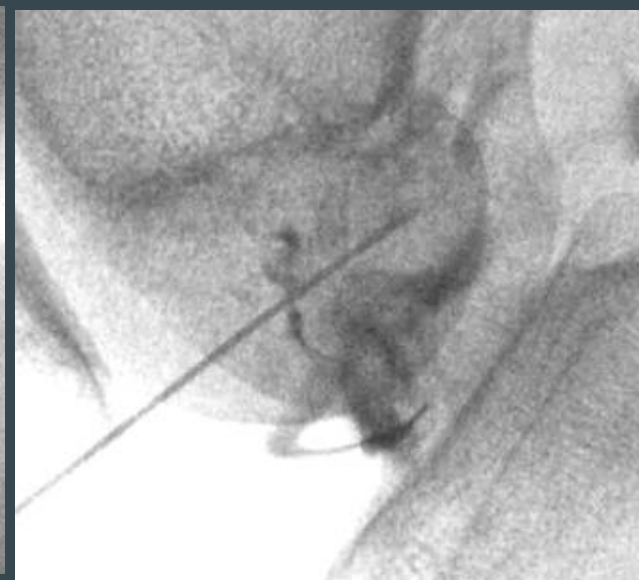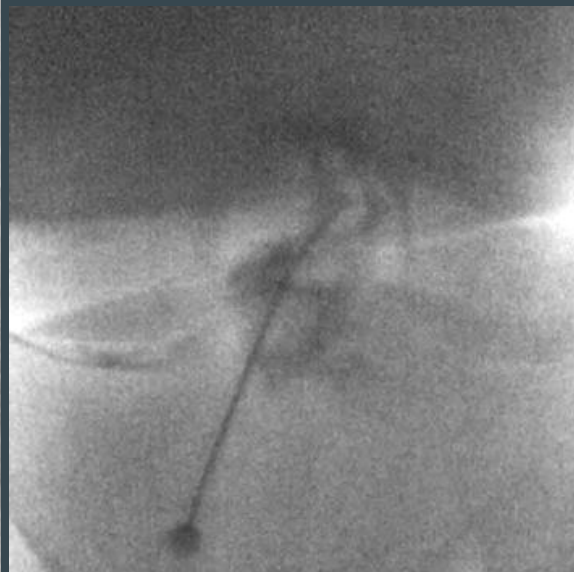
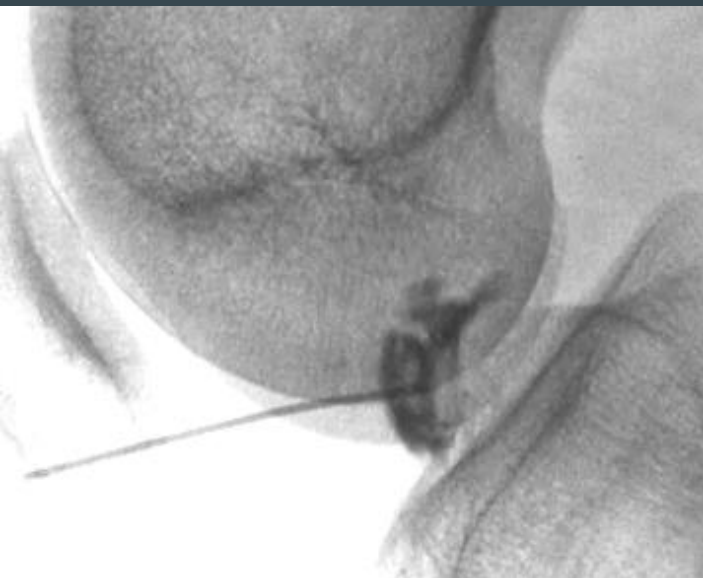Complete Tear Proximal Root



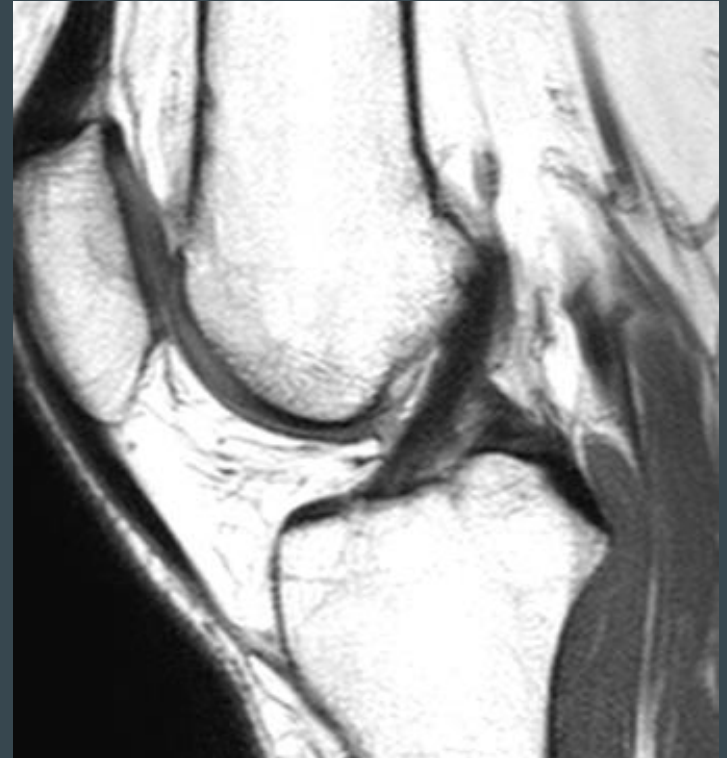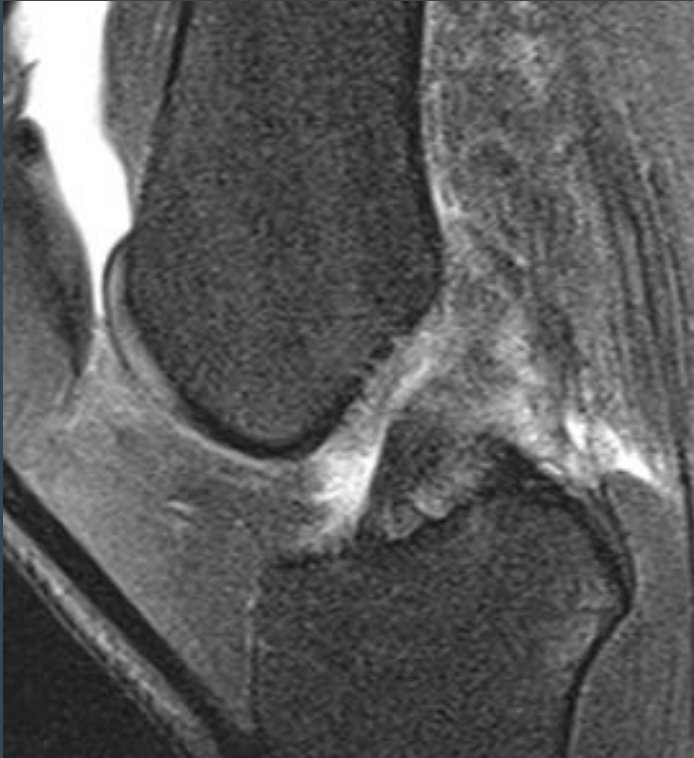March 22

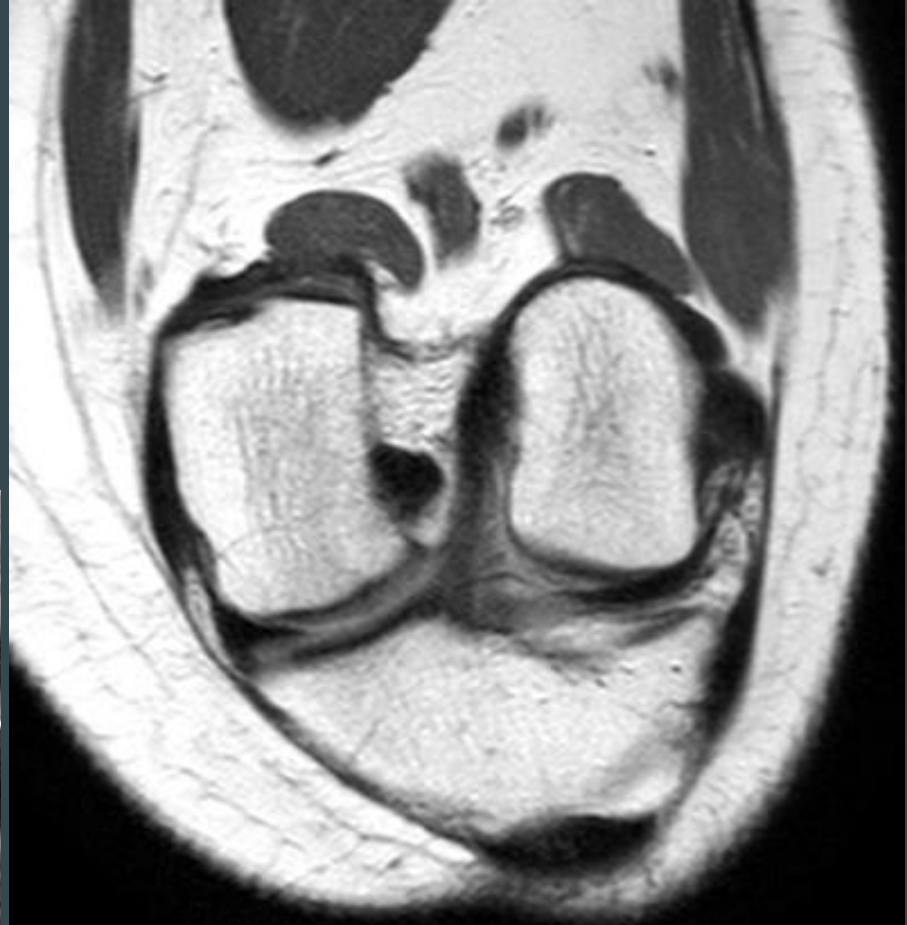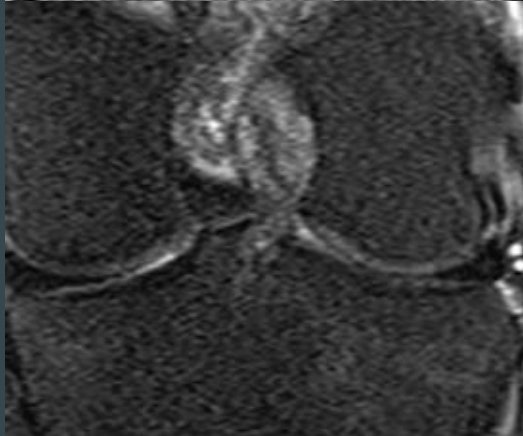

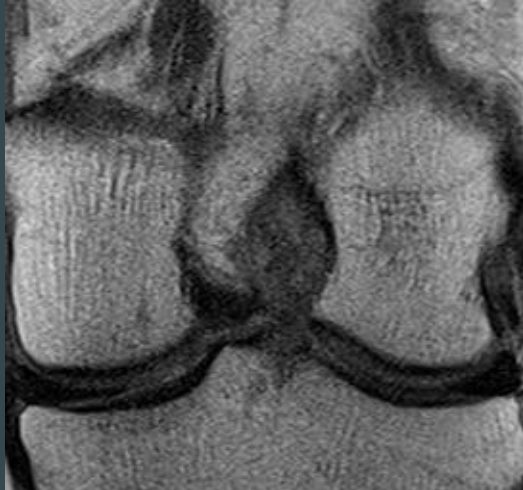
70



Feb 22 to Feb 23

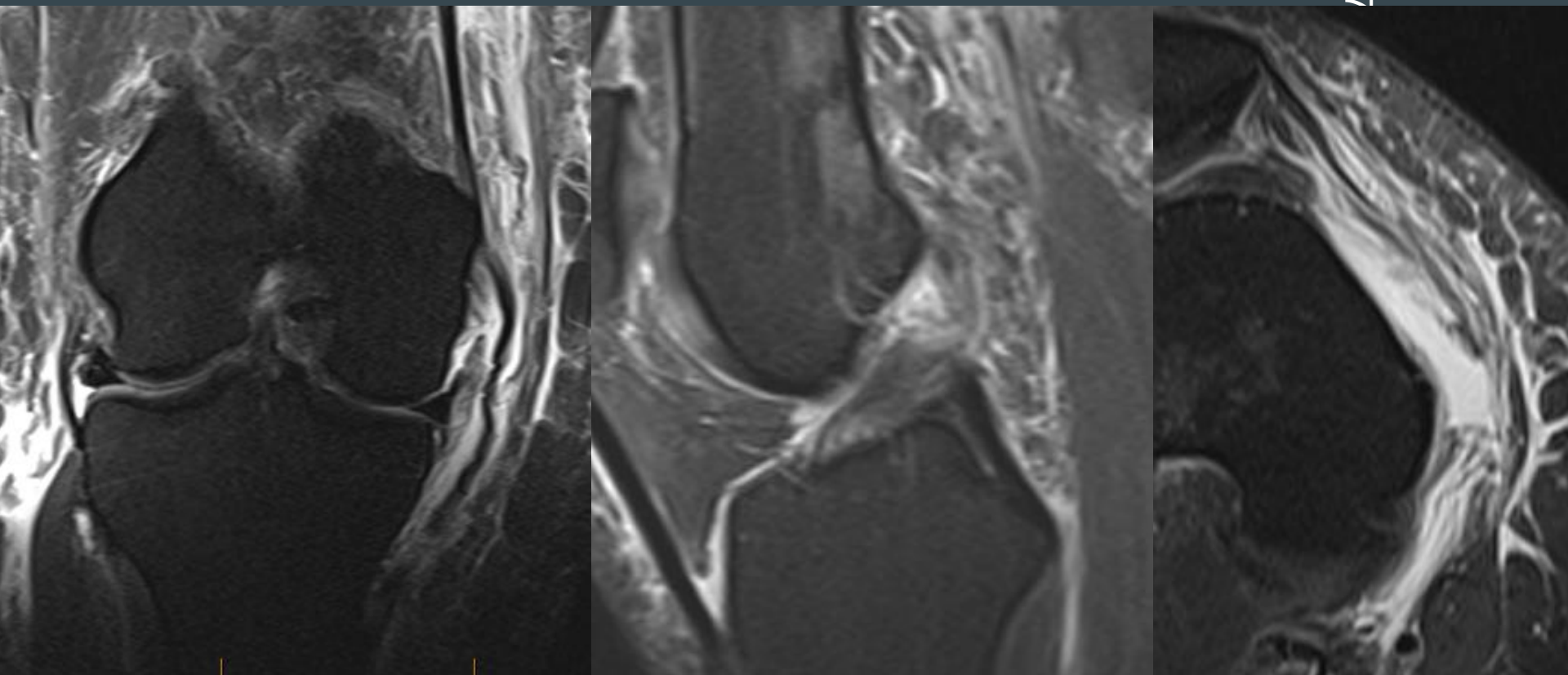


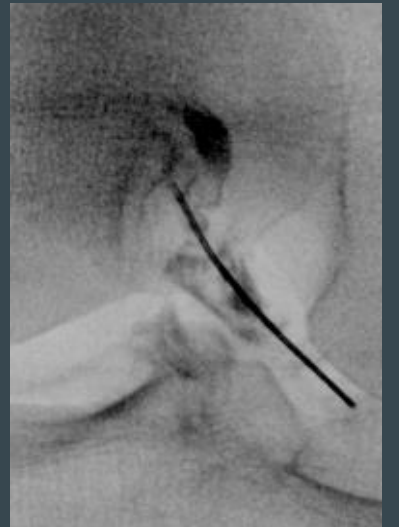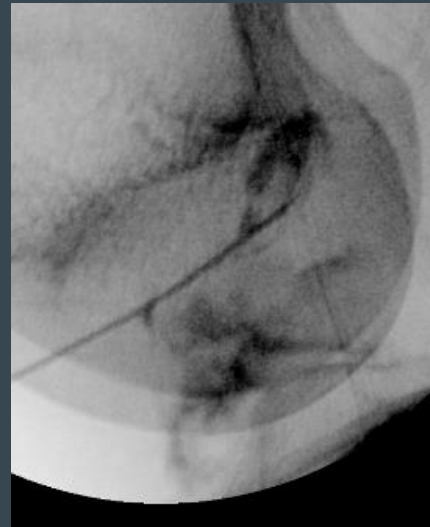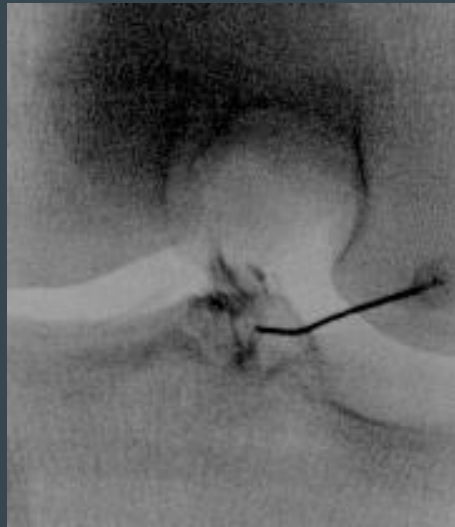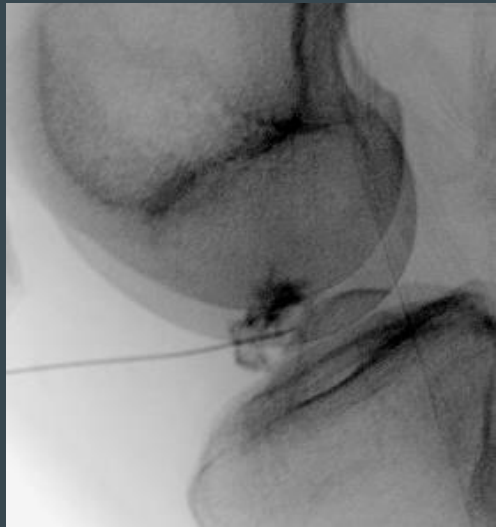


Horse Kick

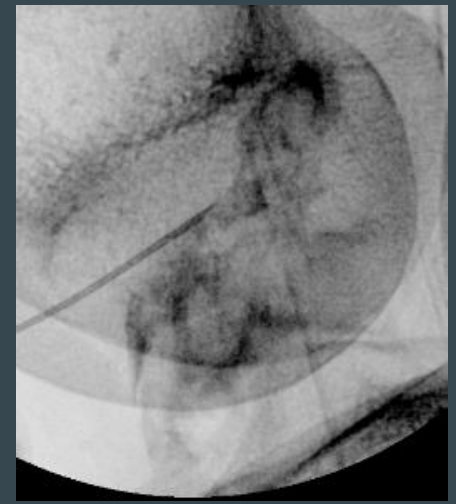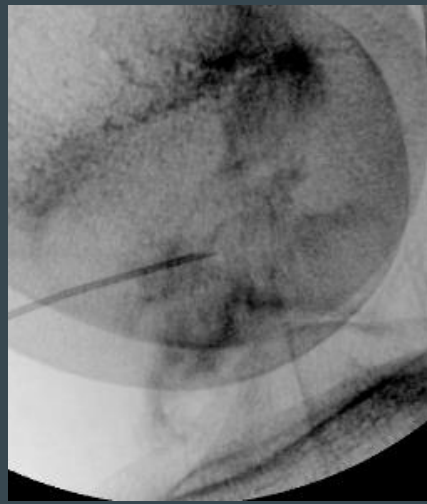

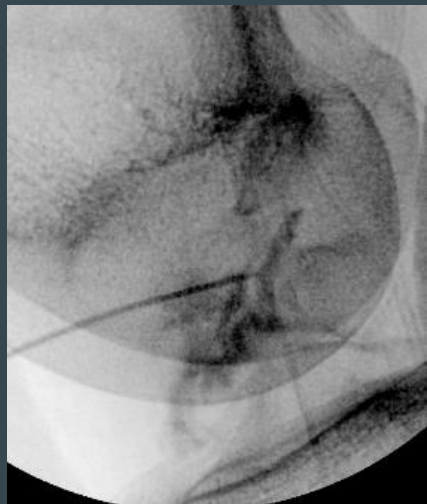
JP Knee - Sept 10, 2023

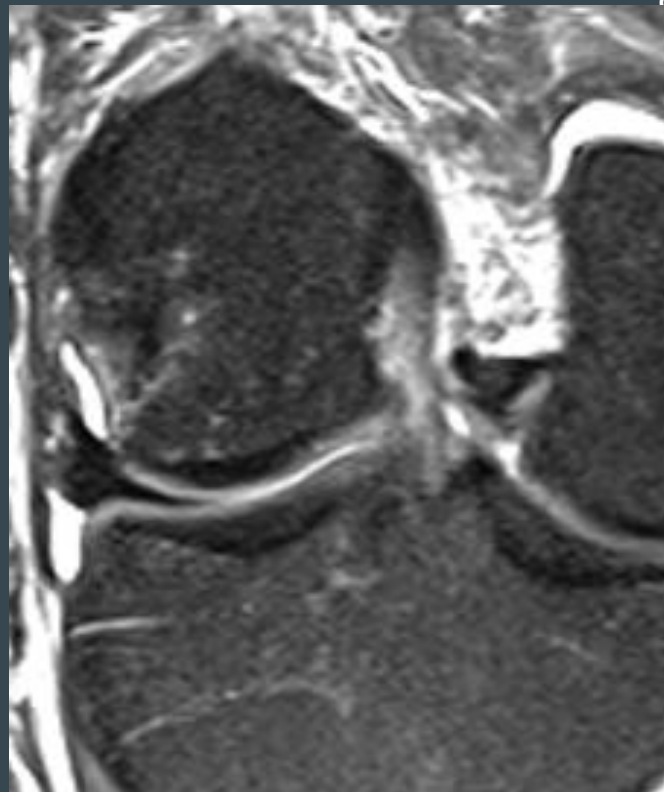
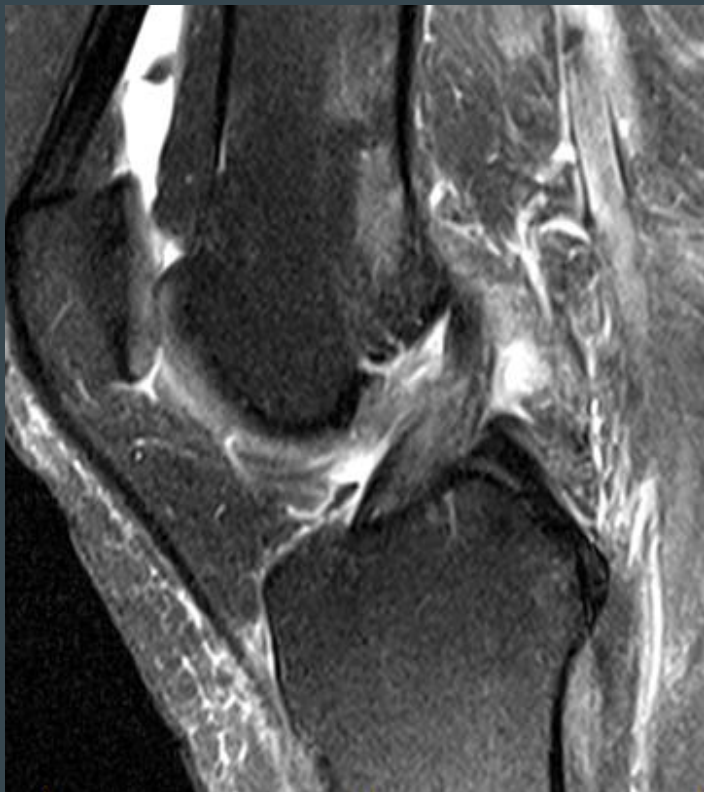




Oct 5, 23



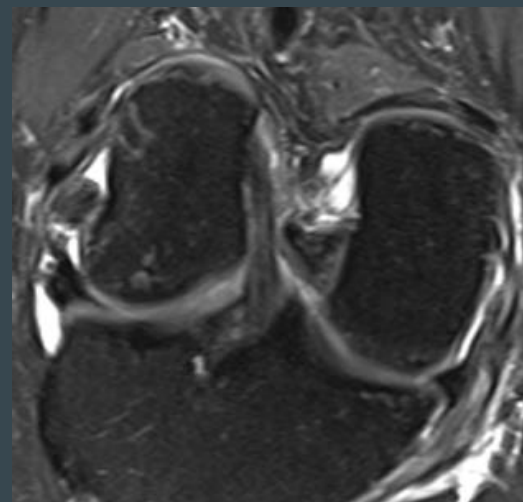
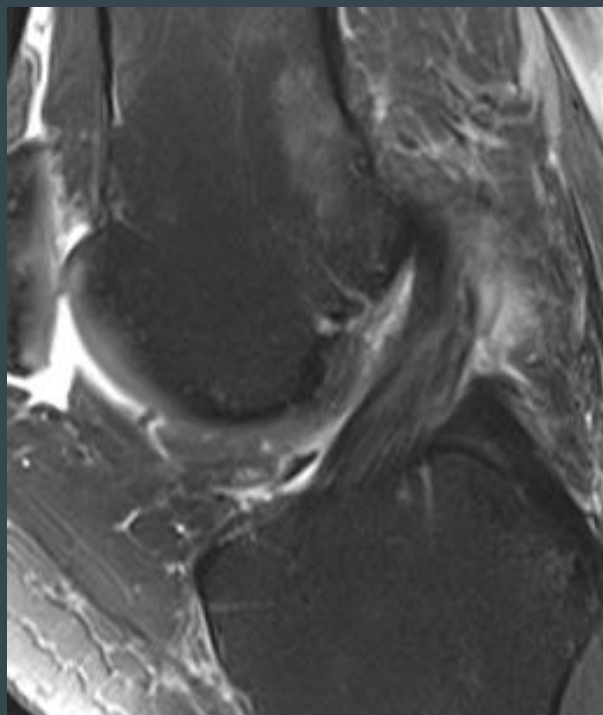
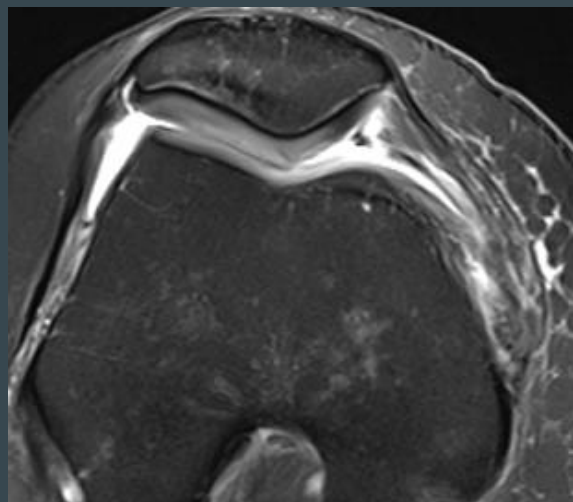
Nov 24, 2023



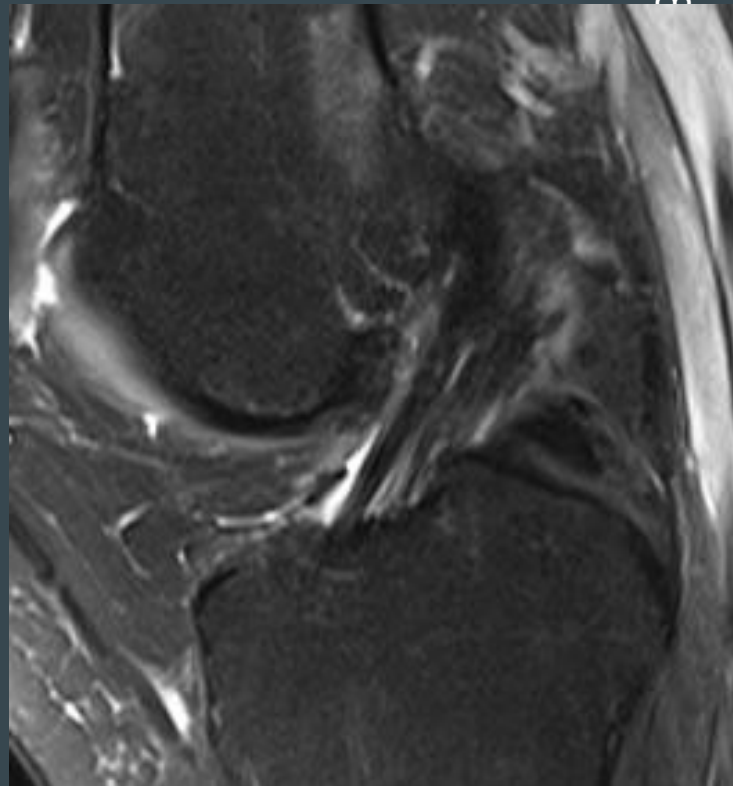
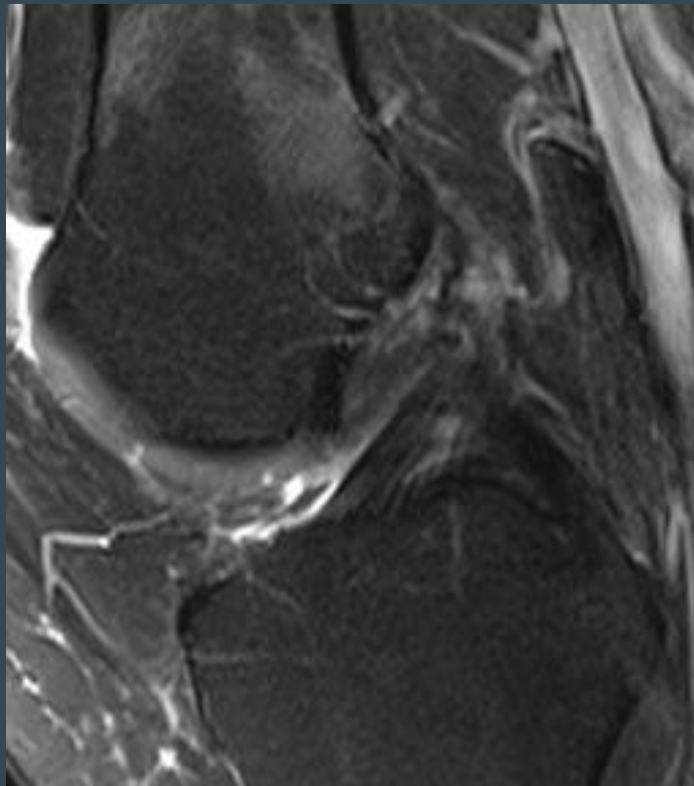
76

JP Knee – Dec 28, 2023

77

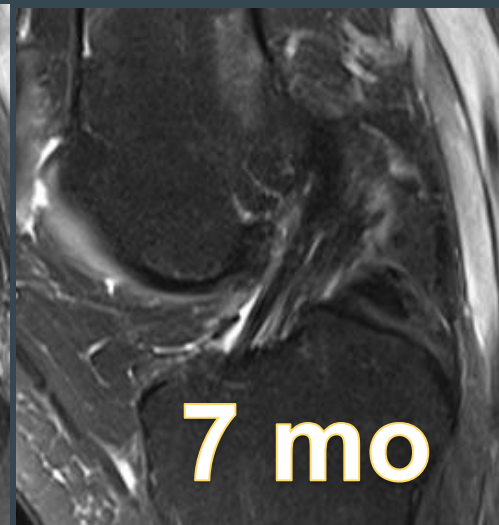
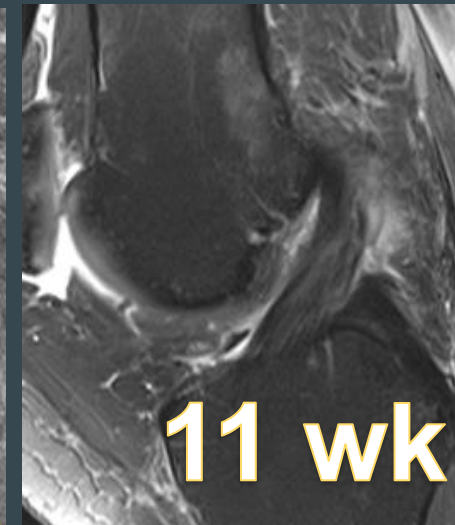
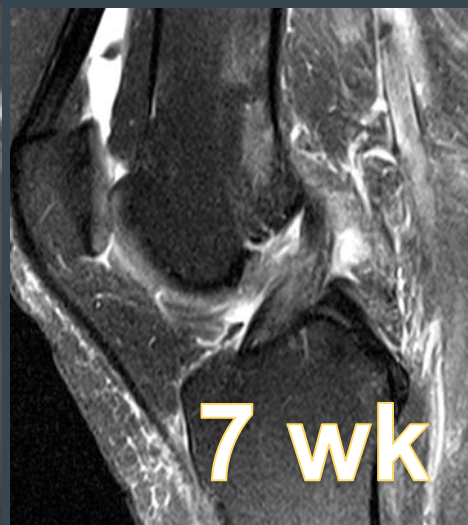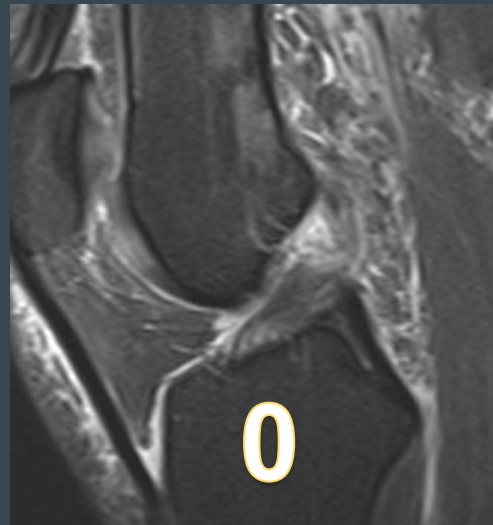


Healed ACL

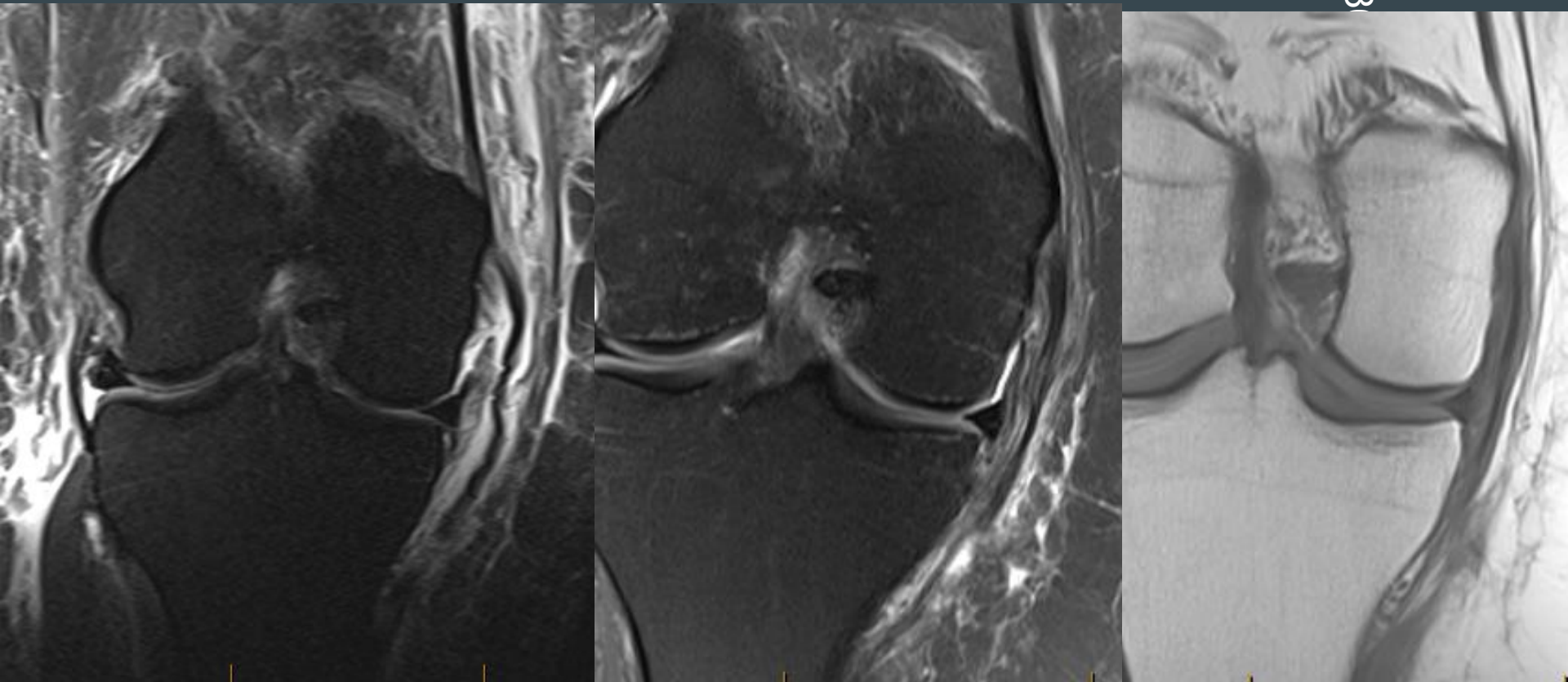


Progression of Healing

79



MCL Healing – 0,3,7 months




DOES IT MATTER IF IT STICKS
AROUND?

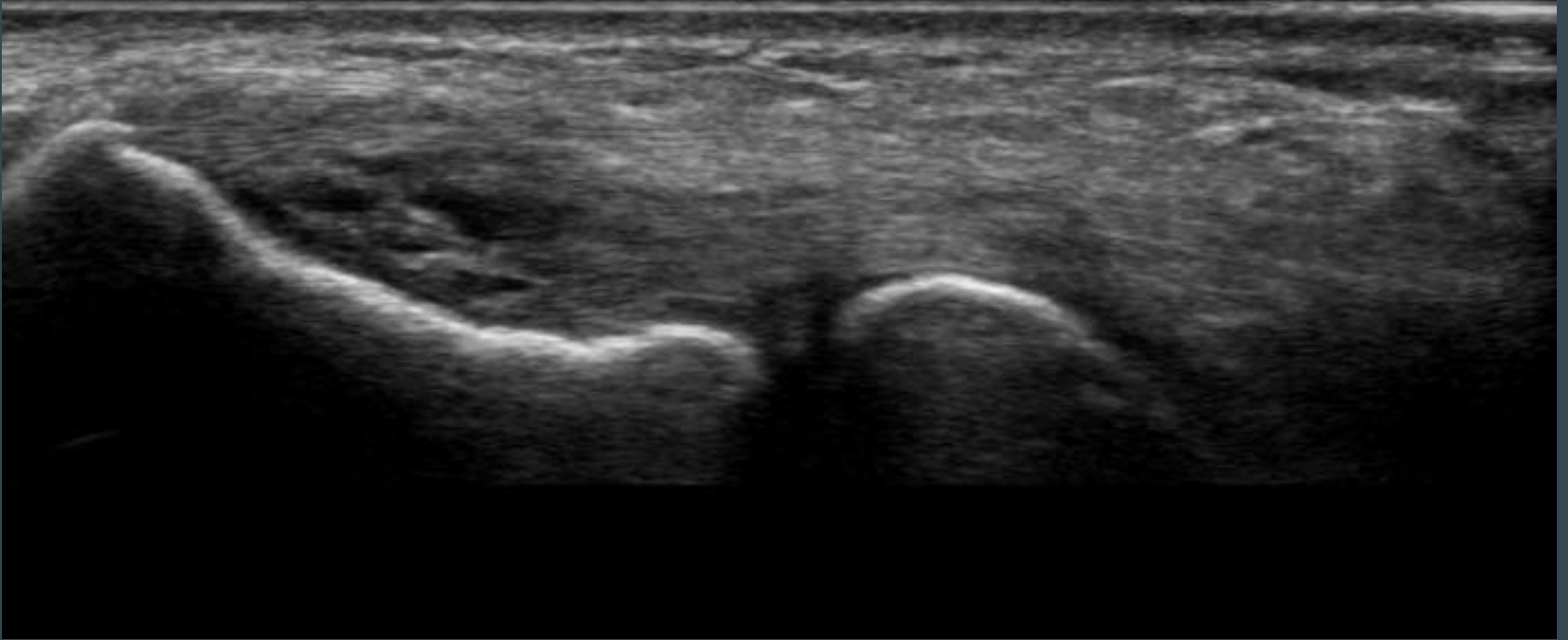
Bioscaffolds?



Ligament Healing Biologically Active Scaffold

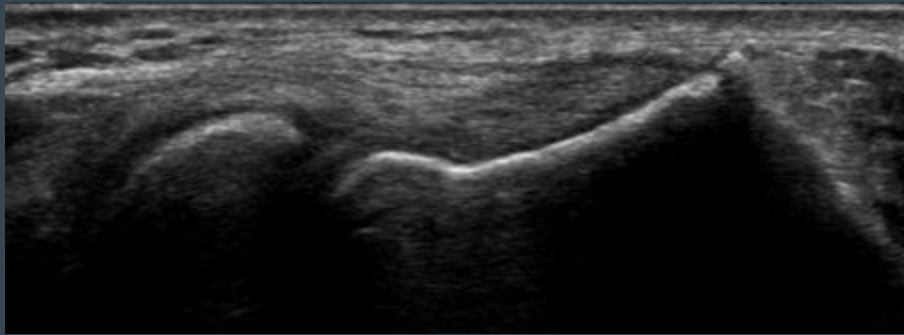

Combo Therapy –

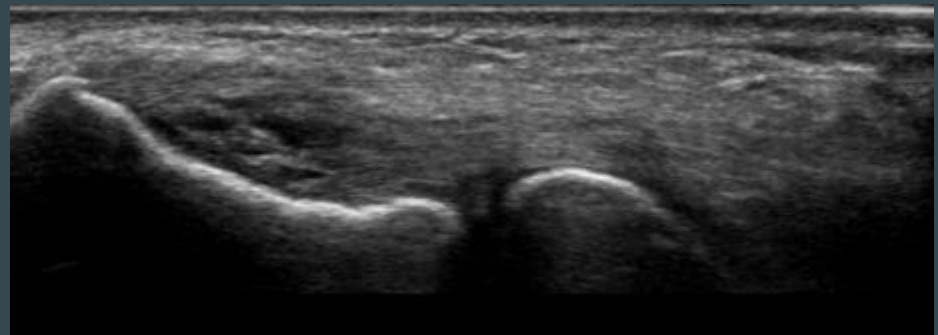


Diagnostic Ultrasound

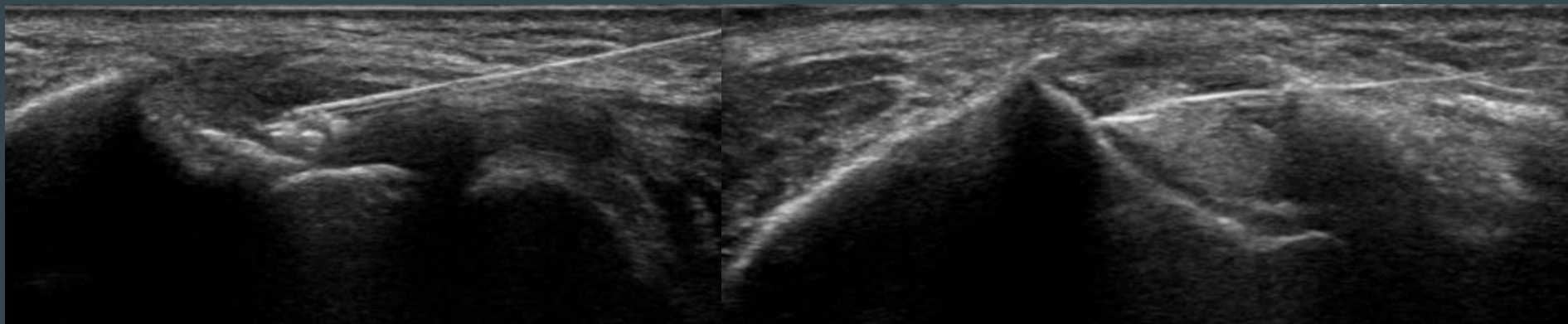
Left Side: Asymptomatic



Right Side: Symptomatic

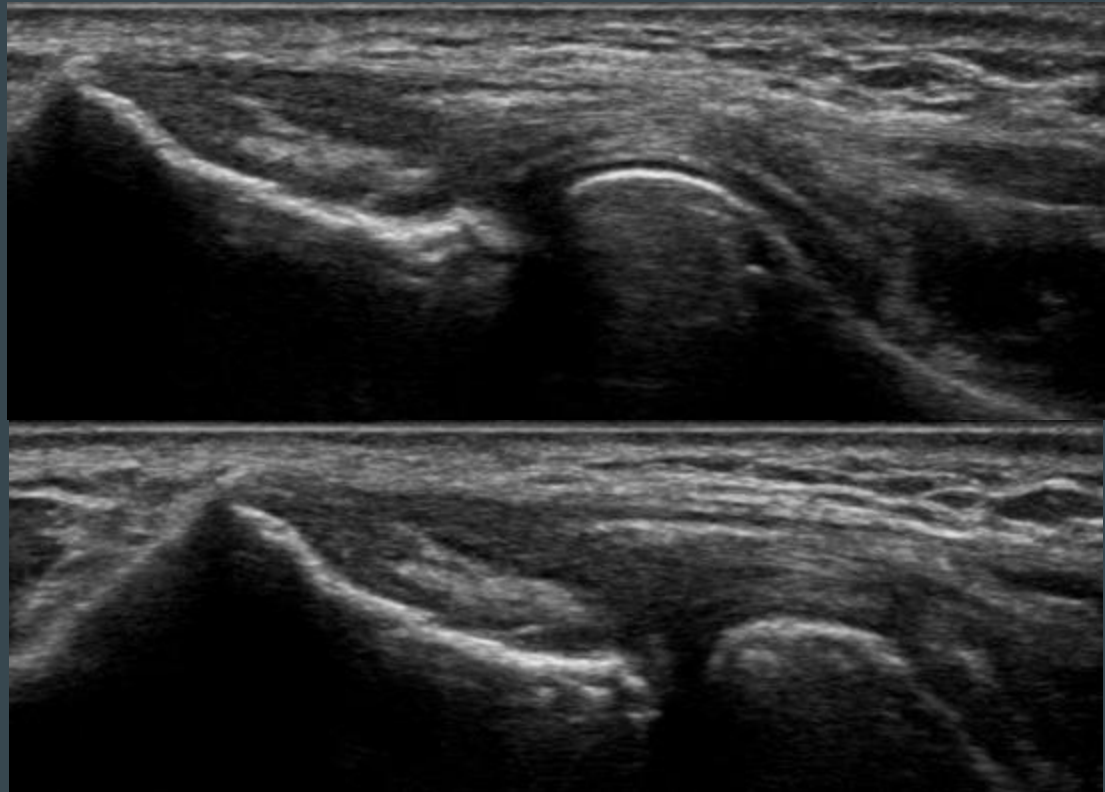


Intervention



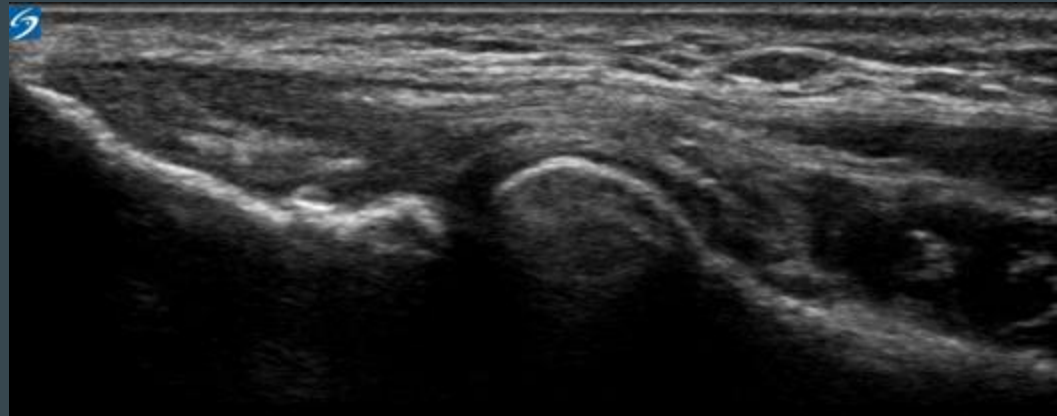
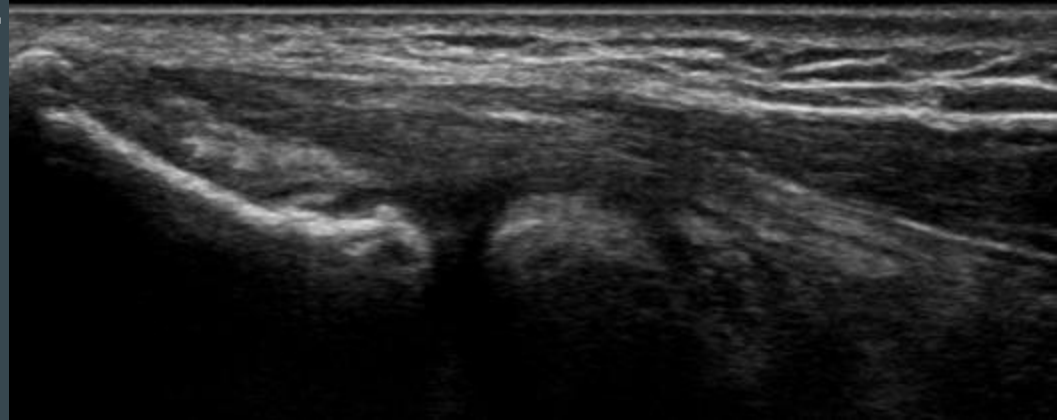
Follow up- 3 months post

- 0/10 pain score at visit
- At worse 3/10 pain with repetitive motions, overall less severe and less frequent
- 80% improvement
- Increased function
- Continuing PT and meeting all milestones, ready for discharge



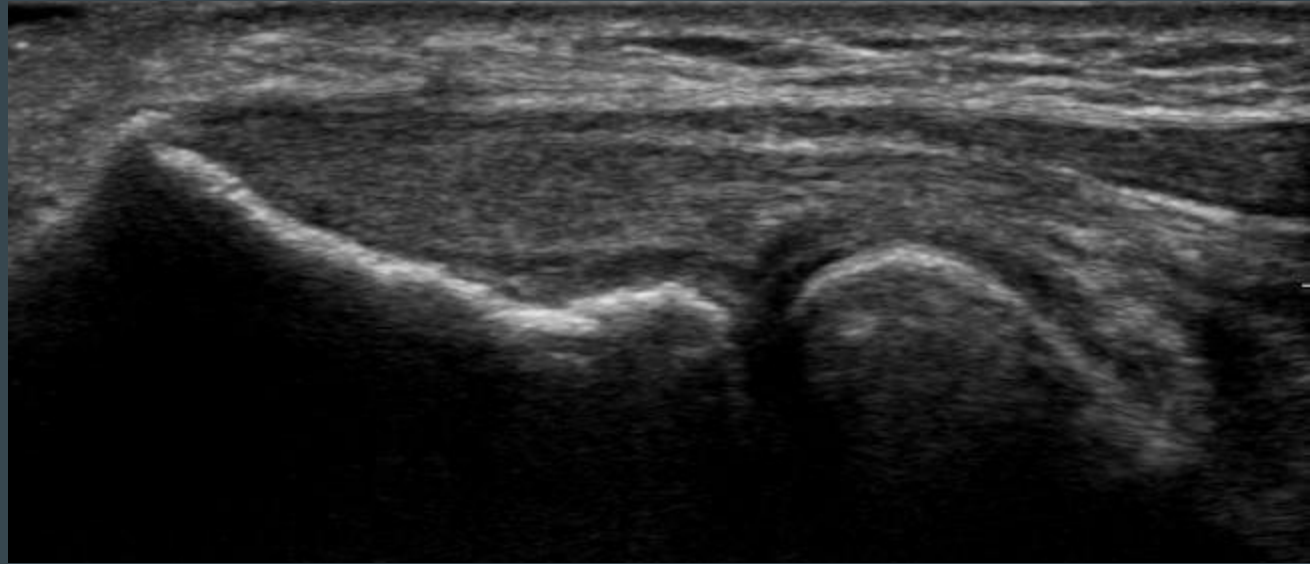
Follow up-4.5 months post

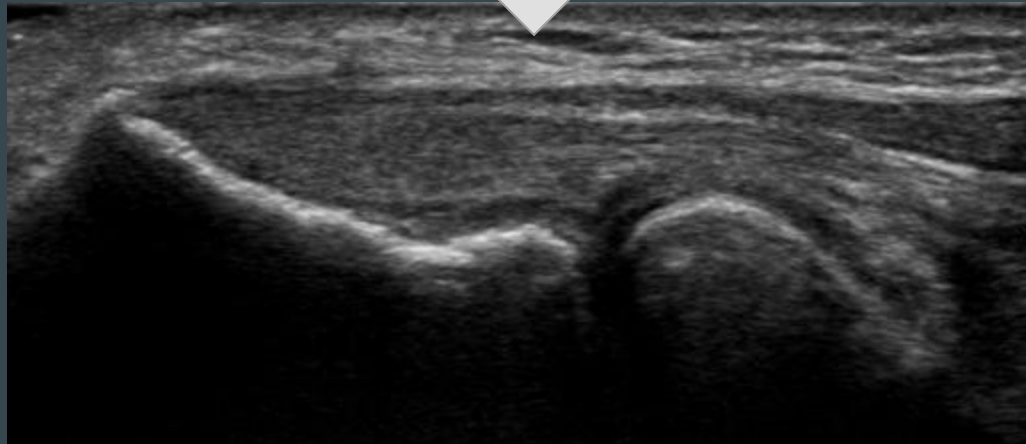
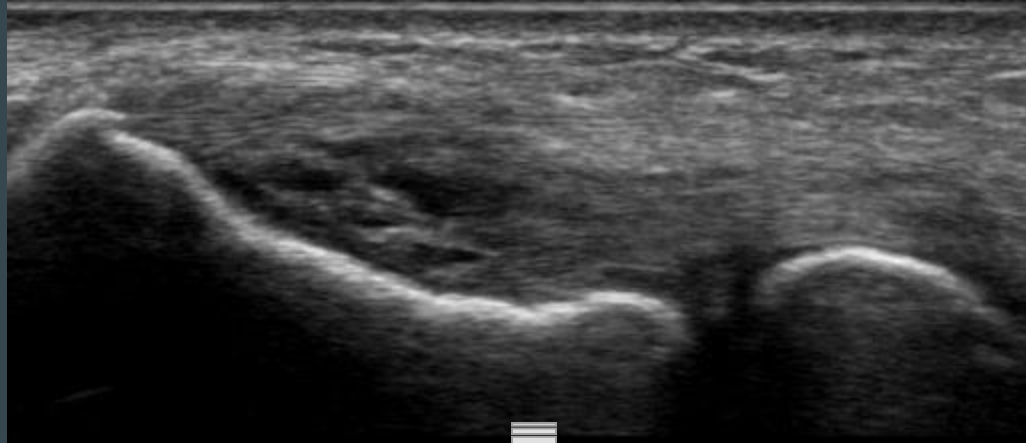
- Continued improvement
- 0/10 pain daily
- Very occasional pain with repetitive wrist extension movements



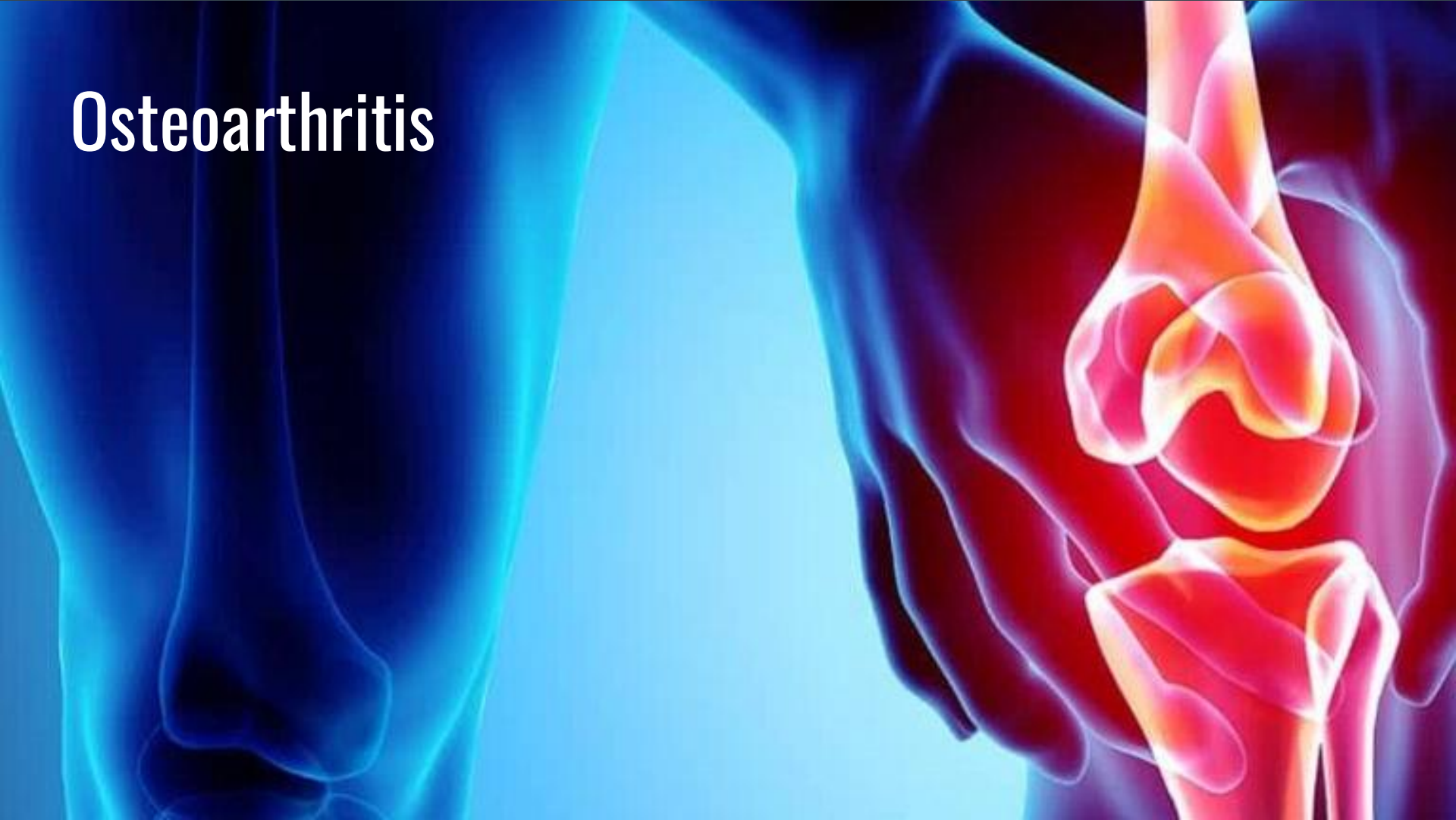Follow up-9 months post

- 95% improvement
- Continuing to improve
- No pain and no pain with activities



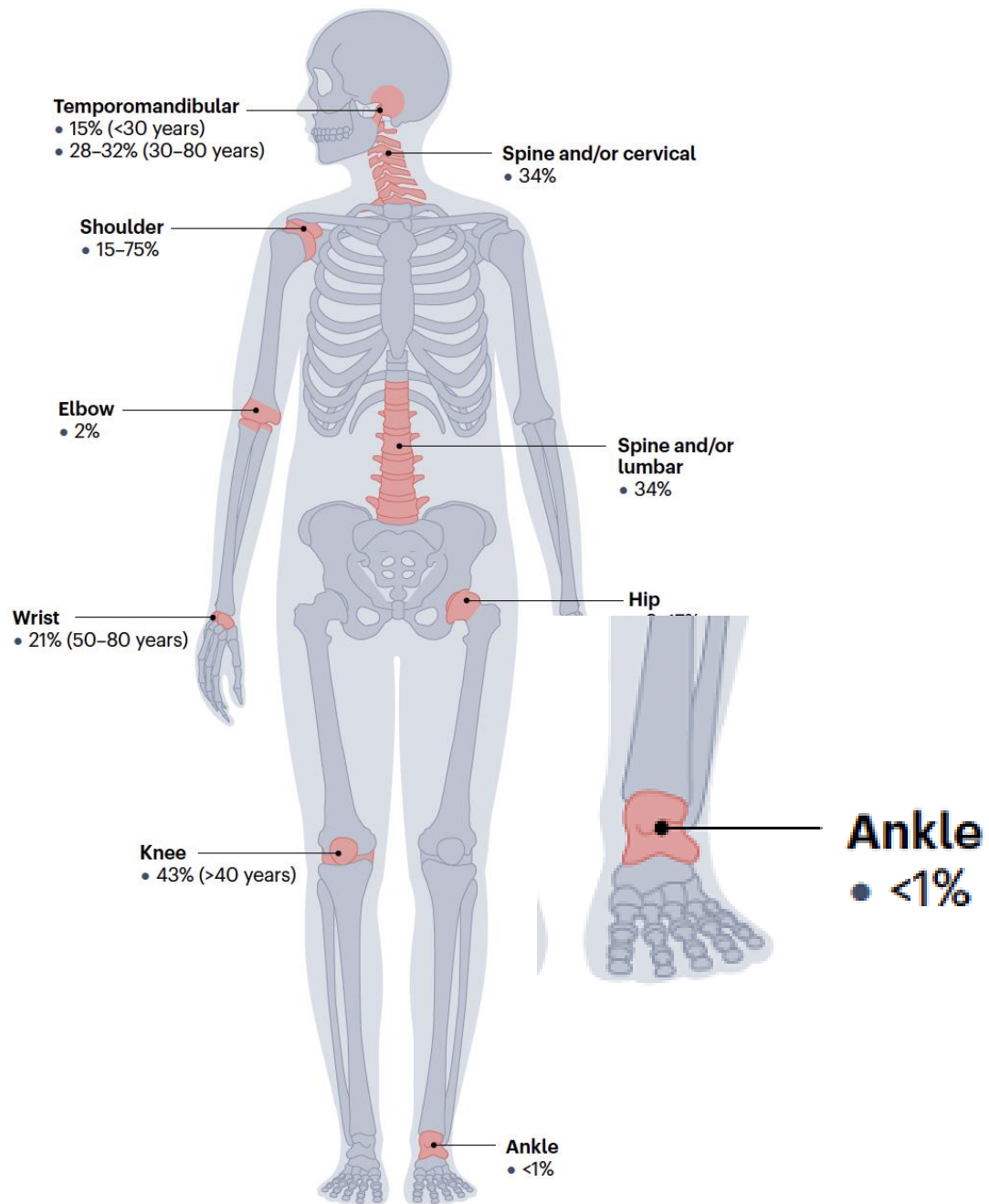


Osteoarthritis



45% of individuals may develop Symptomatic knee OA over their lifetime

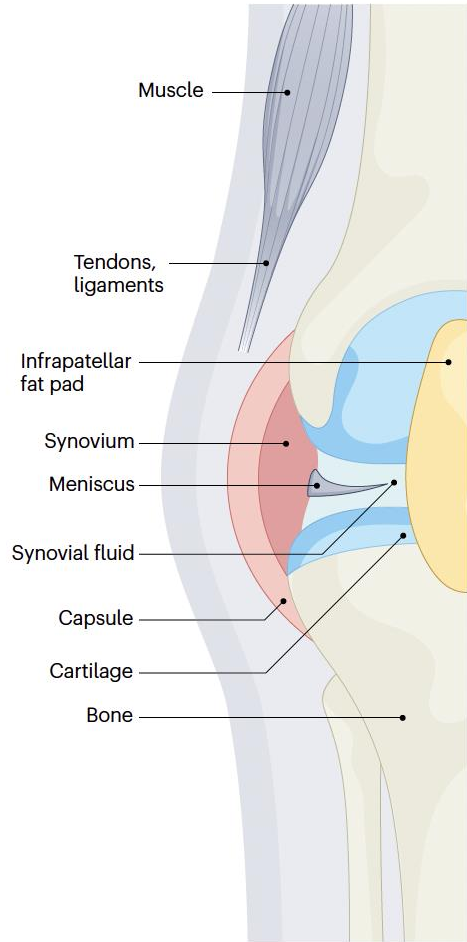
In 2020, 14.8% of the global population aged 30 years or older experienced some form of osteoarthritis



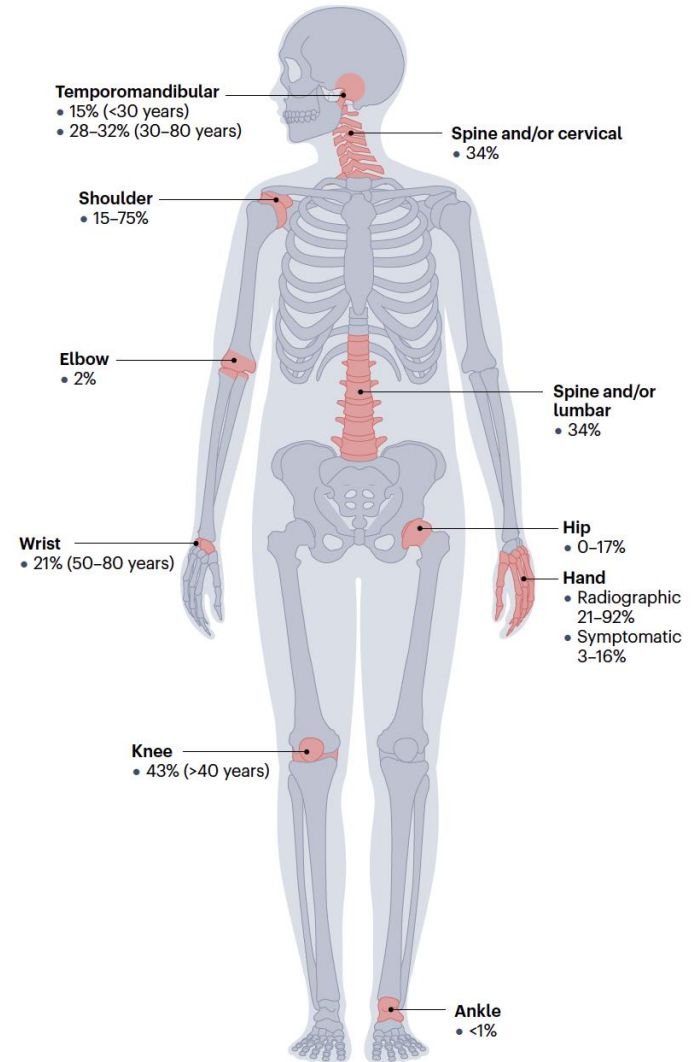
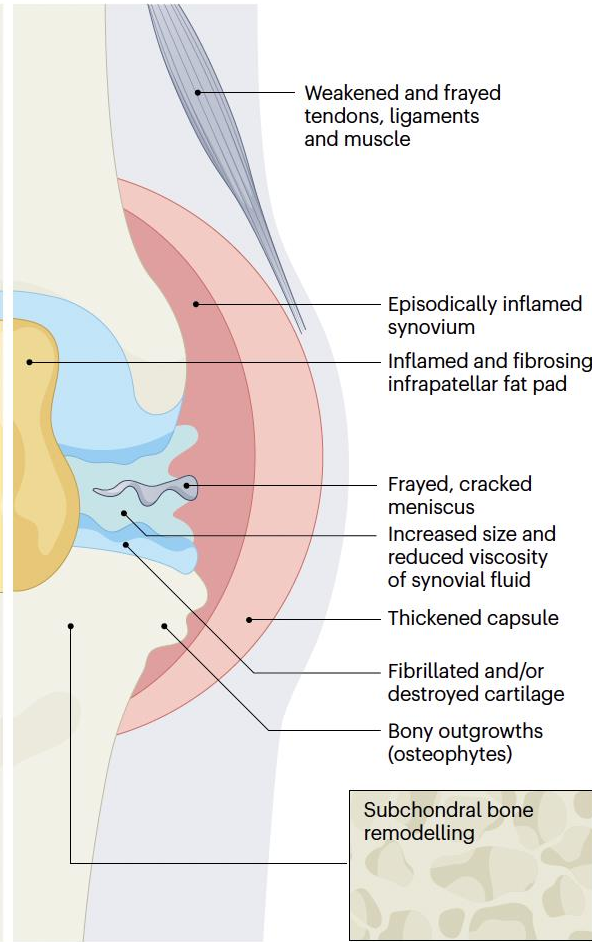
New Understanding of Osteoarthritis

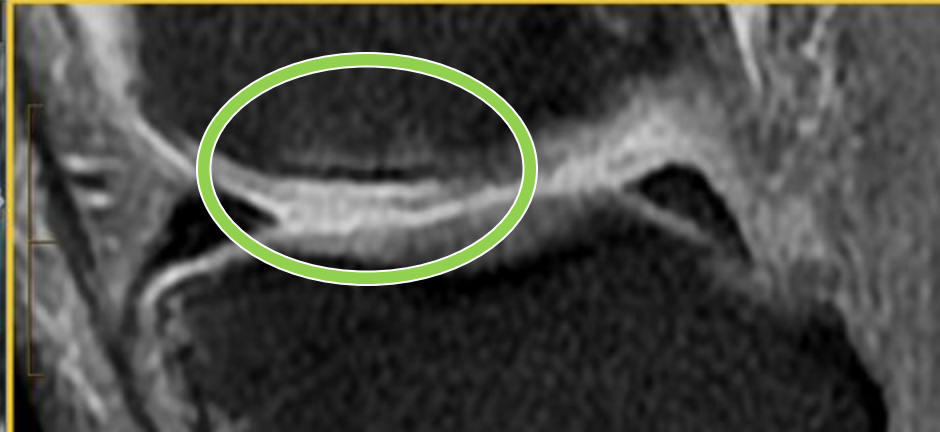
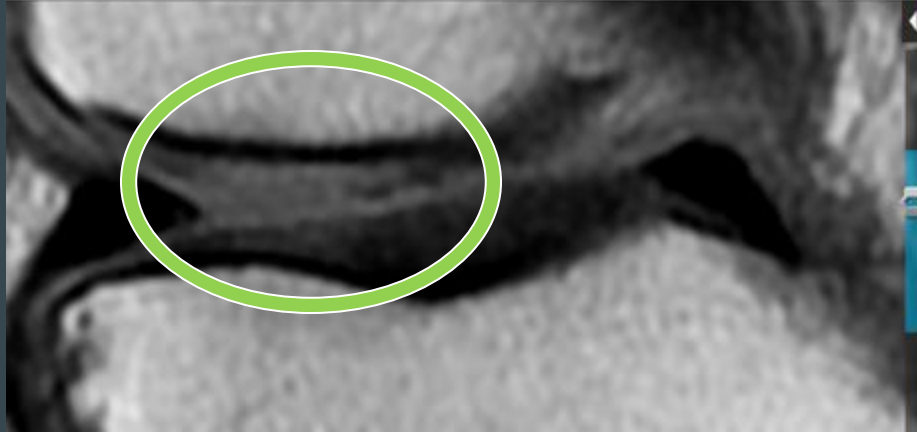
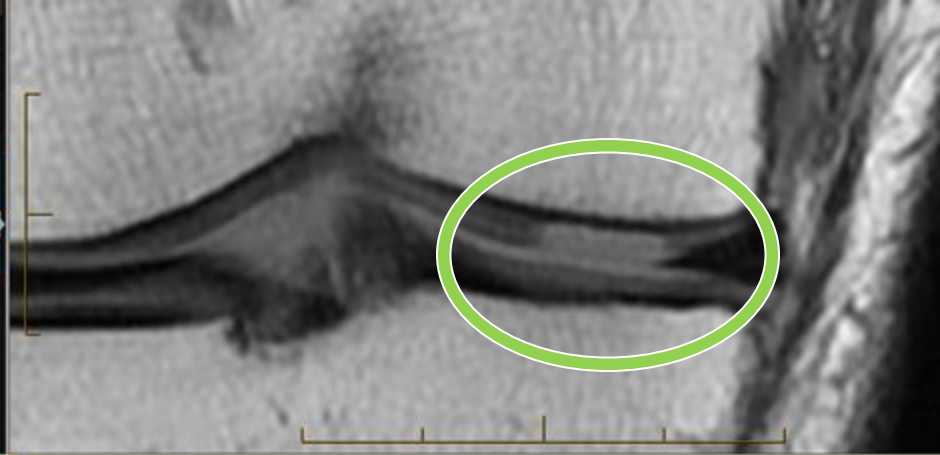
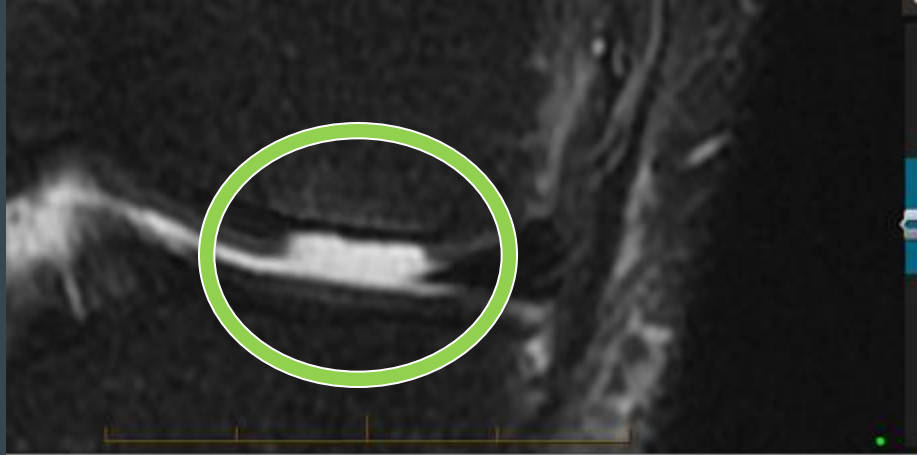
- *complex, multifactorial disorder affecting the entire joint, including the bone, cartilage, ligaments and muscles*
- *Osteoarthritis Research Society International (OARSI) defines OA as a disorder of movable joints marked by cell stress and extracellular matrix degradation*
- *critical need to address the illness of OA early in the disease course when symptoms are typically episodic by targeting the leading modifiable risk factors to mitigate its extensive impacts*

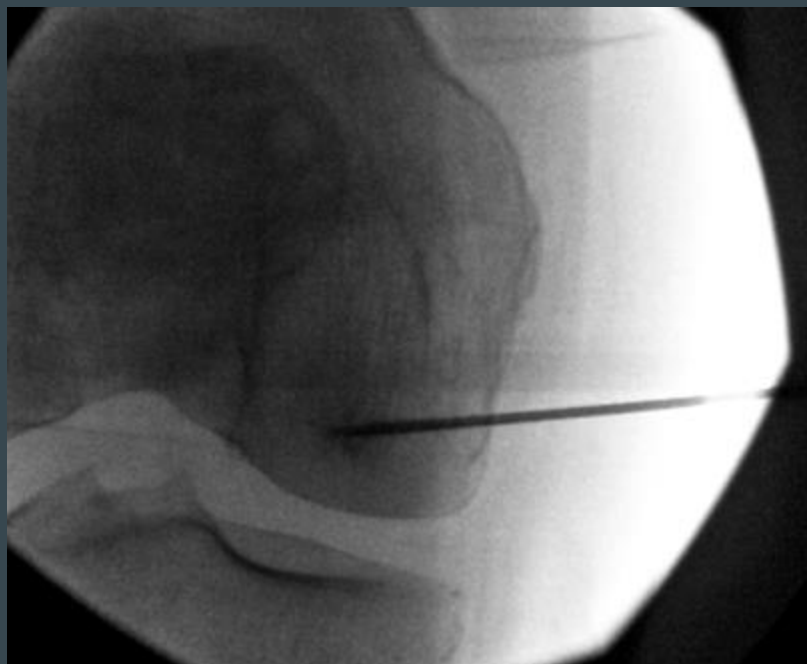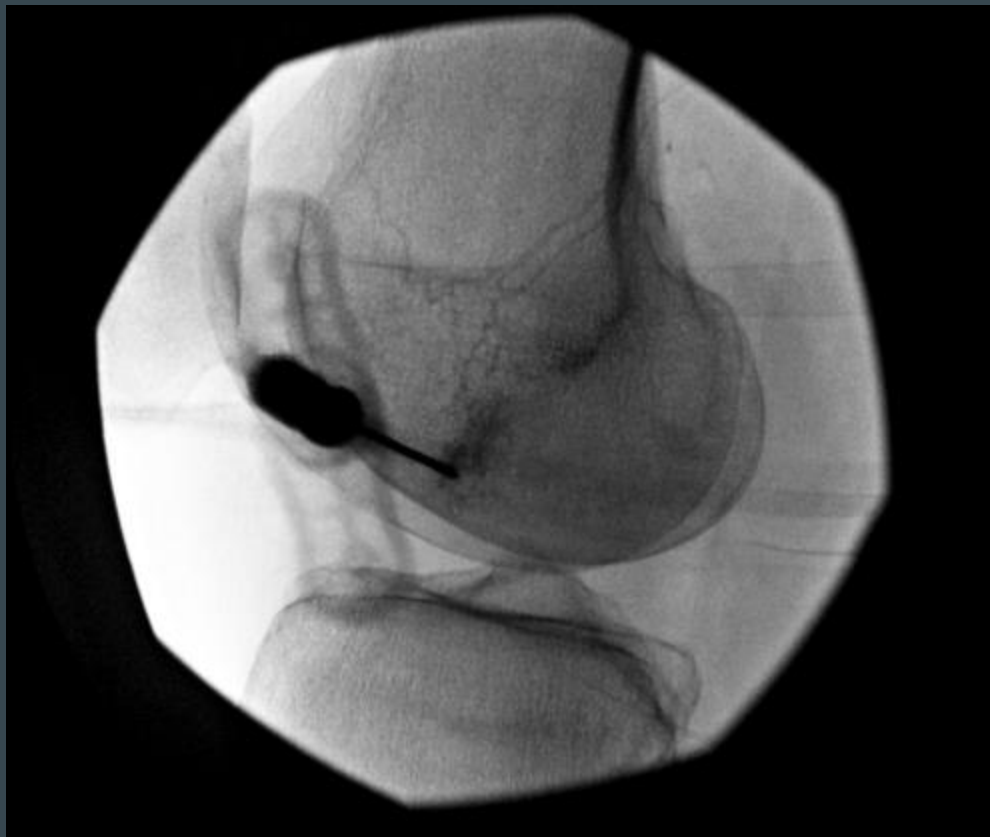a Healthy joint

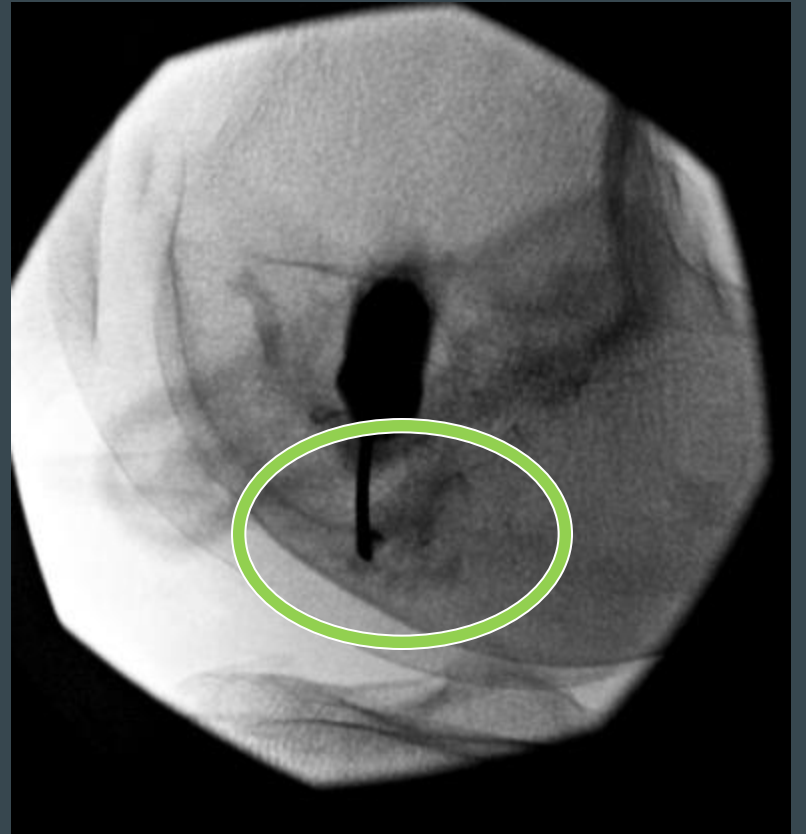
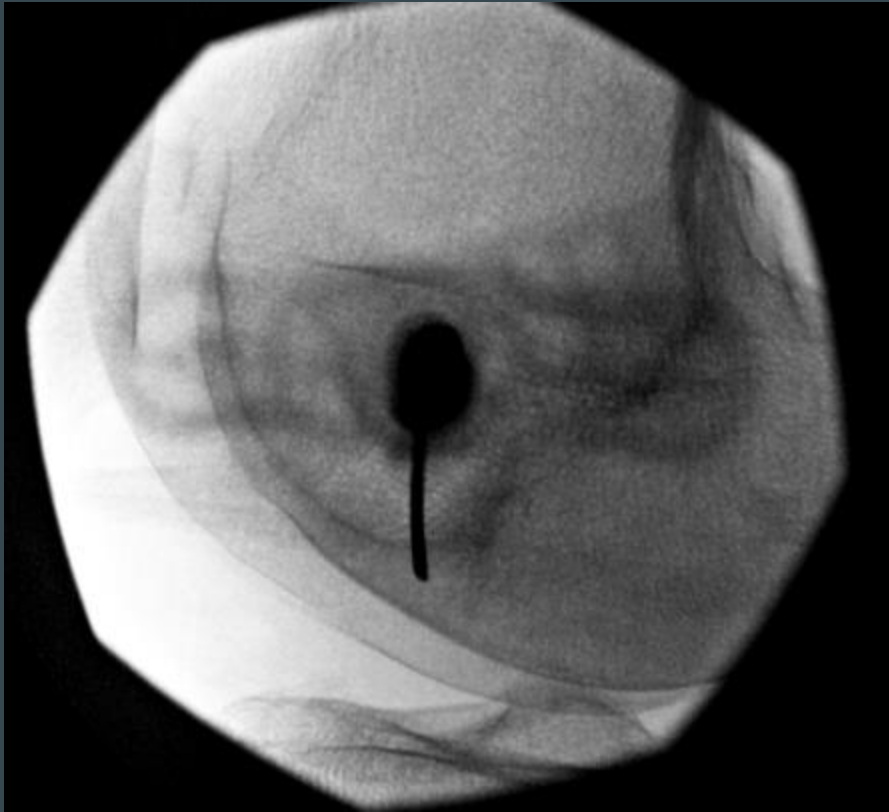
b Osteoarthritic joint

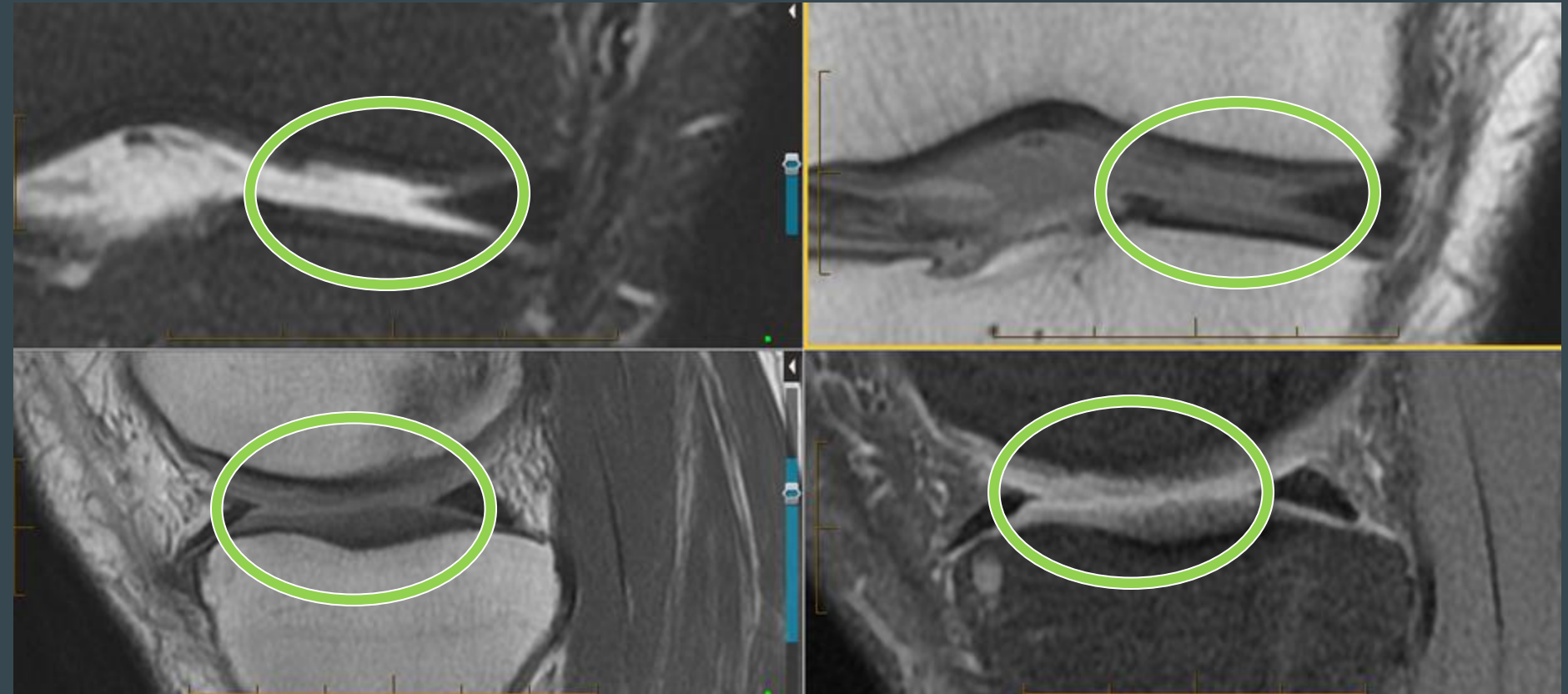


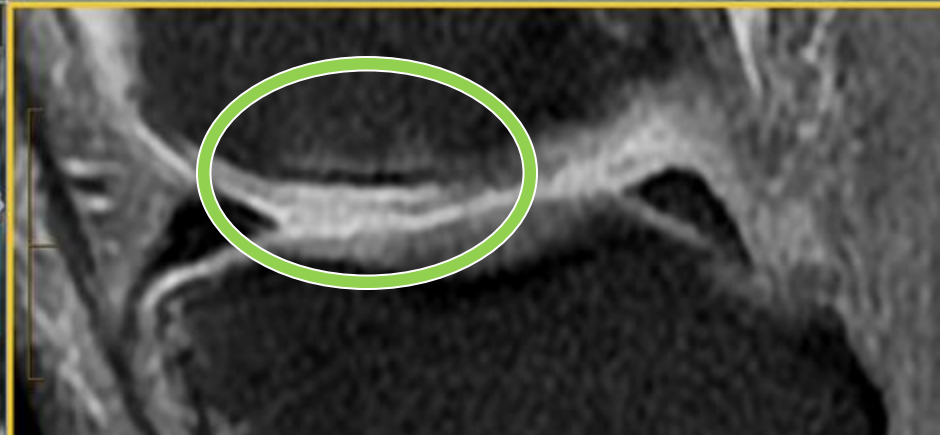
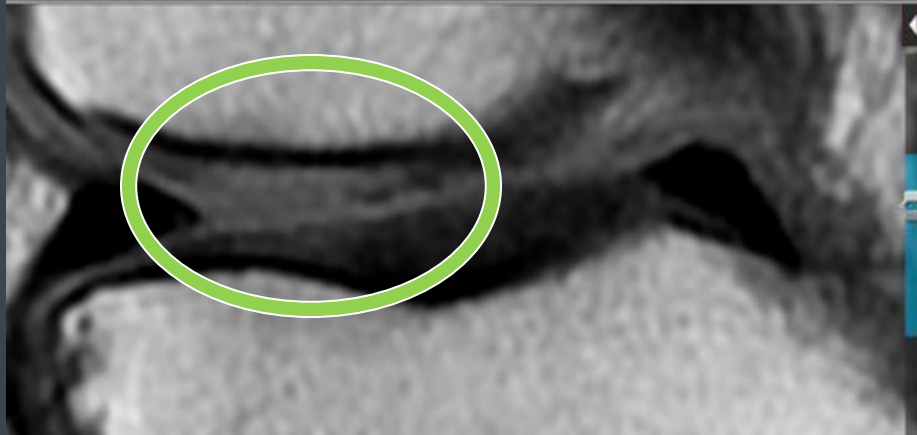
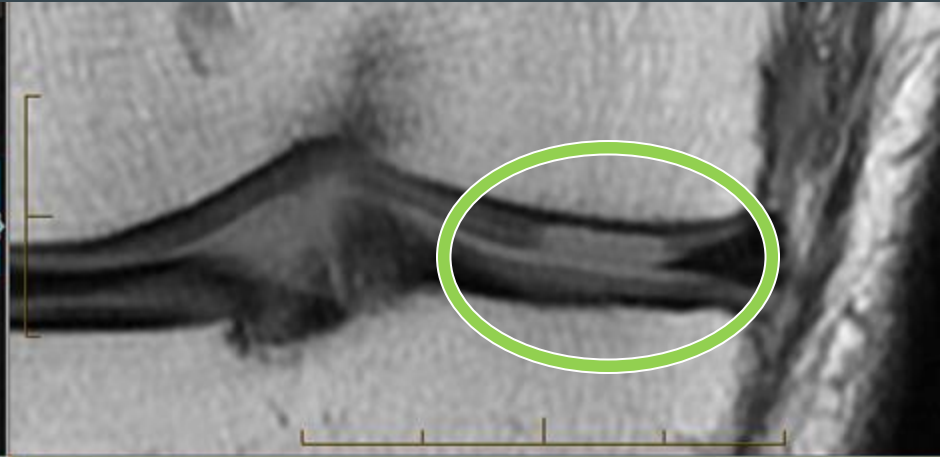
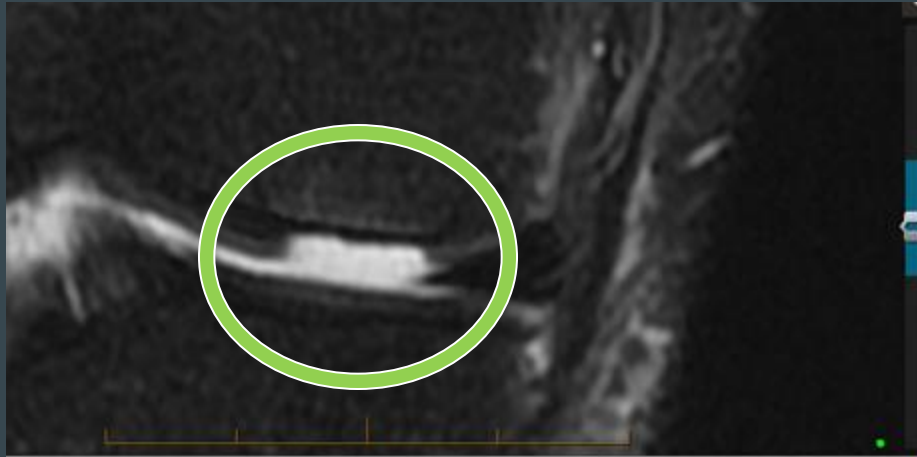


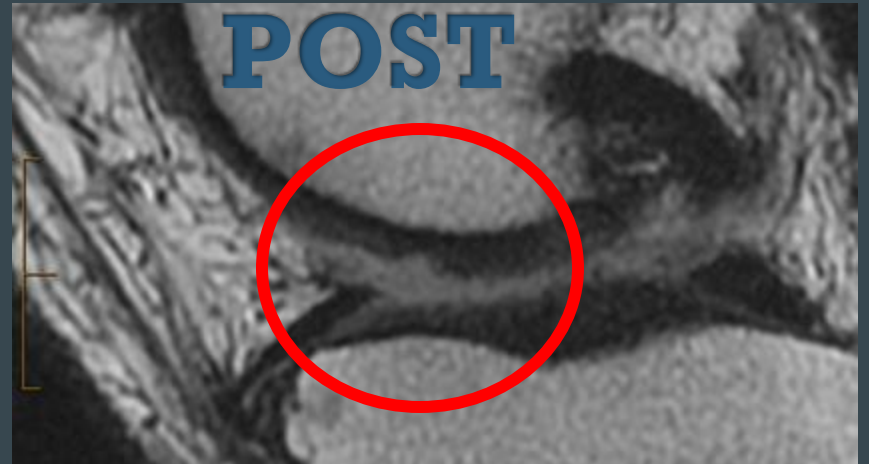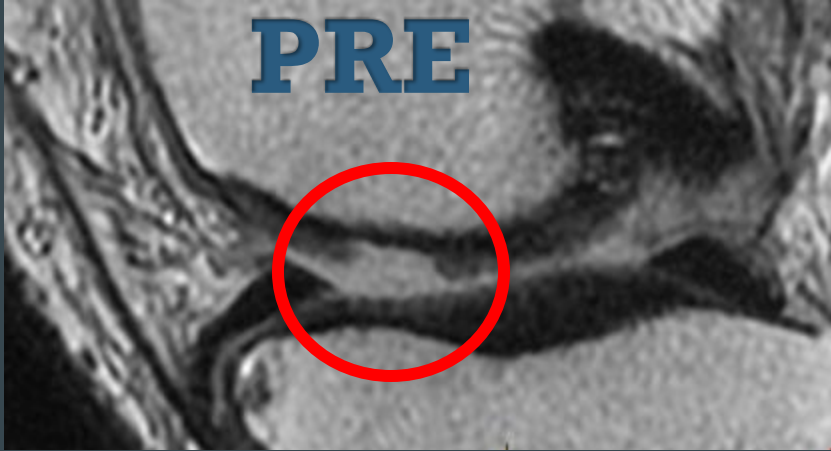


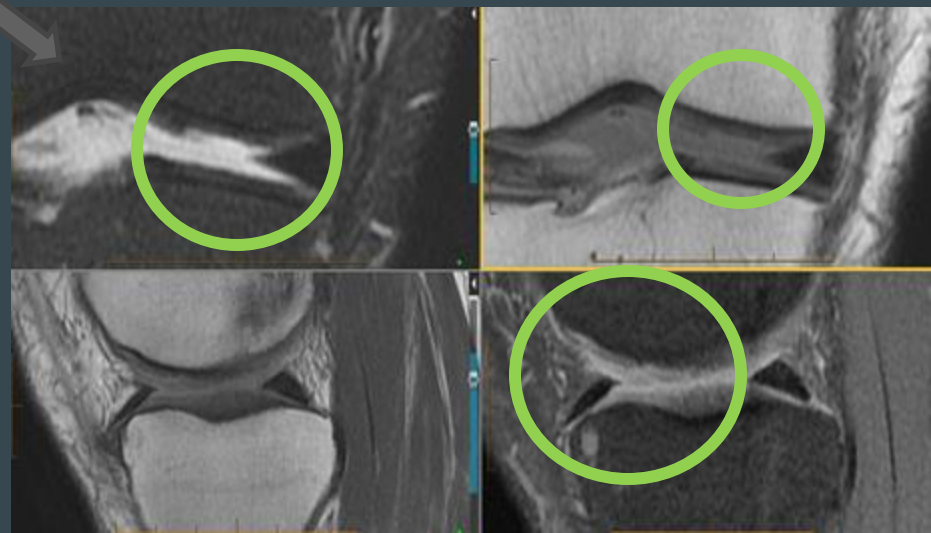
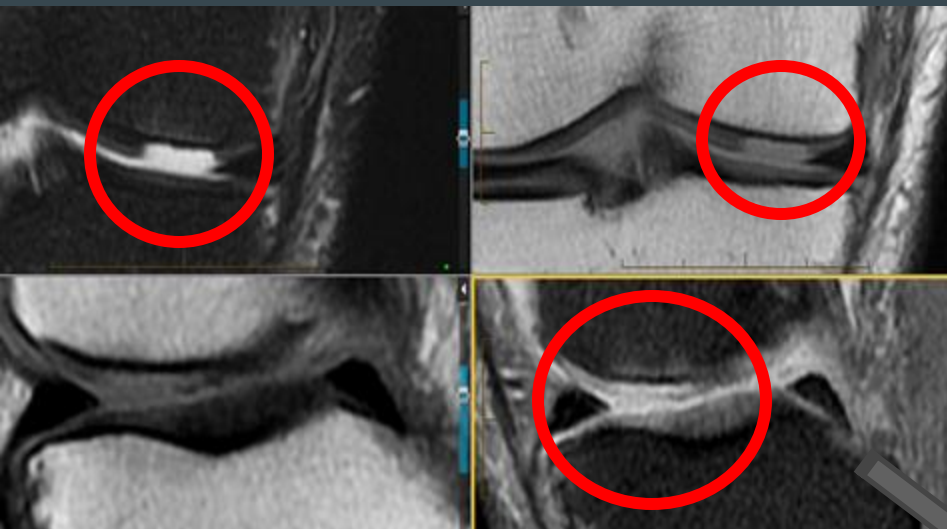


POST

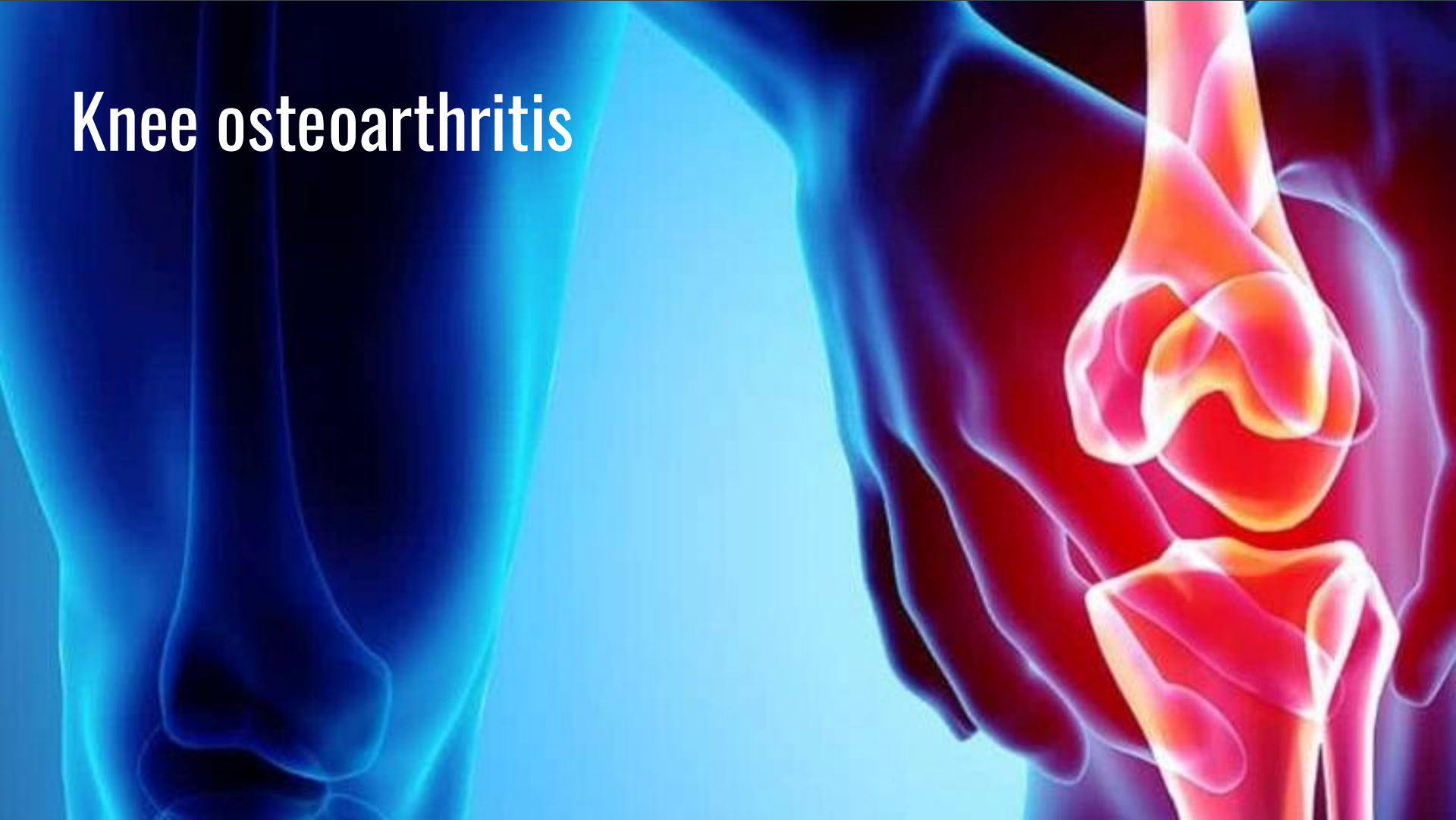



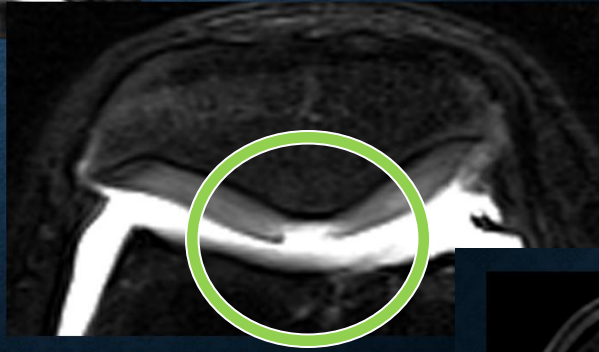
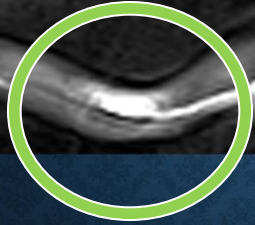




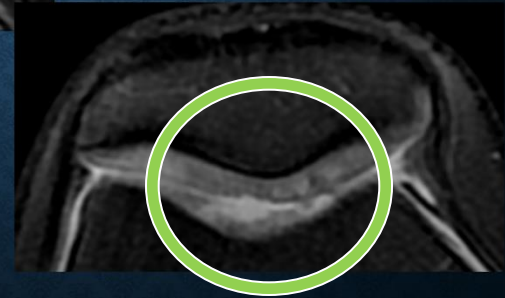
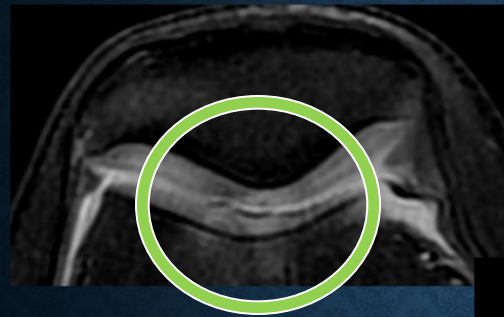
Knee osteoarthritis

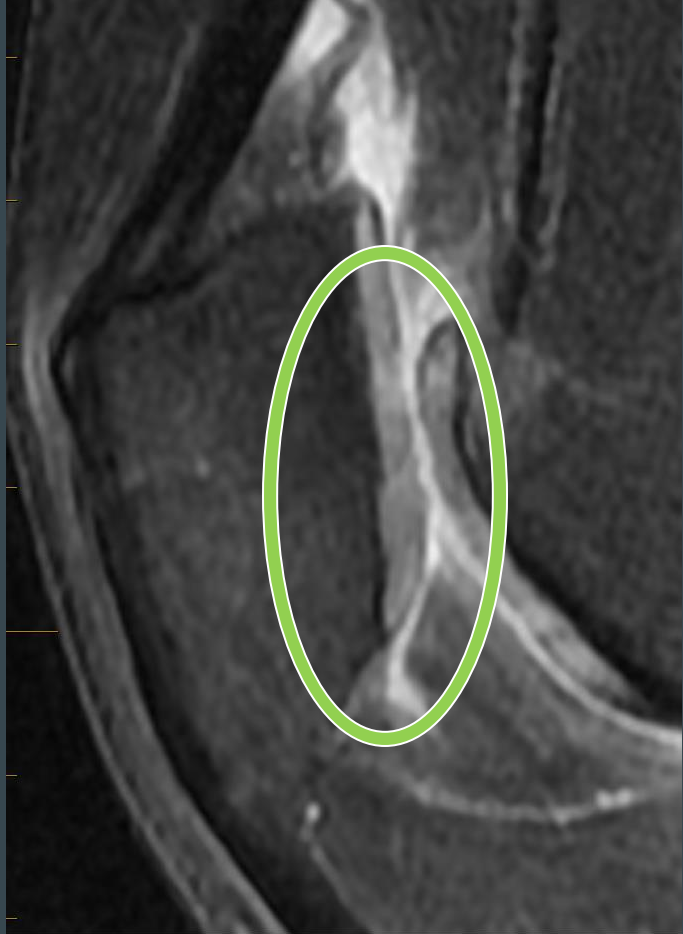
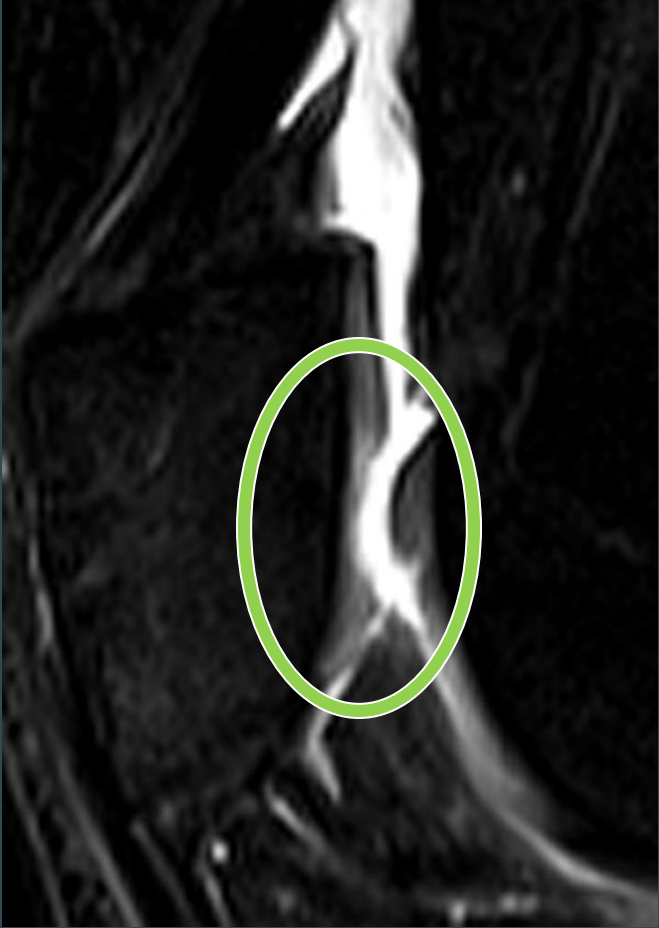
**35 YO F
PFC
MAY 2018**


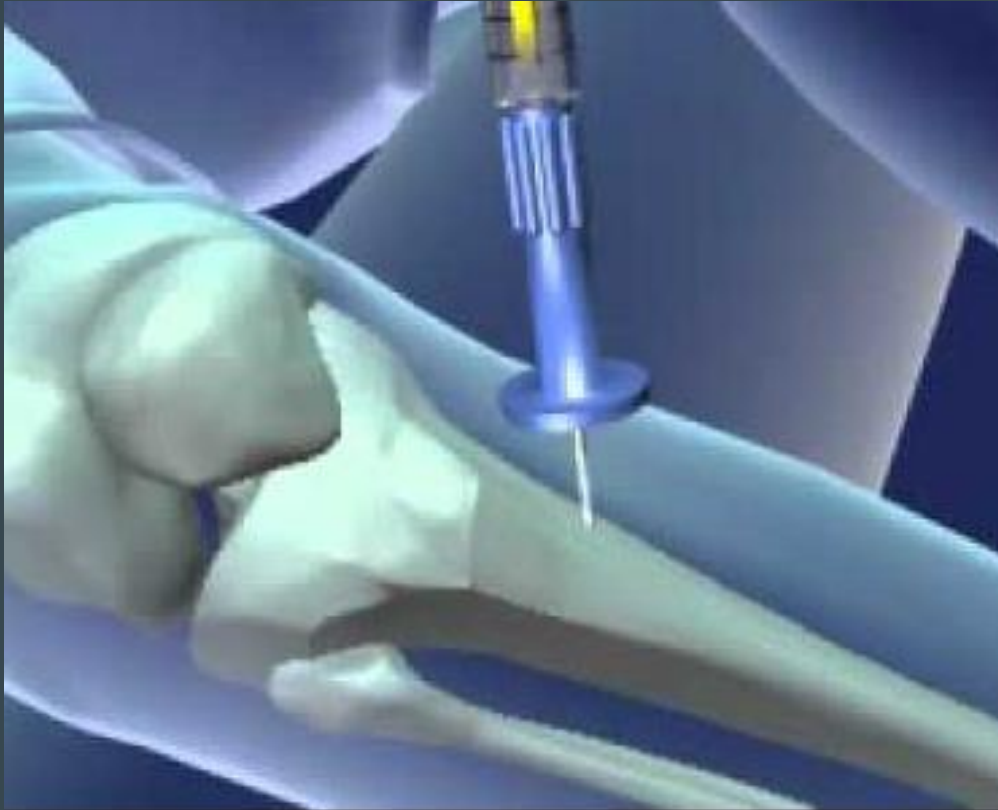


**APR 2022
4 YEARS POST BLP
CELL THERAPY
INJECTION**

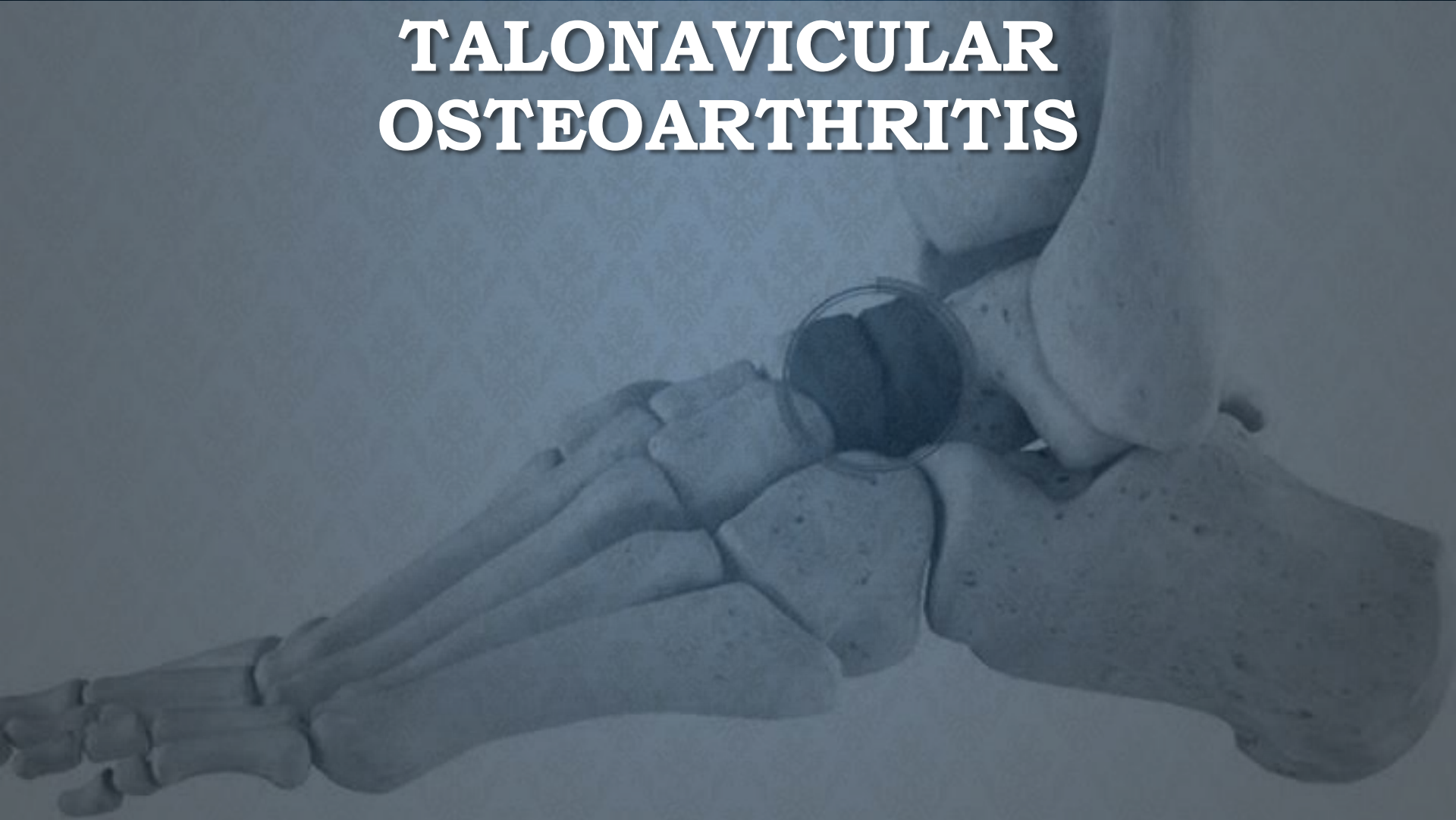


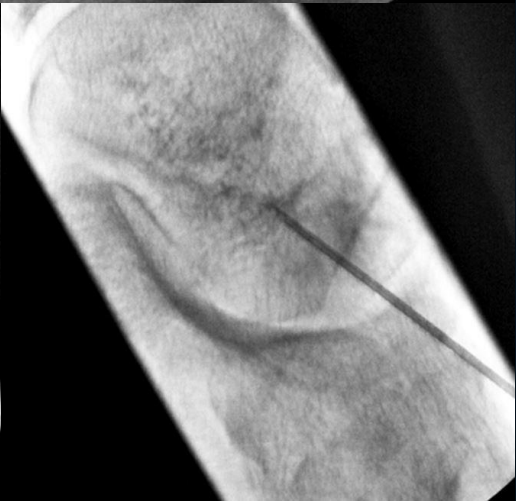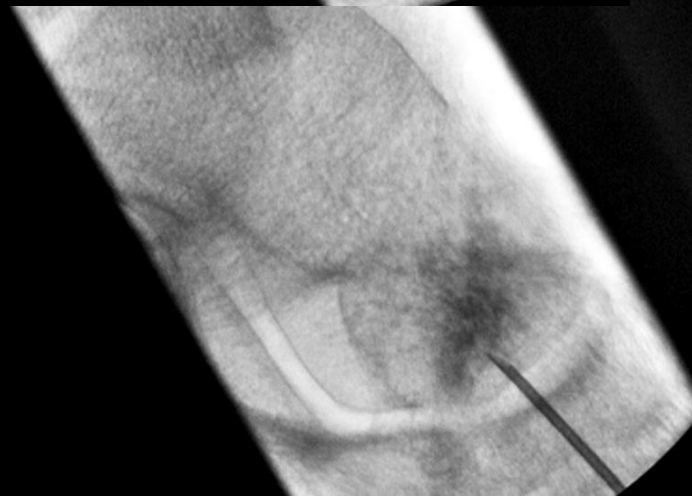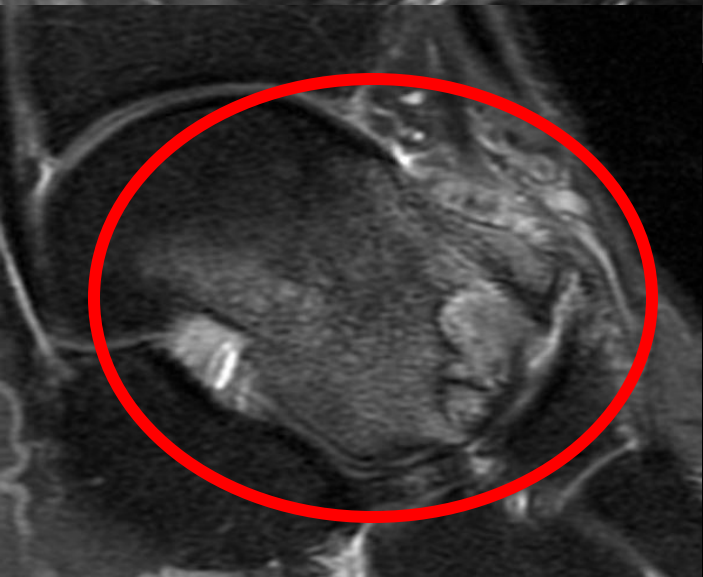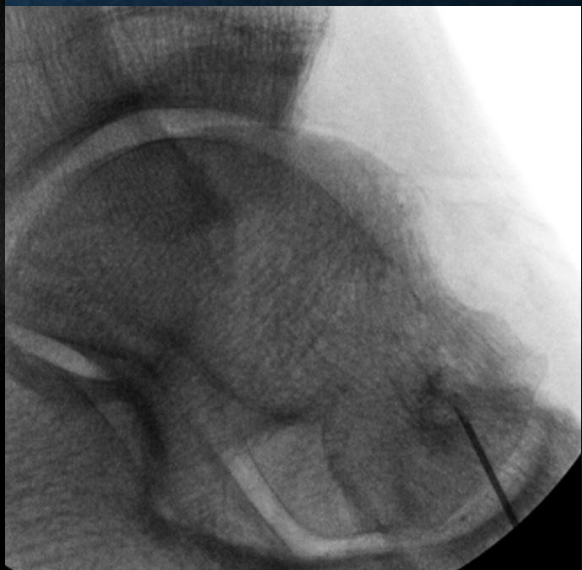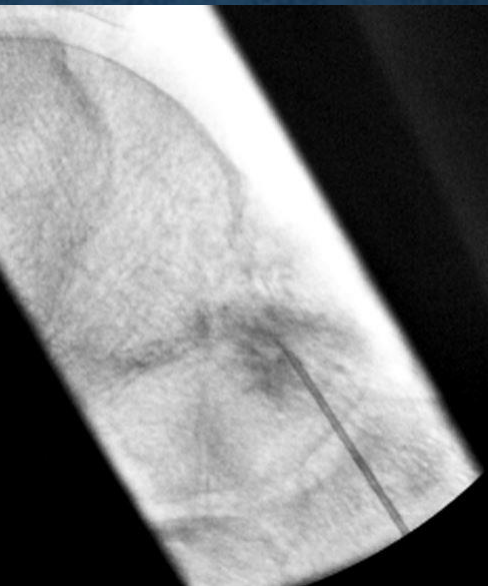


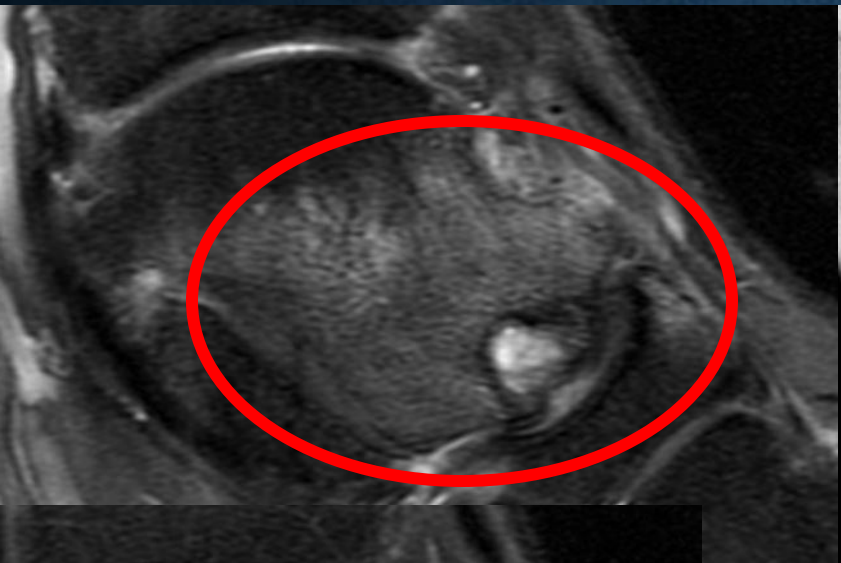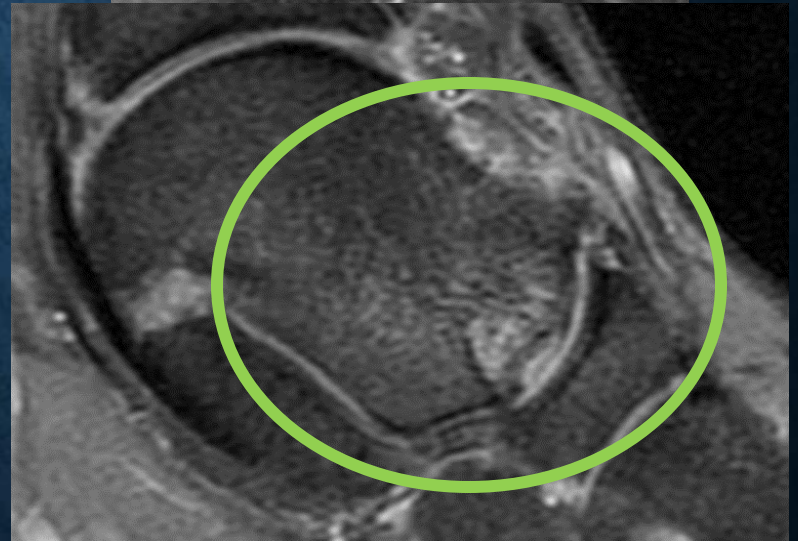
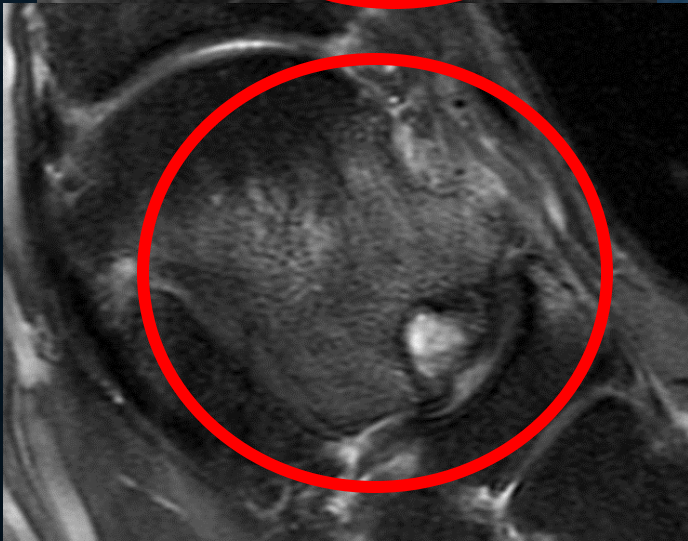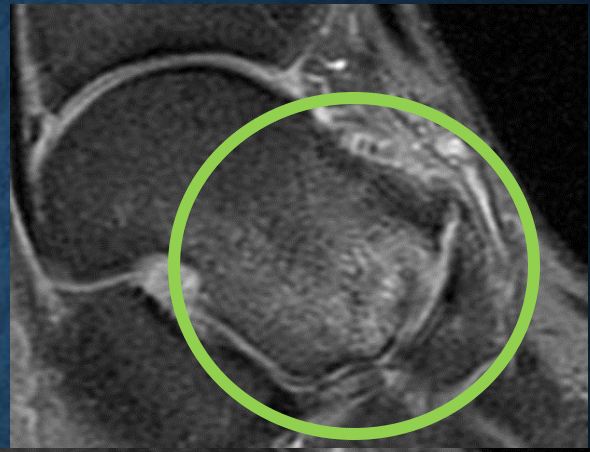
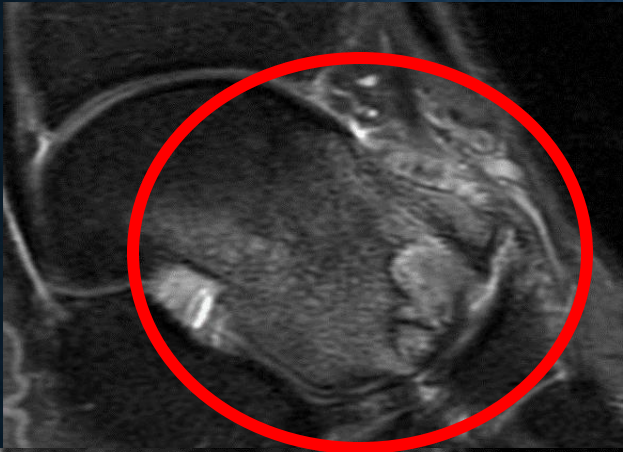Intra-Osseous Injections



TALONAVICULAR OSTEOARTHRITIS

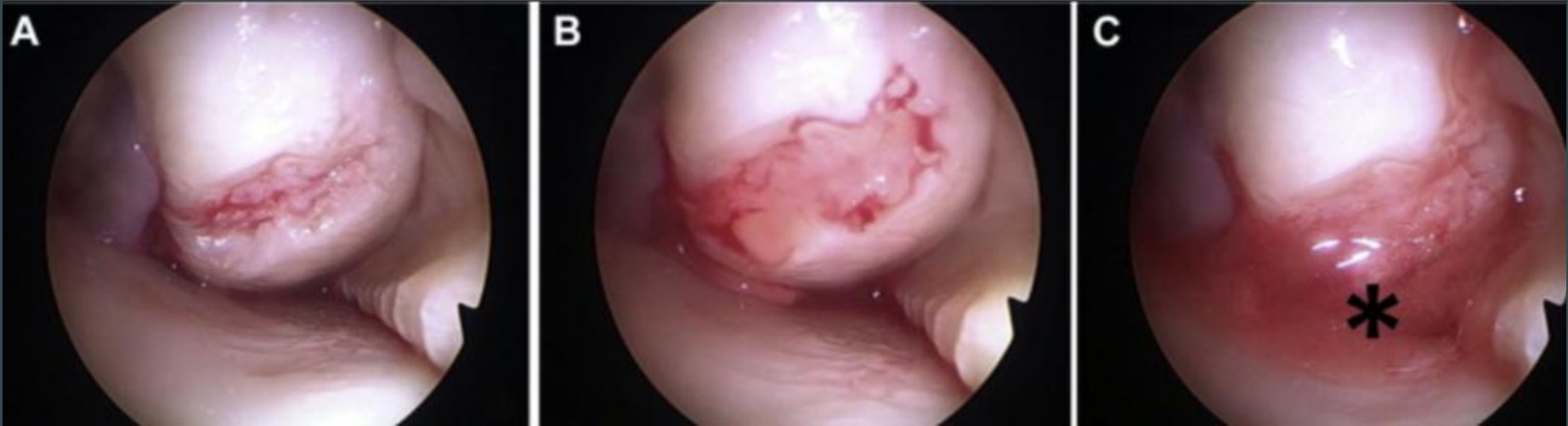







KNEE OSTEOARTHRITIS



> *Arthrosc Tech*. 2014 Dec 15;3(6):e713-7. doi: 10.1016/j.eats.2014.09.006. eCollection 2014 Dec.

Intraosseous infiltration of platelet-rich plasma for severe knee osteoarthritis

Mikel Sánchez ¹, Nicolás Fiz ², Jorge Guadilla ¹, Sabino Padilla ³, Eduardo Anitua ³, Pello Sánchez ⁴, Diego Delgado ⁴

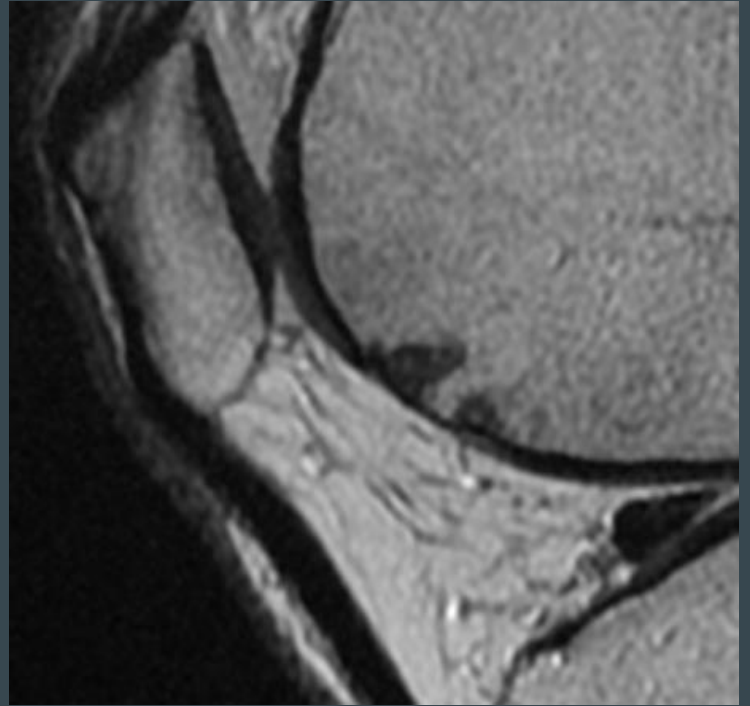
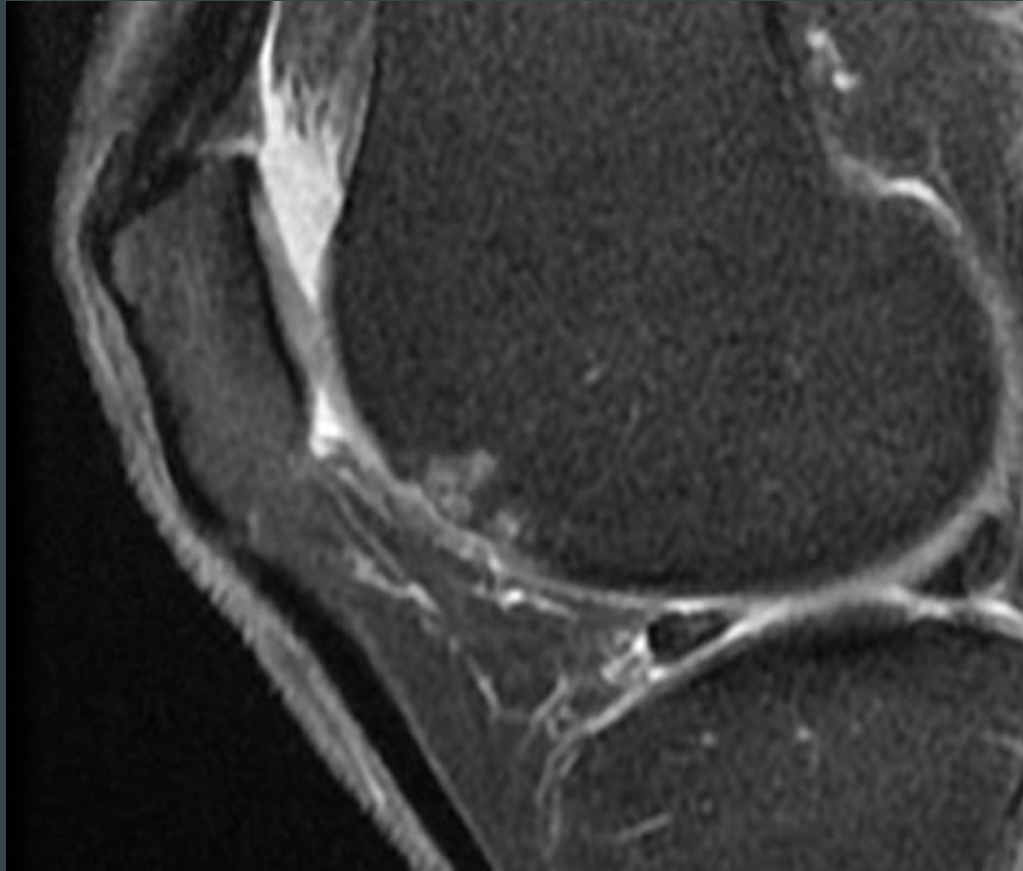
Affiliations + expand

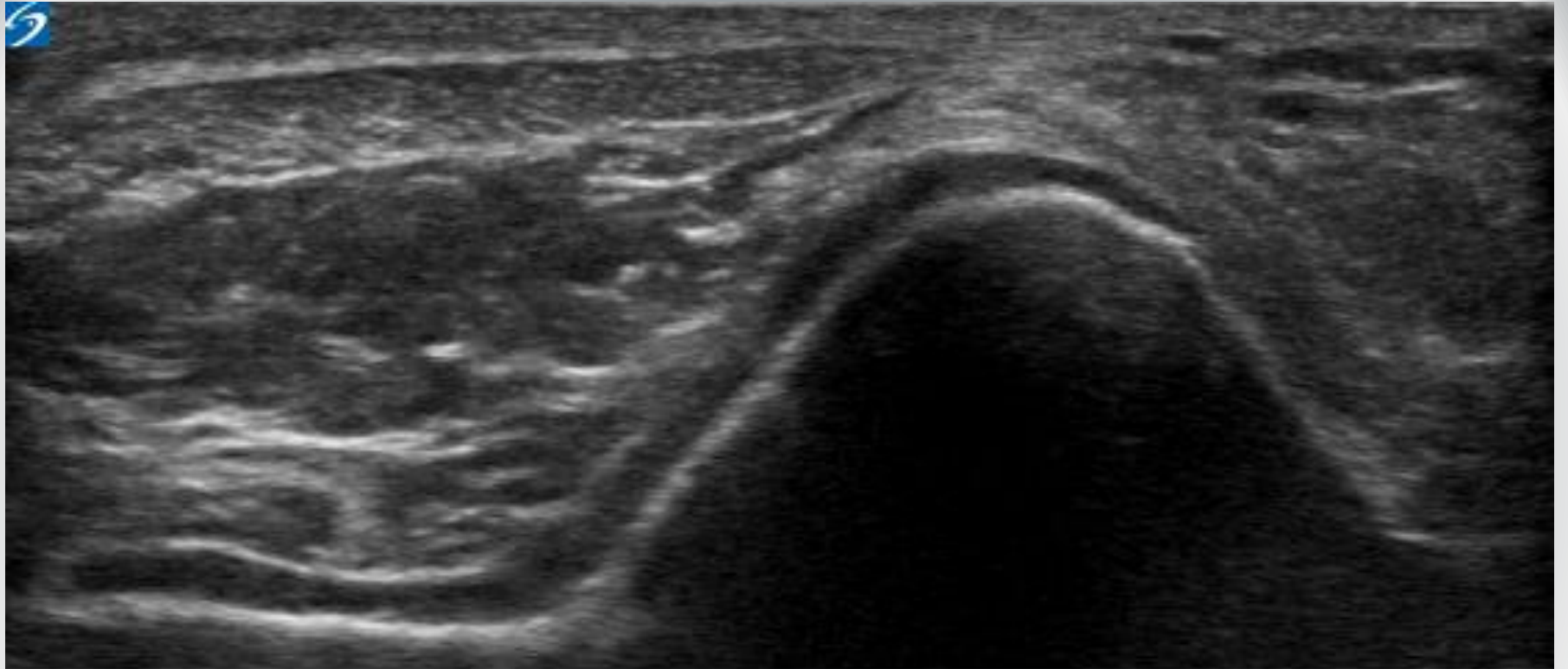
PMID: 25685680 PMCID: PMC4314556 DOI: 10.1016/j.eats.2014.09.006

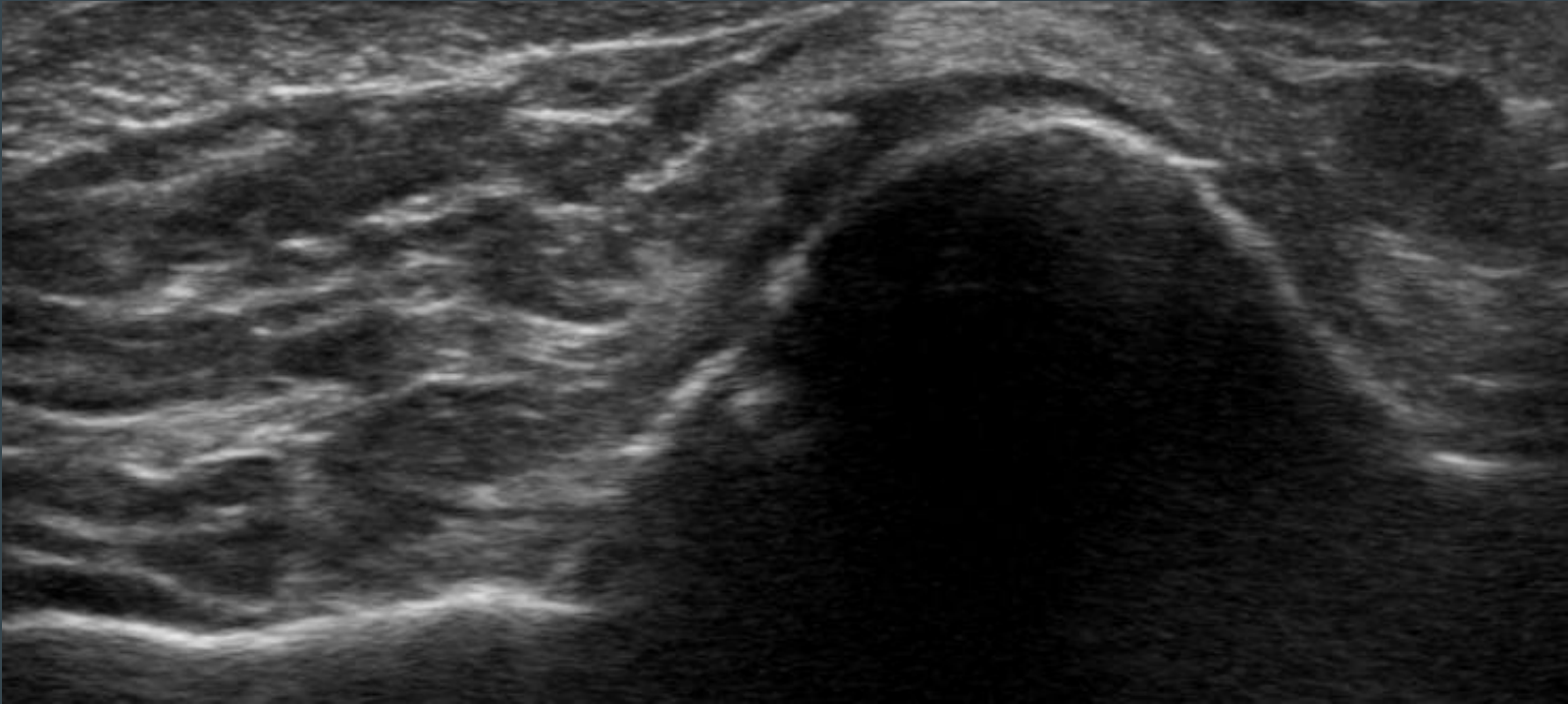
Abstract

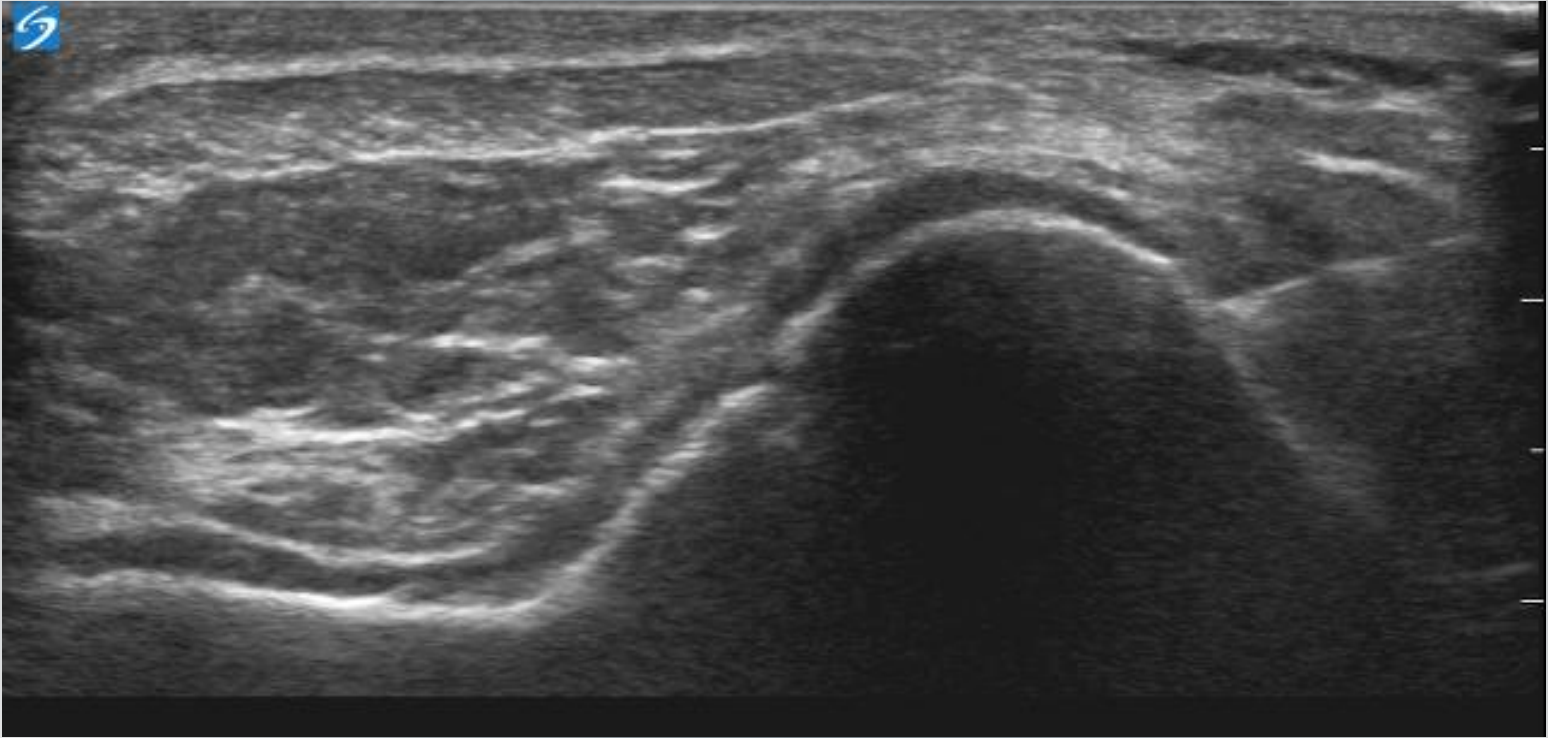
We describe a new technique of platelet-rich plasma (PRP) infiltration for the treatment of severe knee osteoarthritis. PRP intra-articular infiltration is a promising treatment for knee osteoarthritis, but it still has some limitations in high-degree osteoarthritis. Diagnosis of osteoarthritis is based on clinical and radiographic findings, and patients with grade III or IV knee tibiofemoral osteoarthritis based on the Ahlbäck scale are considered candidates for this technique. The technique consists of performing intraosseous infiltration of PRP into the subchondral bone, which acts on this tissue and consequently on cartilage-bone communication. Although the intraosseous injection hinders the conventional knee intra-articular infiltration, it allows an extension of the range of action of the PRP, which acts directly on the subchondral bone, which is involved in the progression of osteoarthritis. Thus this technique involves a new administration of PRP that can delay knee arthroplasty; moreover, it can be applied for not only severe osteoarthritis but also other pathologies in which the subchondral bone is critical in the etiology, such as necrosis and osteochondral lesions.

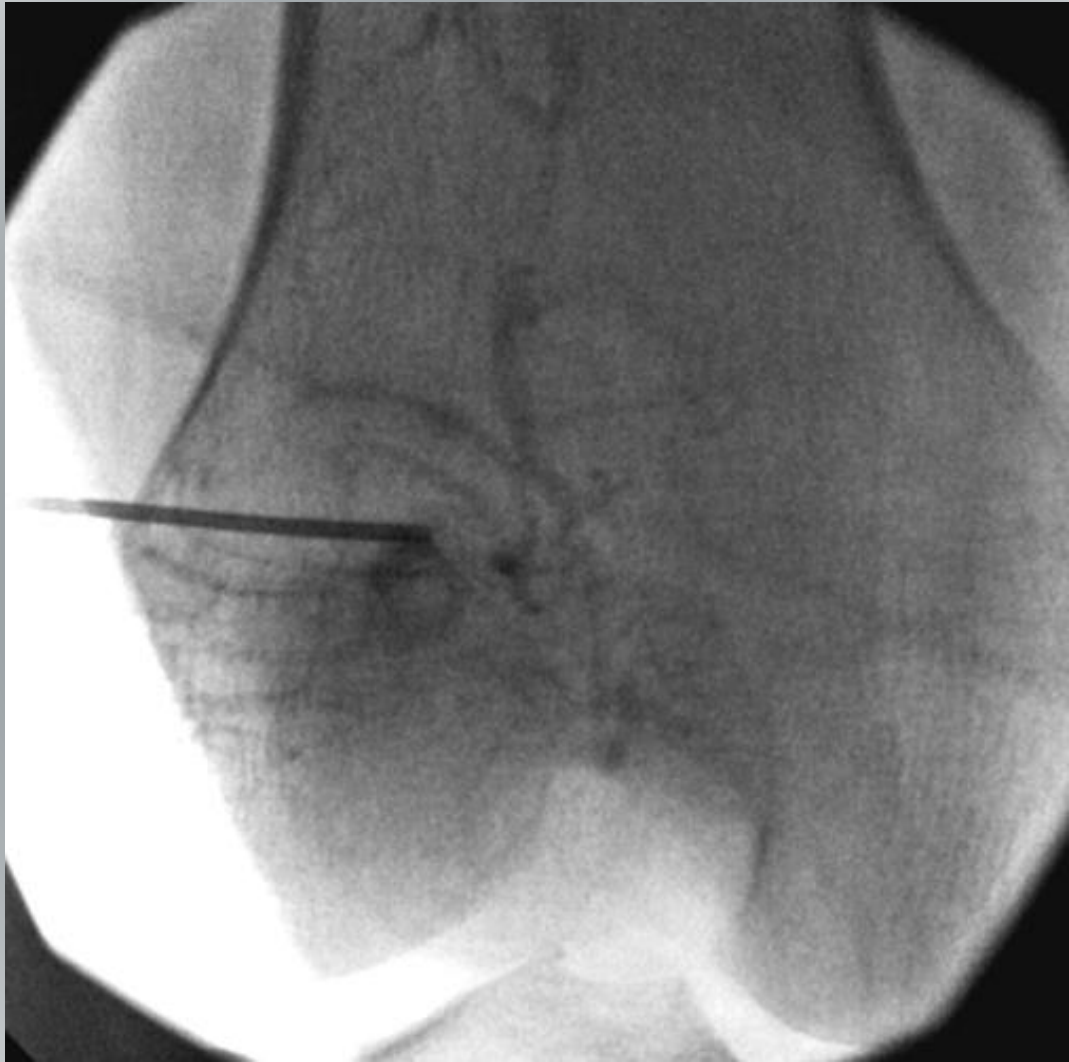PubMed Disclaimer

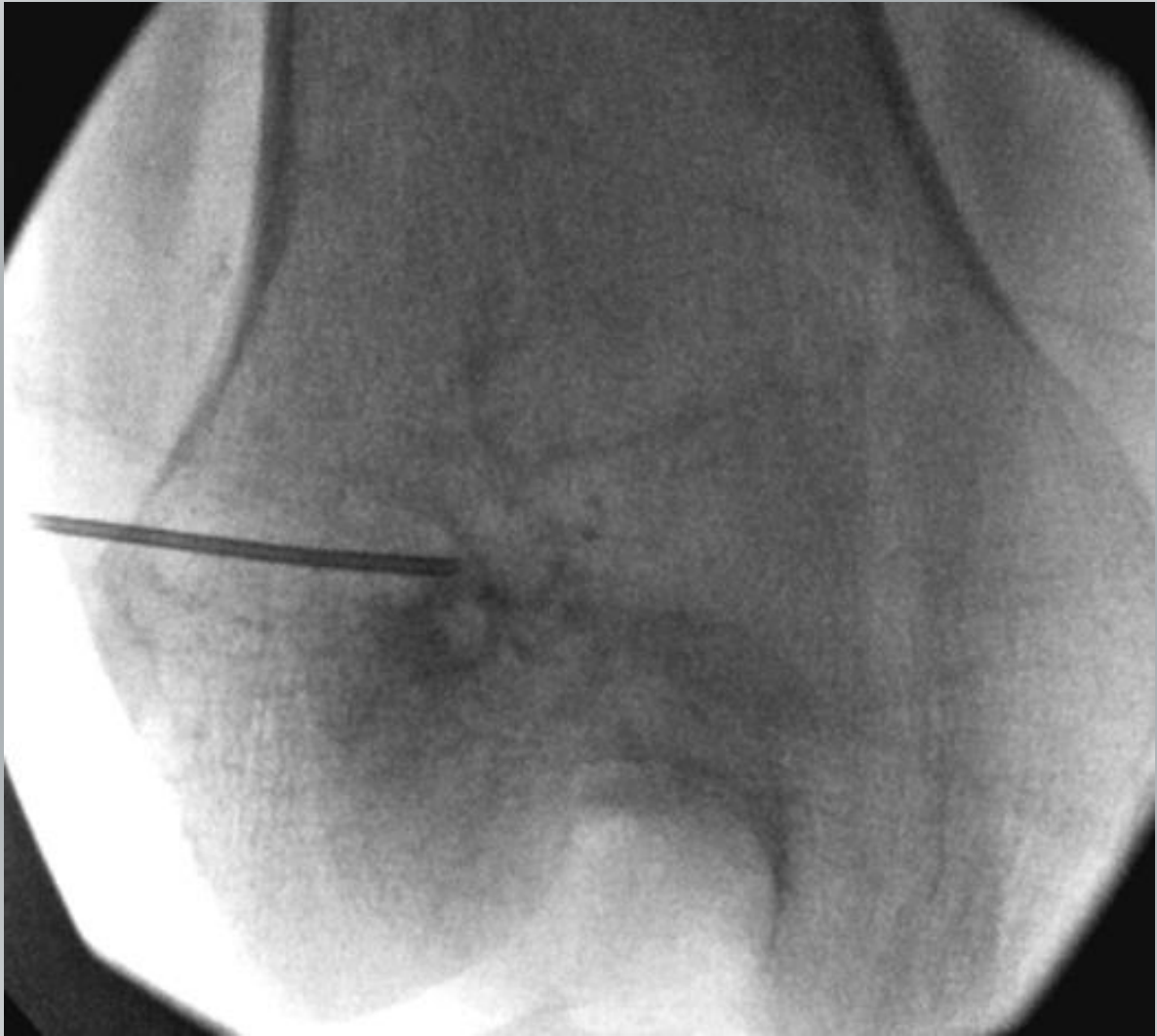

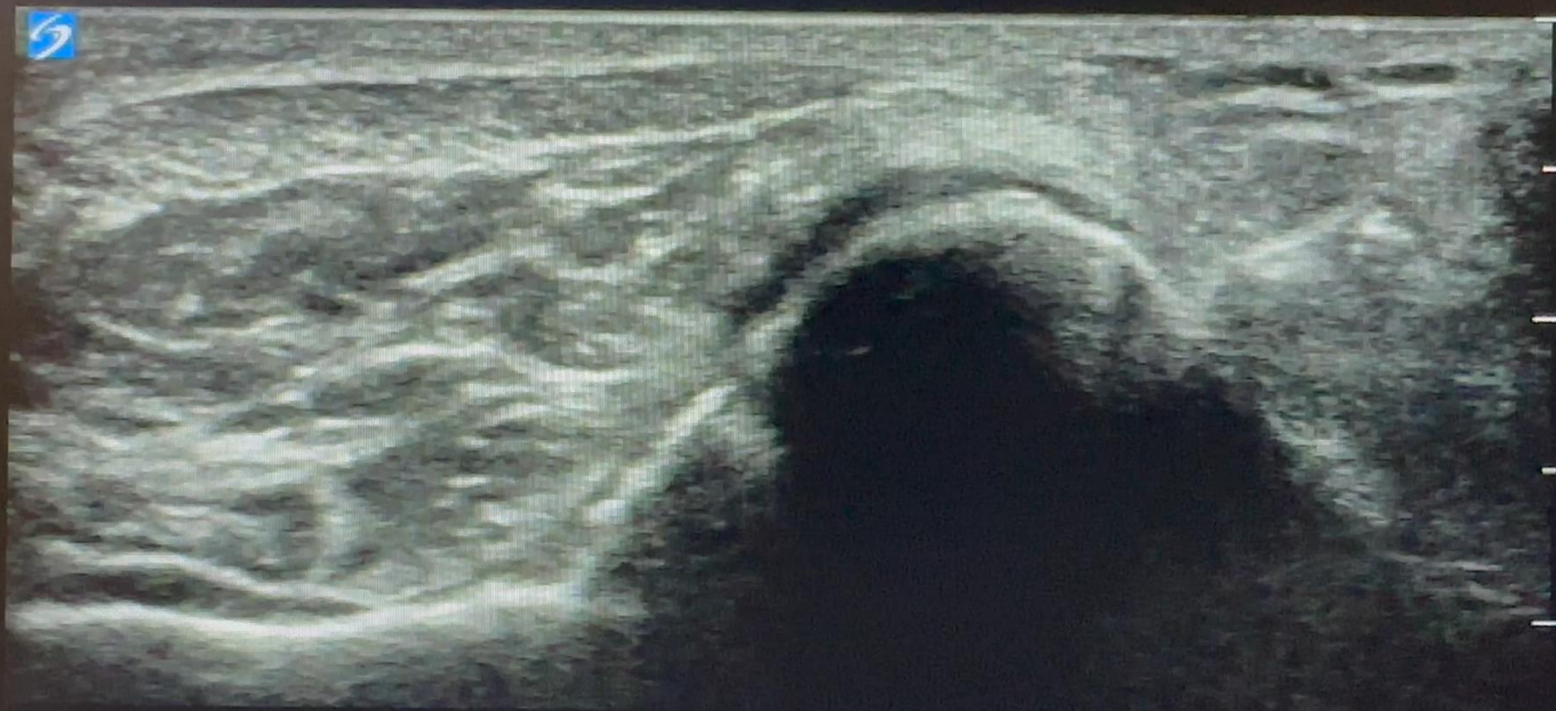












KNEE

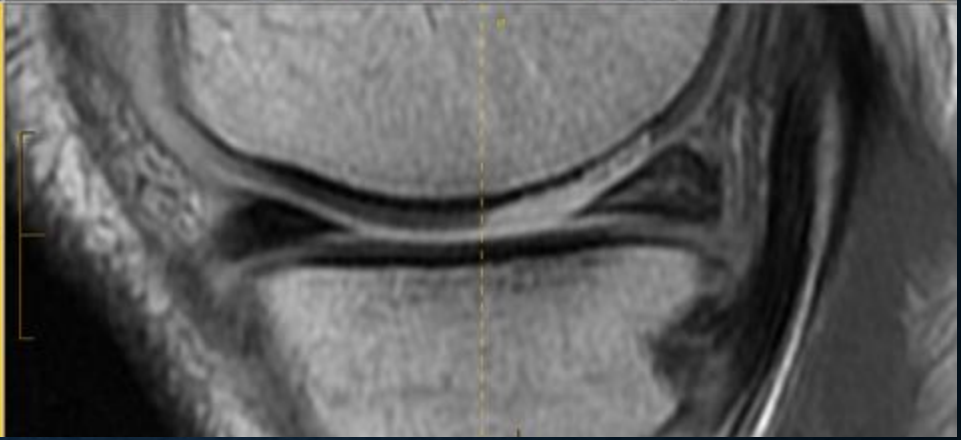
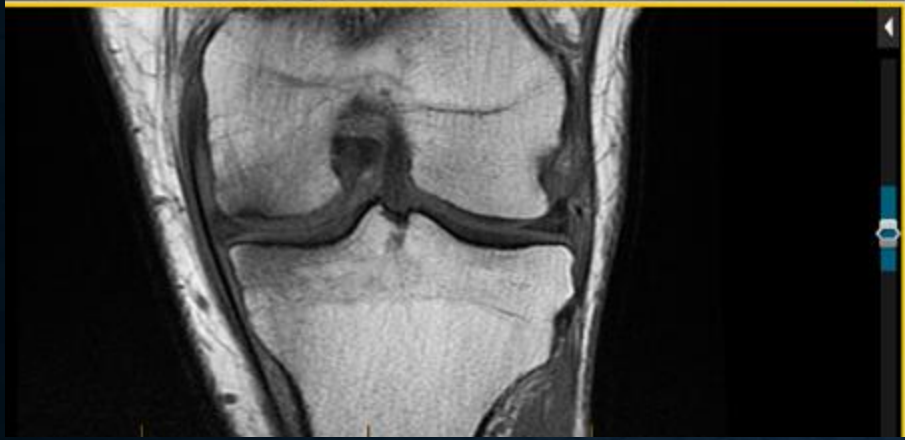
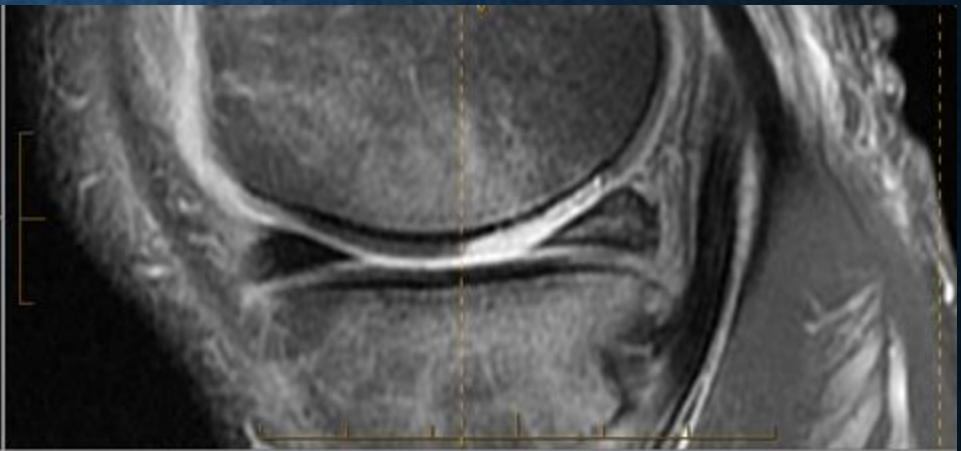
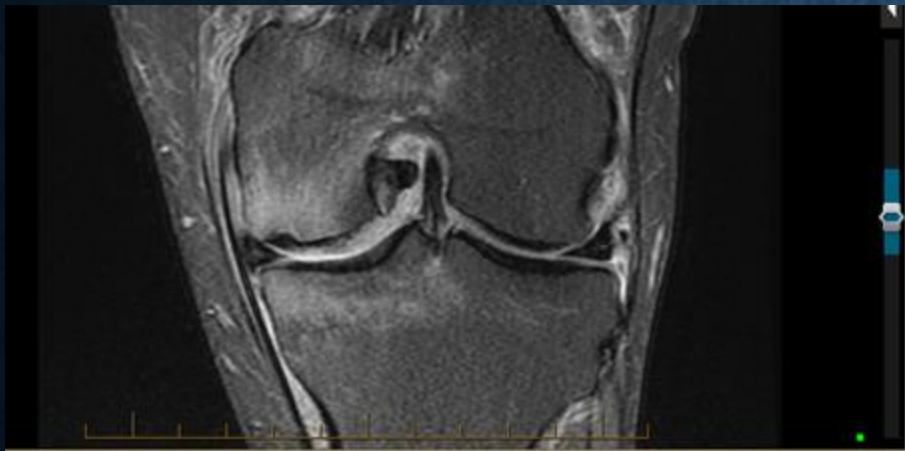Right
SonoSite

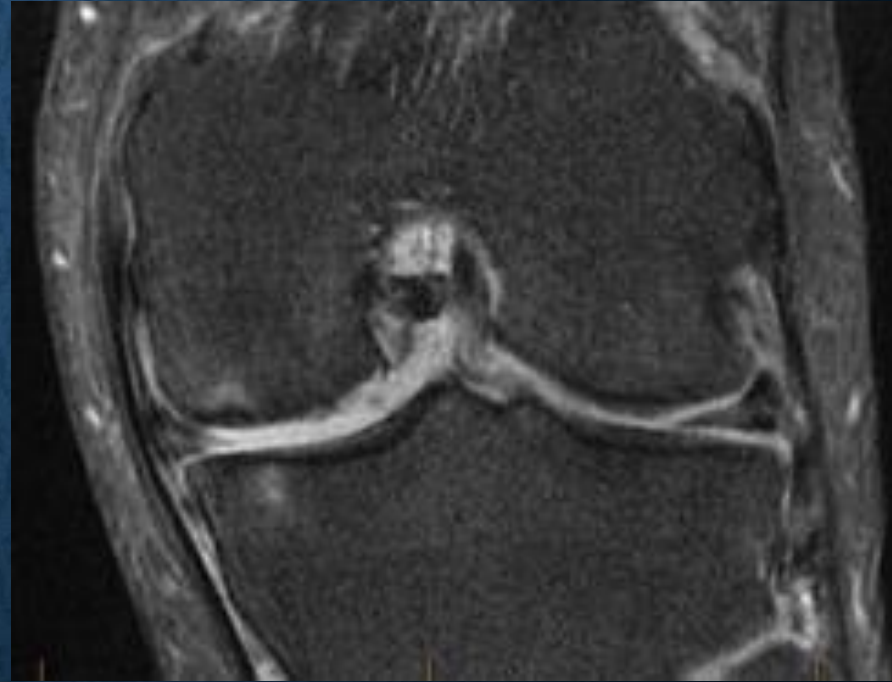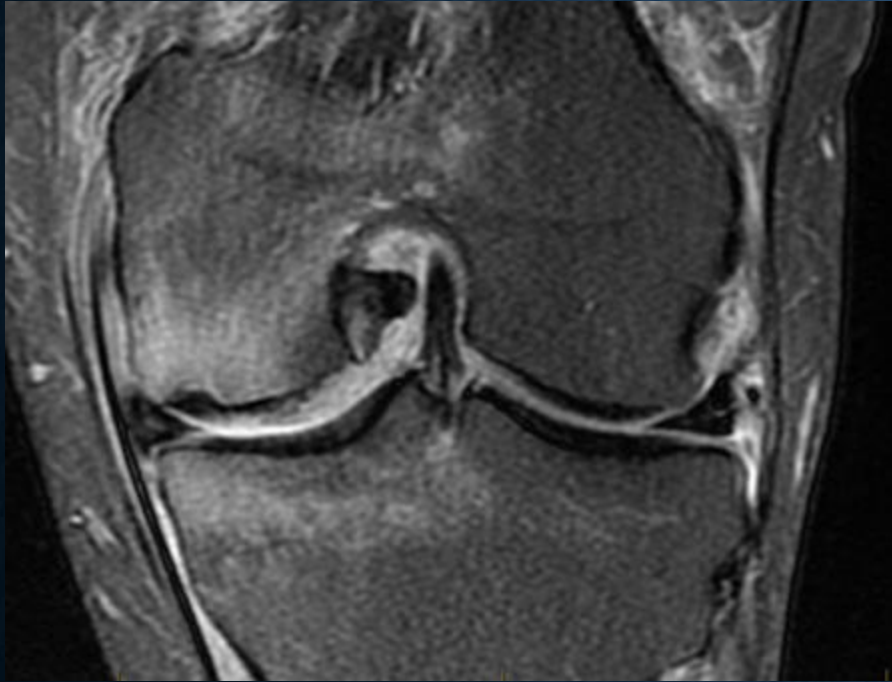2.3 cm

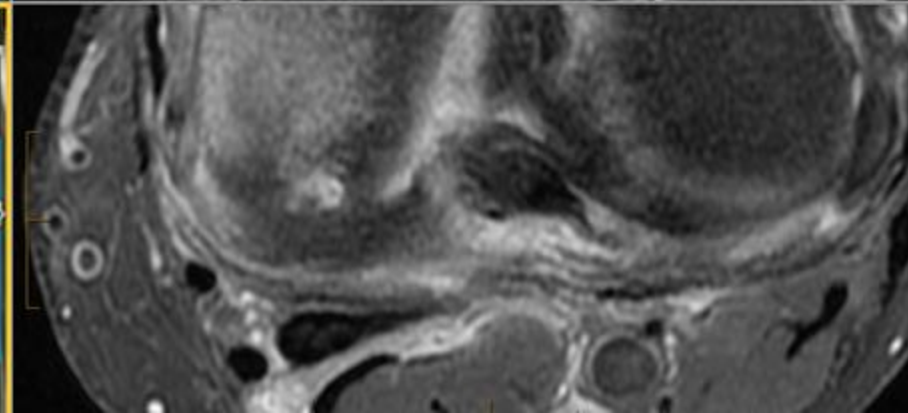
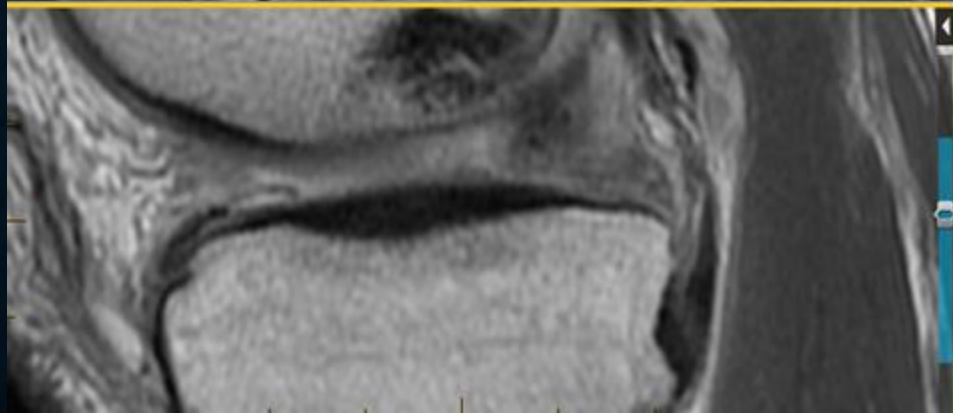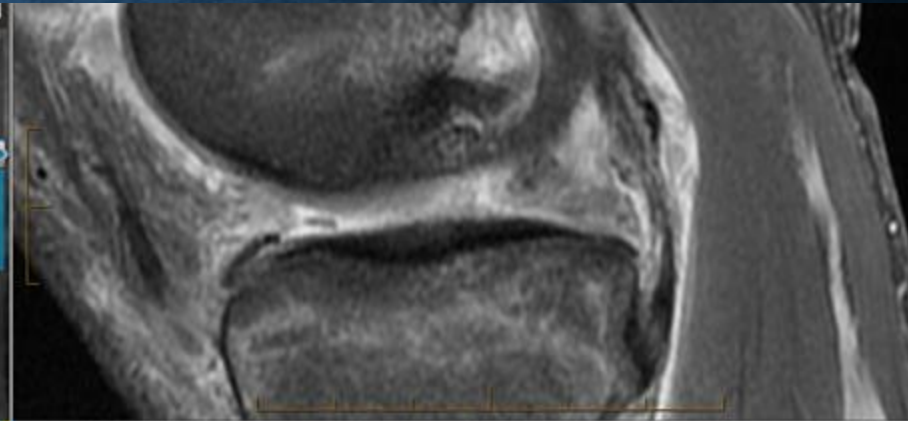
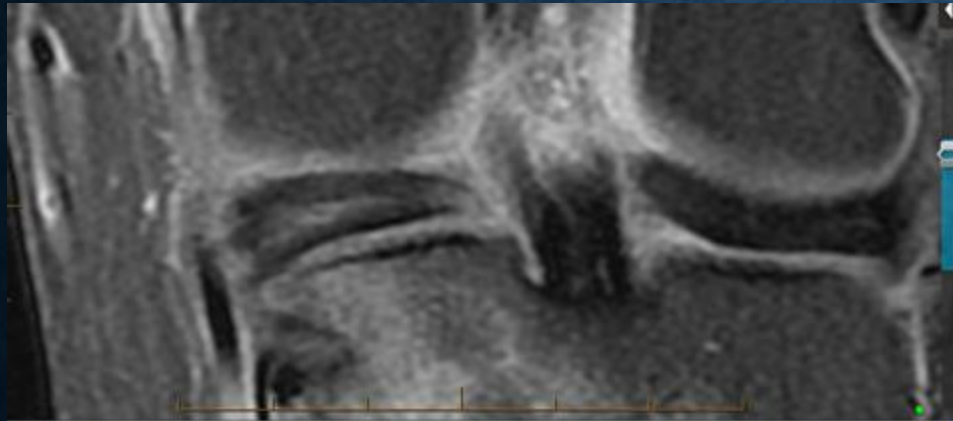2D: G: 50

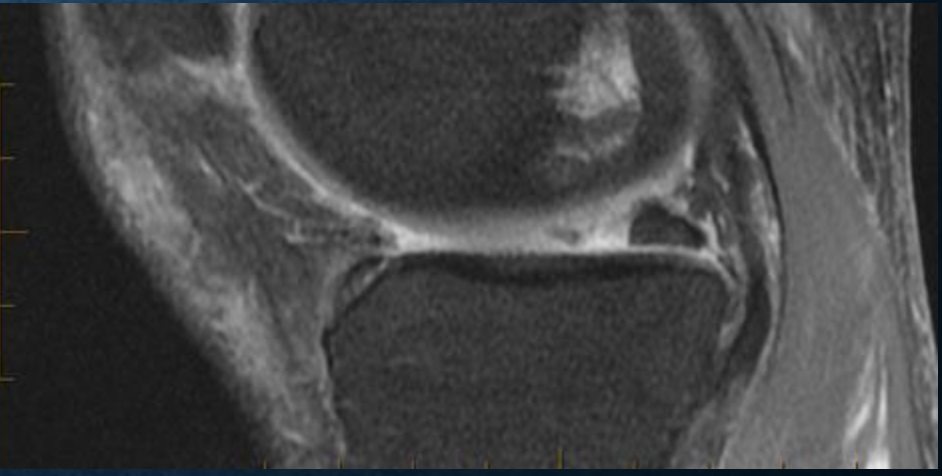
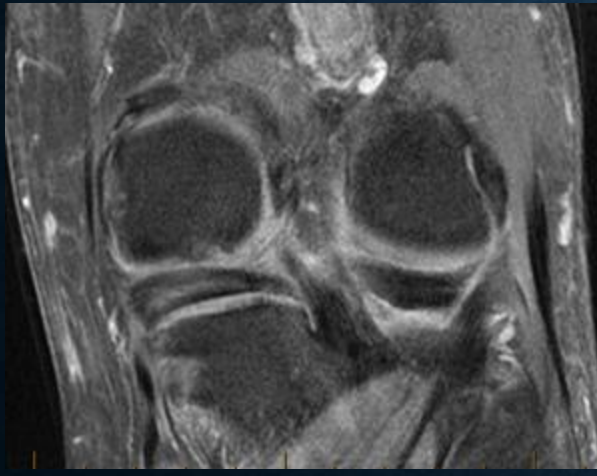
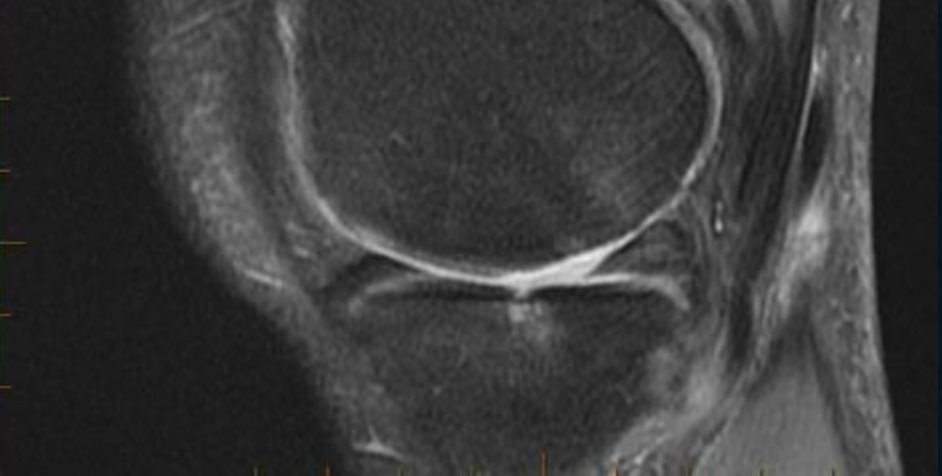
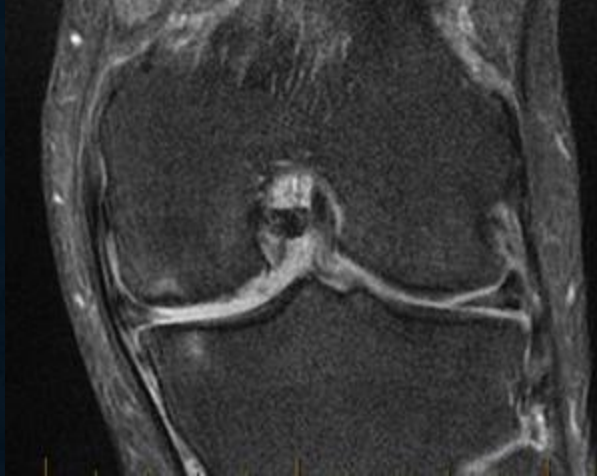An anatomical illustration of a human knee joint. The image is split vertically: the left side shows a normal knee joint in a blue, semi-transparent style, while the right side shows a knee joint with a red and yellow glow, indicating inflammation or pain. The text "KNEE OSTEOARTHRITIS" is centered over the image in a bold, white, serif font.


KNEE OSTEOARTHRITIS












Joint as an
ORGAN
treatment
paradigm

Biologic & Mechanical Ecosystem

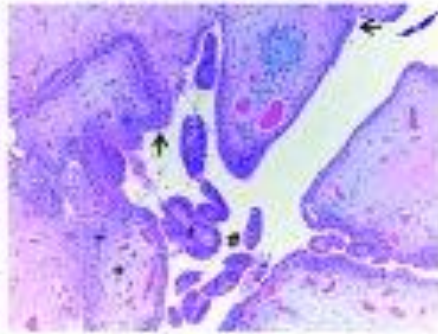
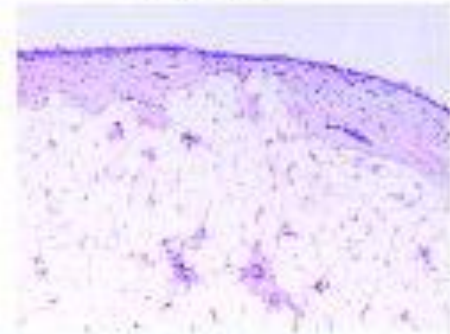
- **Integrated diagnostics**
- **Multi-tissue targeting**
- **Precision delivery & staged therapy**
- **Adjunctive systemic or organismal support**
- **Longitudinal monitoring & imaging proof**
- **Functional outcomes & pain mechanisms**

So “joint as organ” is a paradigm that demands holistic, coordinated, precision biologic/regenerative medicine—not a patch-on or single-tissue fix.

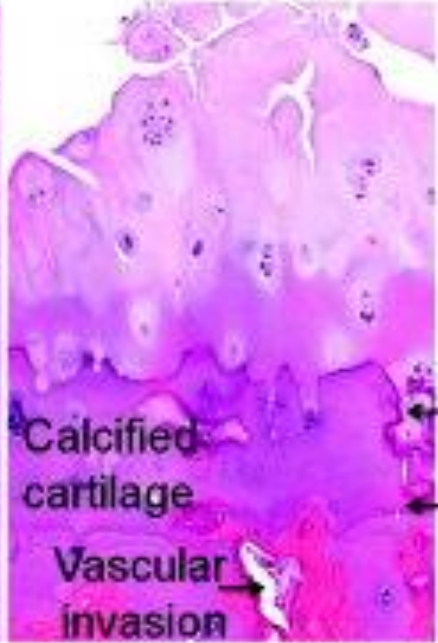


Normal

Osteoarthritis



Synovium



Articular cartilage

Calcified cartilage

Vascular invasion

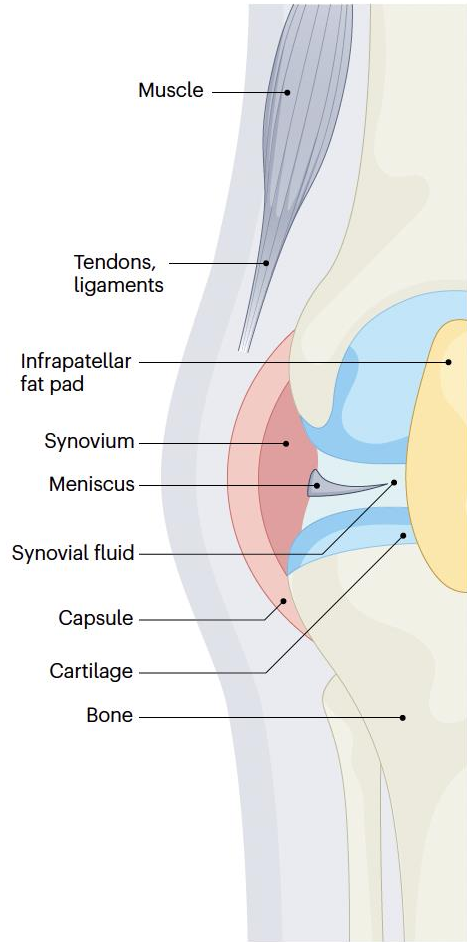
Tidemark duplication

Subchondral bone

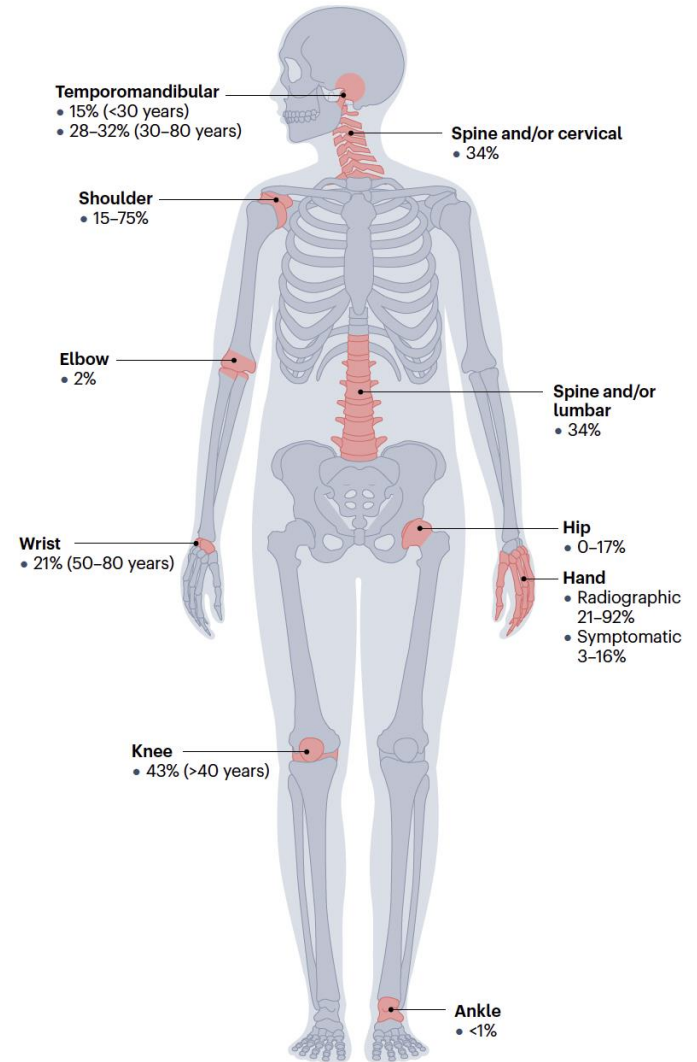
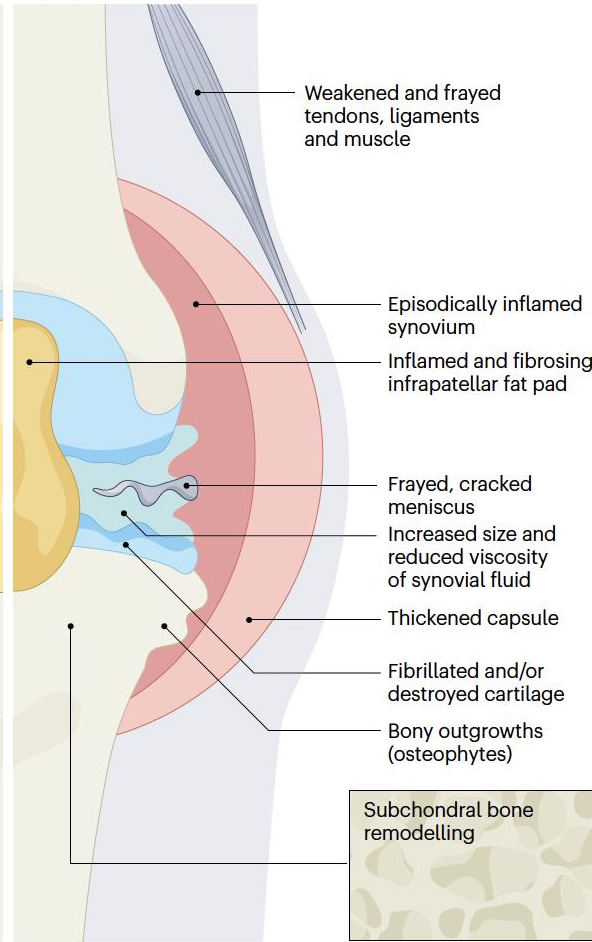
Cascade of OA

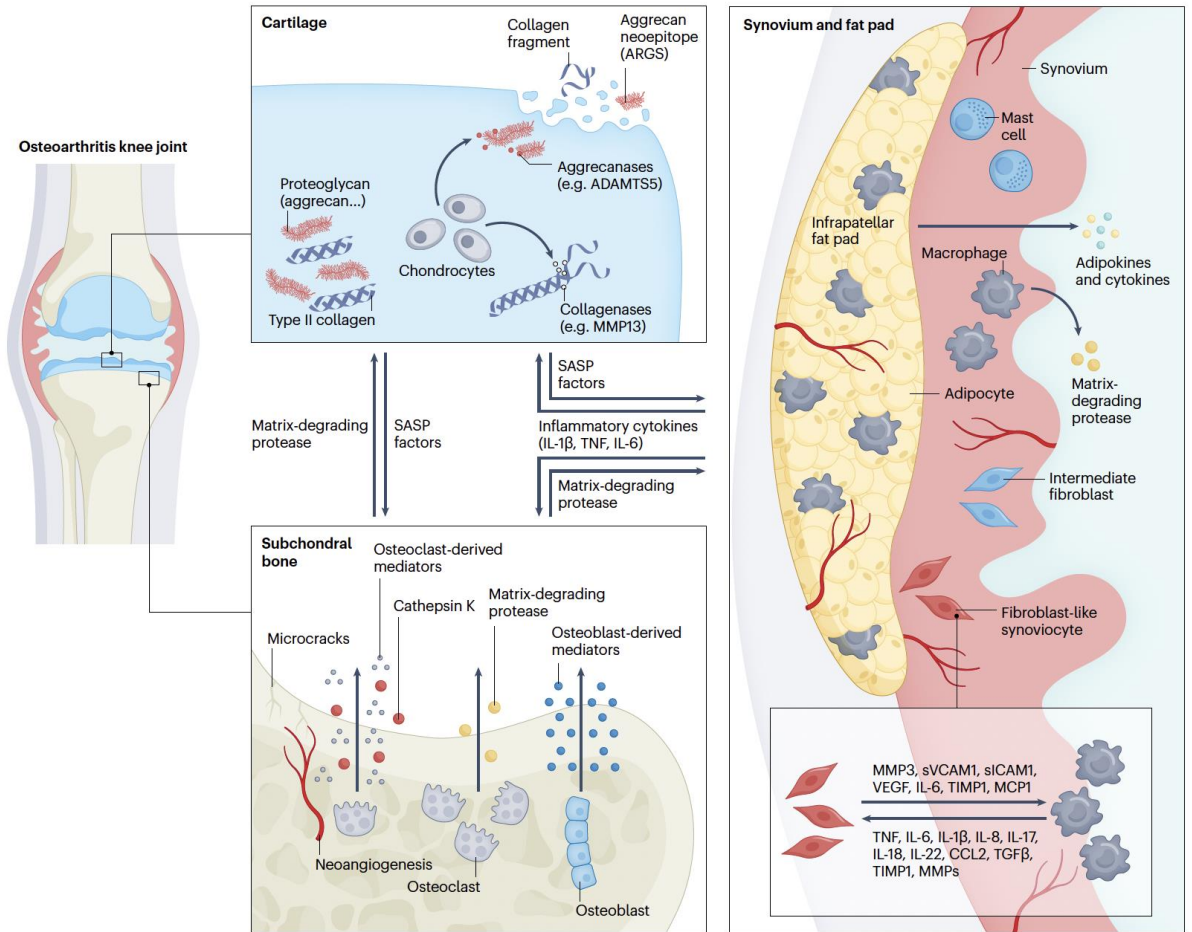
- *systemic inflammation,*
- *fibrosis,*
- *Extracellular matrix (ECM) degradation*
- *neovascularization*
- *Neural sensitization*

a Healthy joint

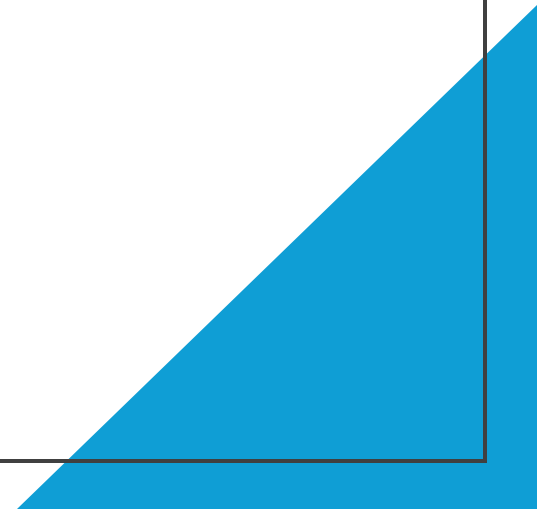


b Osteoarthritic joint





Shift The Narrative





Joint as Organ

Modern OA science (Loeser 2012, Su-an Tang 2025) → Joint = cartilage + subchondral bone + synovium + capsule + ligaments + nerves

Pathology is multi-tissue → “Joint failure,” not just “cartilage wear”

Key takeaway: *Precision therapies must consider the whole ecosystem*

TMJ OA is **not**
only “wear
and tear”

Mechanical overload

Systemic factors

Inflammatory drivers

Patient behavior.

Well Established Risk Factors



Age



Sex



Mechanical Overload/Malalignment



Trauma or Microtrauma



Laxity & Hypermobility



Inflammatory Drivers

Other Probable Contributors



Hormonal & Metabolic Factors



Genetics & Epigenetics




Systemic Disease Associations



Psychological & Behavioral Factors

Systemic Inflammation

Beyond wear & tear: OA linked to systemic metabolic health



Diabetes & hyperlipidemia → increase systemic inflammation



These conditions may predispose to OA or worsen progression



Emphasizes OA as both a mechanical & metabolic disease



Global Osteoarthritis (OA) Projections – 2050

- **Knee OA:** +74.9% → ~642 million people
- **Hand OA:** +48.6% → ~279 million people
- **Hip OA:** +78.6% → ~62.6 million people
- **Other OA (foot, ankle):** +95.1% → ~118 million people
- **Drivers:** population growth & aging
- **Implication:** urgent need for **public health strategies & interventions** to manage rising OA burden

OA is not One Disease

Phenotype

- Pain-Dominant
- Structural Deformity
- Inflammatory Flares
- Post-Trauma
- Mechanical Overload

Endotype

- Inflammatory Cytokine-Driven
- Subchondrol Bone/Angiogenesis
- Metabolic/Obesity Related
- Cartilage Matrix Degeneration
 - MMP, ADAMTS
- Neuropathic Sensitization



Mortality Risk

- ***high cardiovascular comorbidity and walking disability burden among people with OA***
- ***excess mortality risk is also mediated through depression, anxiety and unrefreshed sleep, often associated with OA***

Genetics Of Degeneration

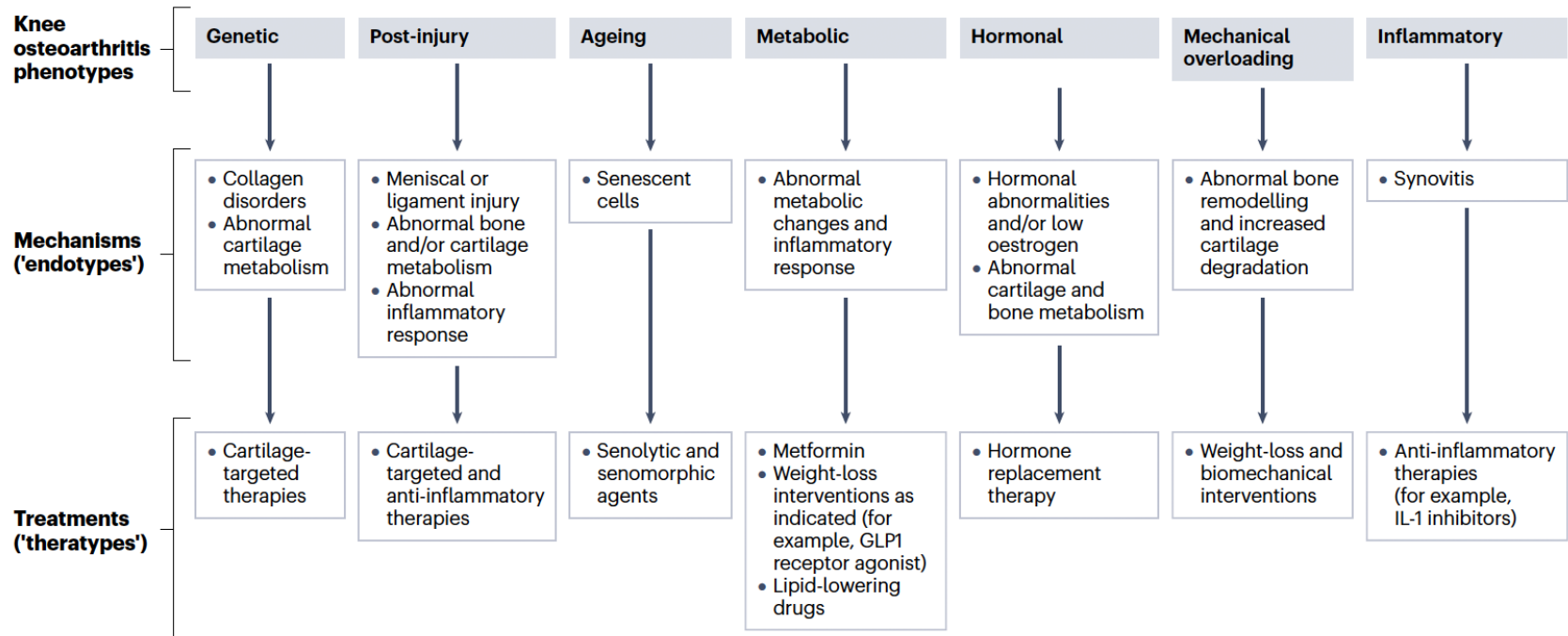
+

•

○

- *Genome-wide association studies have identified over **120 genetic loci associated with various OA phenotypes***
- *Several detected genes are implicated in*
 - ***key structural and inflammatory pathways***
 - ***collagen biosynthesis***
 - ***developmental***
 - ***exacerbate OA-associated inflammation***
 - ***severe chronic pain following joint arthroplasty***

Knee Arthritis Phenotype & Endotype



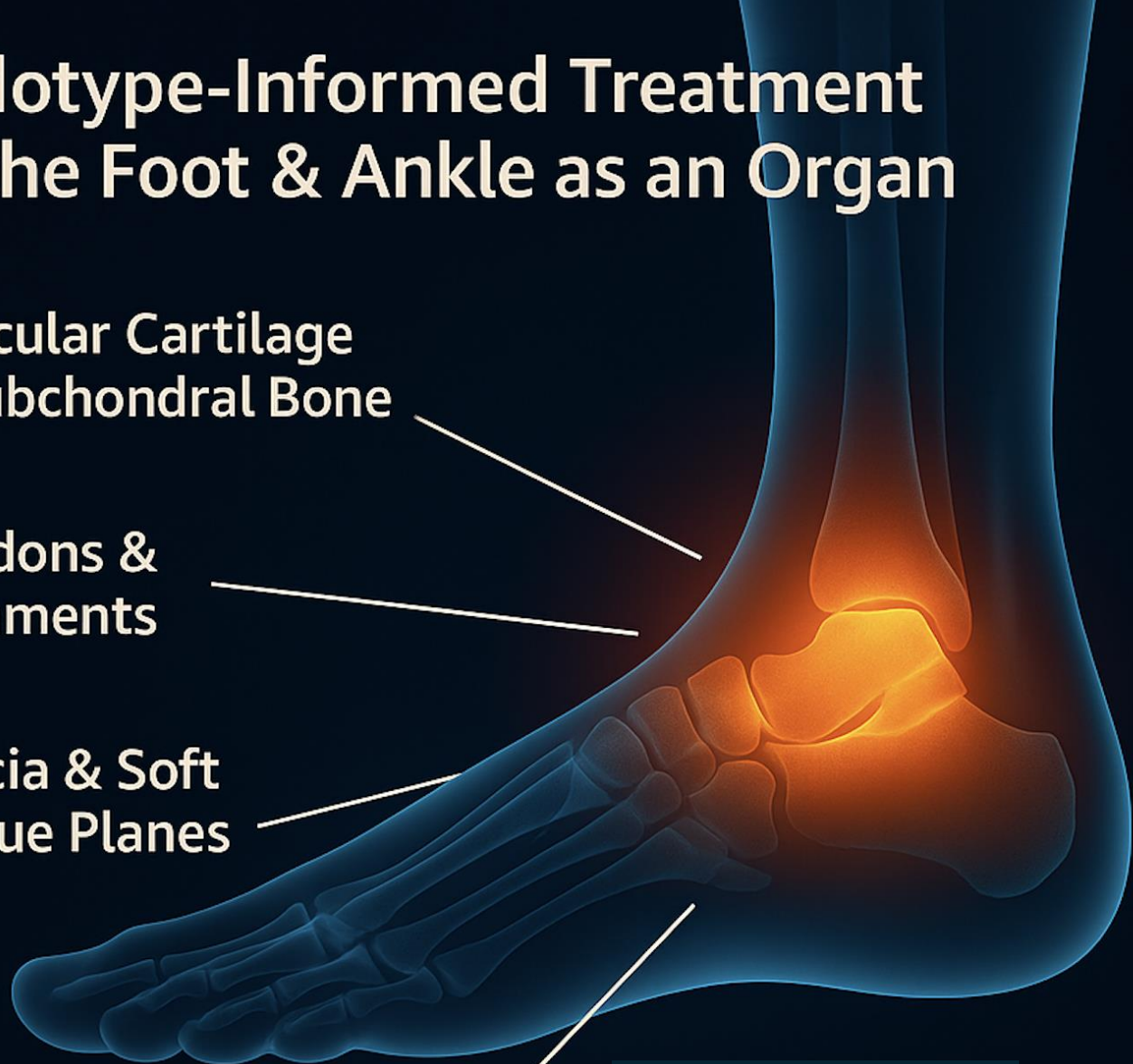
Endotype-Informed Treatment of the Foot & Ankle as an Organ

Articular Cartilage
& Subchondral Bone

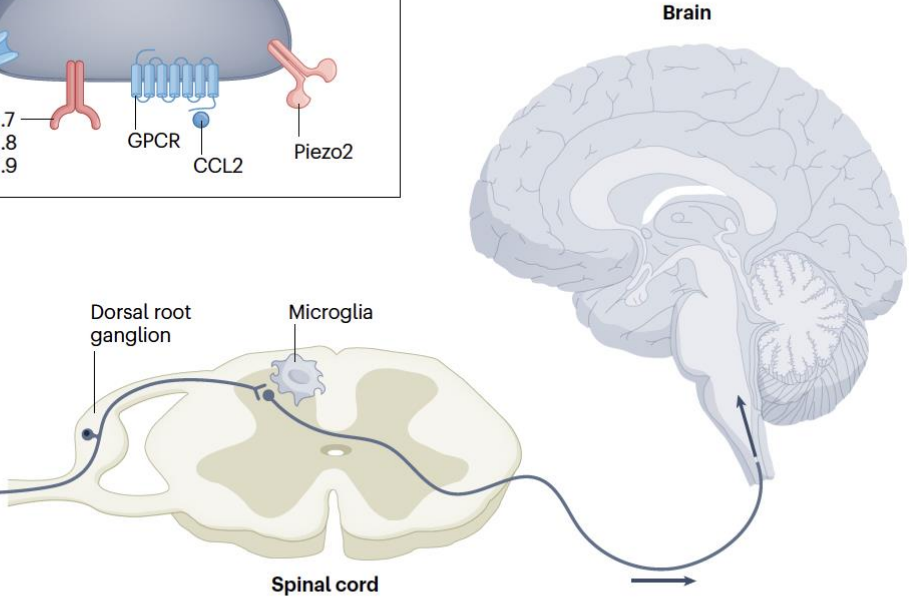
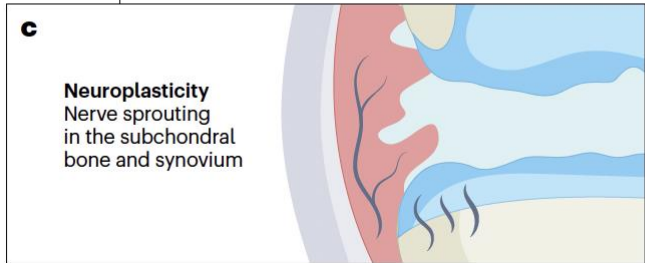
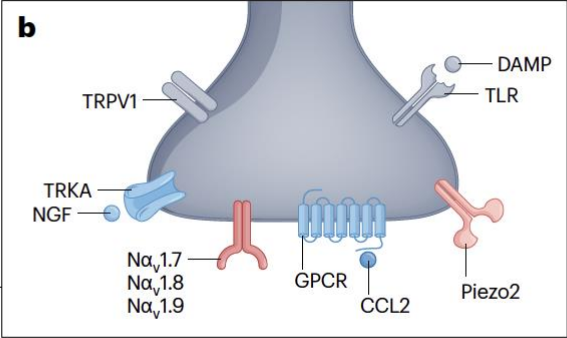
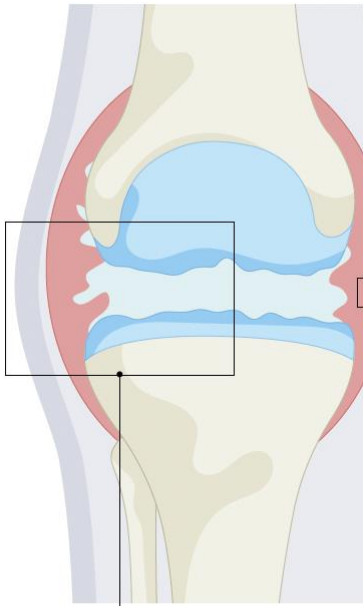
Tendons &
Ligaments

Fascia & Soft
Tissue Planes

Neurosensory
& Vascular Components

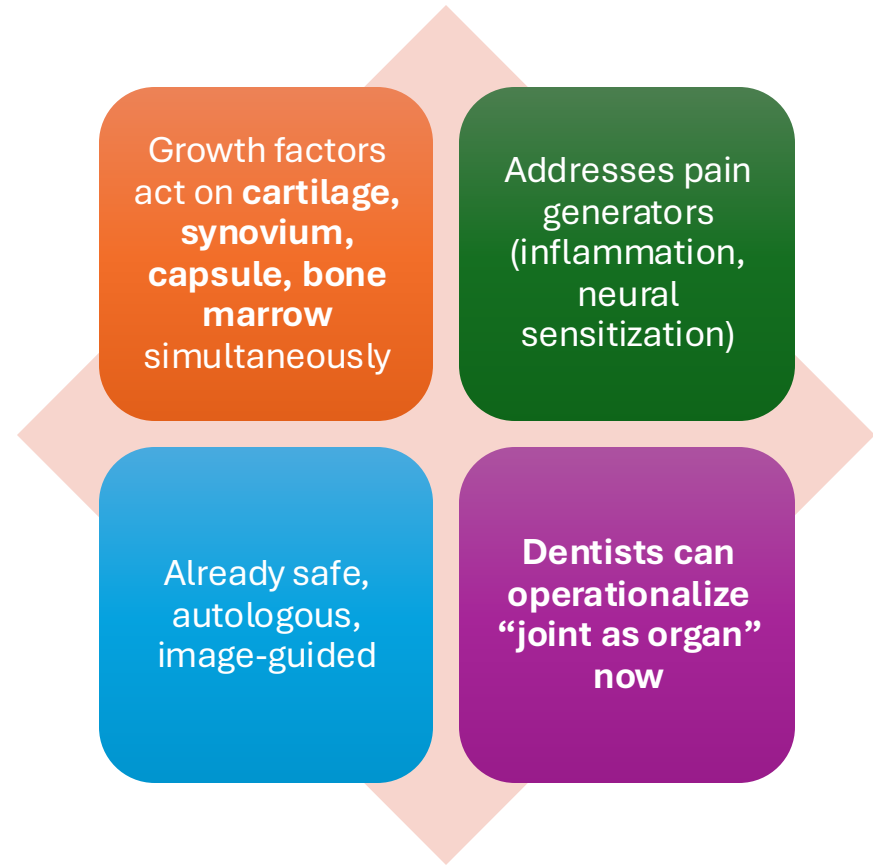


a Osteoarthritis knee joint



“Now that we can name
the pattern, we can target
the biology.”

Why PRF/PRP +PBM Fits the “Organ” Model



Treatment of joints as organ

- **Fibrocartilage & Subchondral Bone** (condyle, eminence)
- **Synovium & Capsule** (inflammation, effusion, capsulitis)
- **Ligaments & Muscles** (laxity, overload)
- **Neurosensory** (peripheral/central sensitization)

Endotype-Informed Foot & Ankle Treatment Pathways

Endotype	Target / Lesion	Regenerative Therapy	PBM Role	Holistic Support
Inflammatory	Synovitis, effusion, tenosynovitis	US-guided intra-articular or peritendinous PRP/PRF (LR-PRP)	Short anti-inflammatory PBM block: reduce swelling and pain	Load modification, footwear optimization, anti-inflammatory diet
Bone / BML	Subchondral bone lesions, stress reactions, osteochondritis	Subchondral "IO" PRP / stem cell biologic conditioning	PBM to enhance bone metabolism and osteoblast activity	Vitamin D & K2 optimization protein sufficiency graded w/ bear
Mechanical / Instability	Ligamentous laxity, chronic ankle instability, plantar plate micro-tear	Capsular / ligament PRP or BMAC	PBM for muscle tone, proprioception and collagen remodeling	Strengthening, balance retraining, orthotic tuning
Fascial / Myofascial	Plantar fasciitis, fascial fibrosis, soft-tissue adhesions	Fascia-targeted PRP/PRF, percutaneous hydrodissection	PBM to improve microcirculation and fibroblast remodeling	Footwear support, mobility work, night splint as needed
Neurosensory	Neuropathy, neuritis, complex pain sensitization	Perineural PRP, exosome, or neuro-modulatory milieu	PBM neuromodulation for pain, nerve repair, microvascular flow	Glycemic control, stress modulation, red-light home use

Matching foot and ankle endotypes to regenerative therapies, PBM integration, and holistic care.


Precision Delivery

- **Synovitis/Effusion:** US-guided intra-articular PRP/PRF; aim just superior to disc–condyle interface; small volume, slow inject.
- **Capsule/Ligaments:** US-guided capsular line peppering PRP/PRF for laxity/pain generators.
- **Subchondral Bone (condyle):** Targeted near-osseous deposition (US landmarks); consider low-volume biologic priming.
- **Myofascial Drivers:** Masseter/temporalis fascia PRP micro-threading (if indicated).

PBM: Anti-inflammatory, Analgesic, Pro-repair

- **Why here?** TMJ is millimeters deep → extraoral PBM reaches target.
- **When?**
 - **Pre-conditioning (5-7x/wk × 2 wks):** reduce baseline synovitis & pain
 - **Immediate post-inject (48–72 h):** mitigate flare, support cell signaling
 - **Rehab phase (5-7x/wk × 8–12 wks):** tissue remodeling, neuromodulation
- **Dosing anchor (with your panel @ 300 mW/cm² at 3”):**
 - Cheek site **12–15 min**; lip/mandible **<3 min**; neck **14–16 min** (to reach ~1–6 J/cm² at mucosa; aligns with extraoral OM dosimetry).
- **Message:** PBM operationalizes “organ-level” care without adding invasiveness.

Host Matters: Make Biology More Repairable

- **Sleep & Stress** → **bruxism load** (screen; simple CBT-I cues, magnesium, appliance adjustment)
 - **Metabolic:** protein ≥ 1.2 – 1.6 g/kg/day; vitamin D sufficiency; omega-3s
 - **Anti-inflammatory diet** (+ weight optimization if needed)
 - **Airway:** screen OSA; referral if high risk
- 

Staged, Not One-and-Done?

Stage 0 (2–4 wks): PBM pre-condition, load hygiene, brief NSAID taper plan if needed

Stage 1 (Day 0): Image-guided PRP/PRF (dominant compartment first)


Stage 2 (2–6 wks): PBM rehab + motor control; reassess pain/function

Stage 3 (8–12 wks): Second Treatment (e.g., capsule/ligaments or subchondral) if still indicated
BOOSTER?

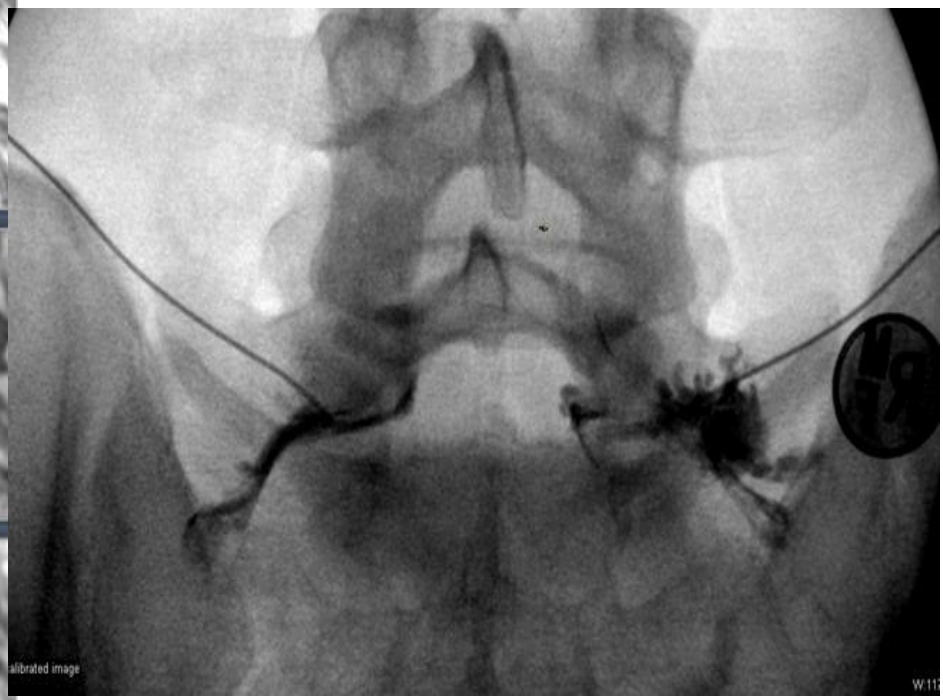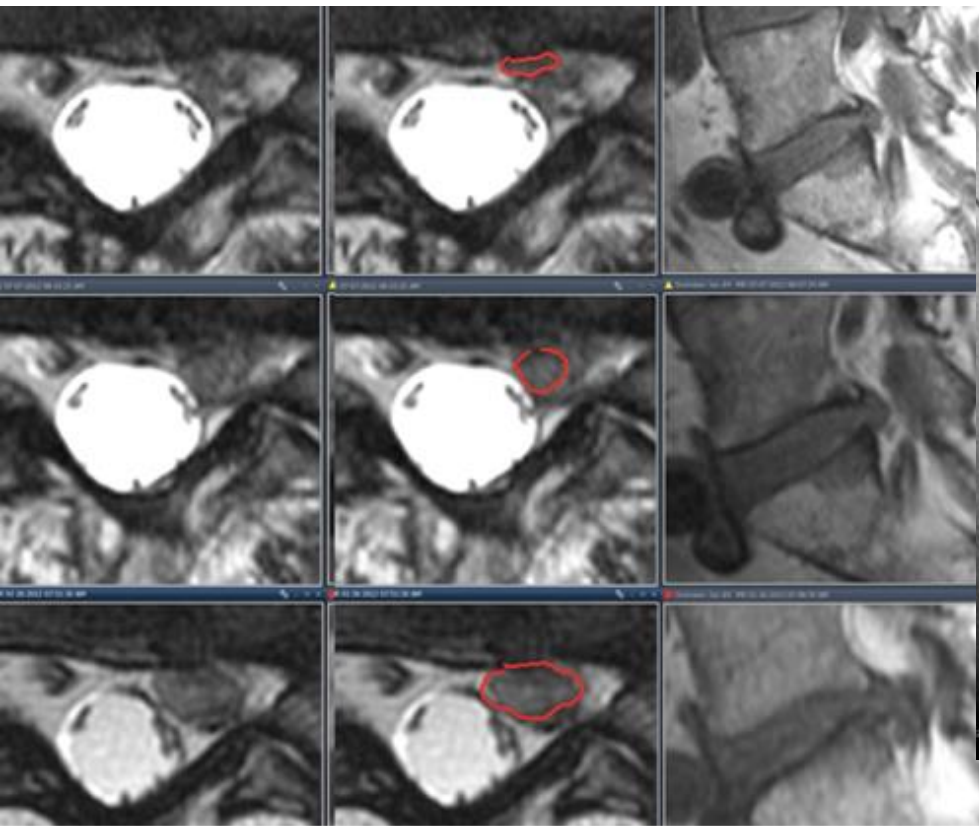
Follow-up imaging when changing plan or documenting structural change

But Here is the GAP!

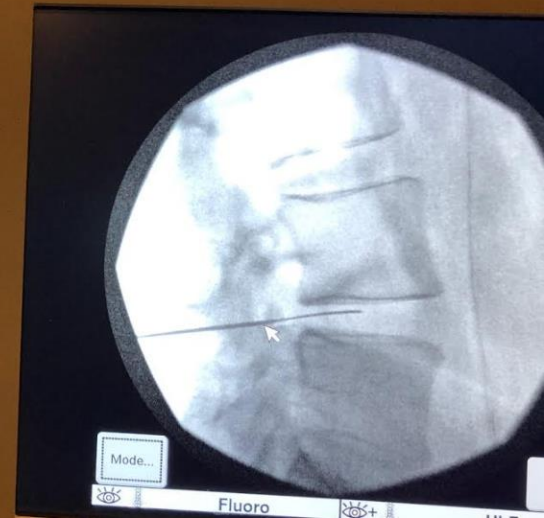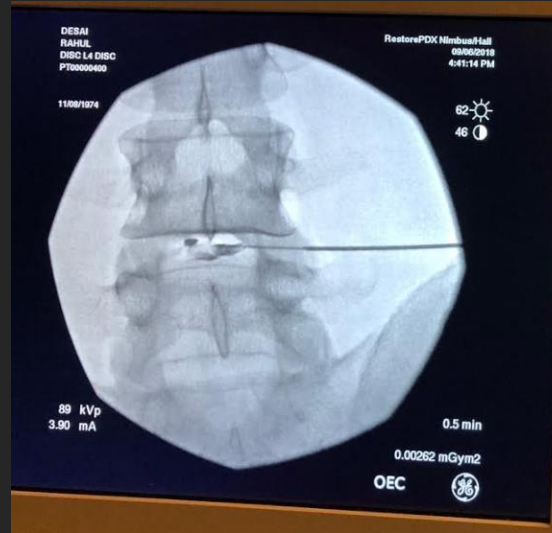
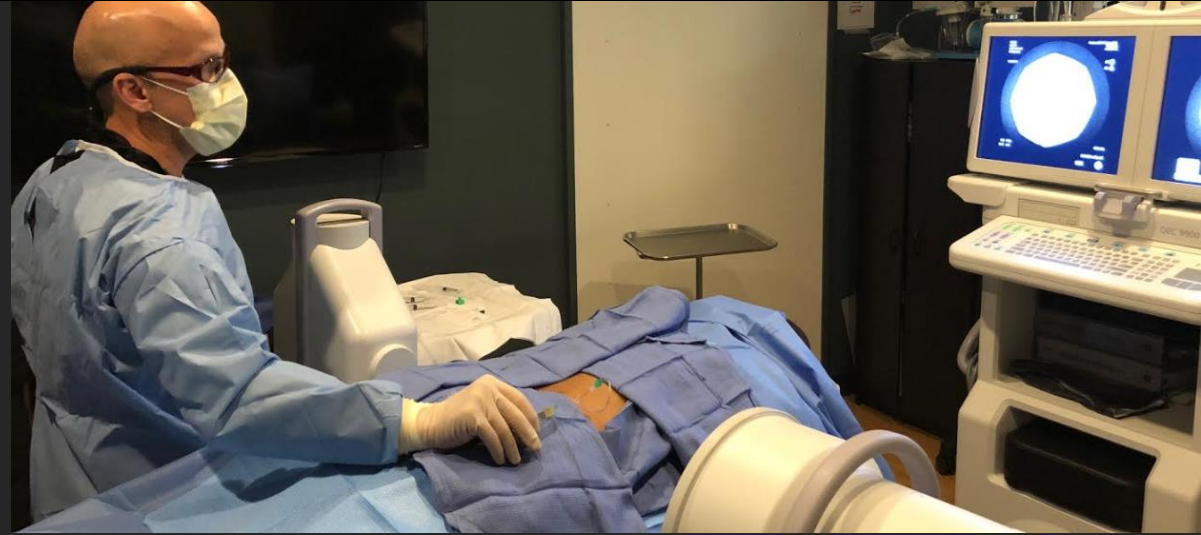- Landmark reviews cover cytokines, growth factors, stem cells, gene editing
- **PRP is NOT mentioned** (despite widespread clinical use)
- Disconnect between *bench science* → *review articles* → *clinical practice*



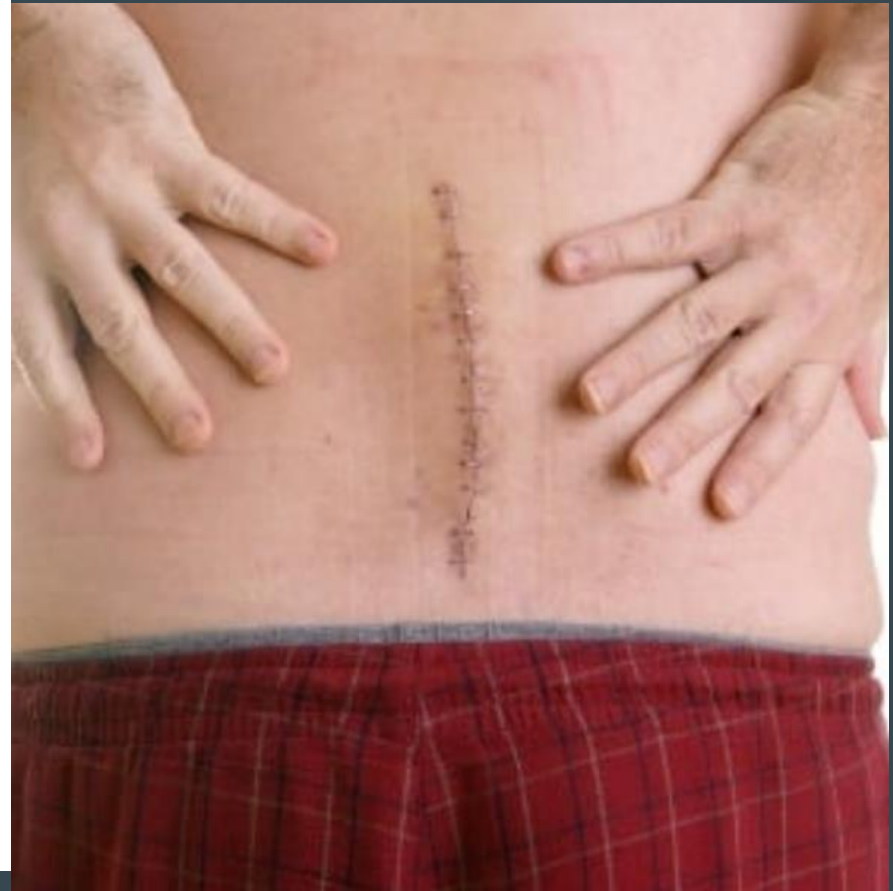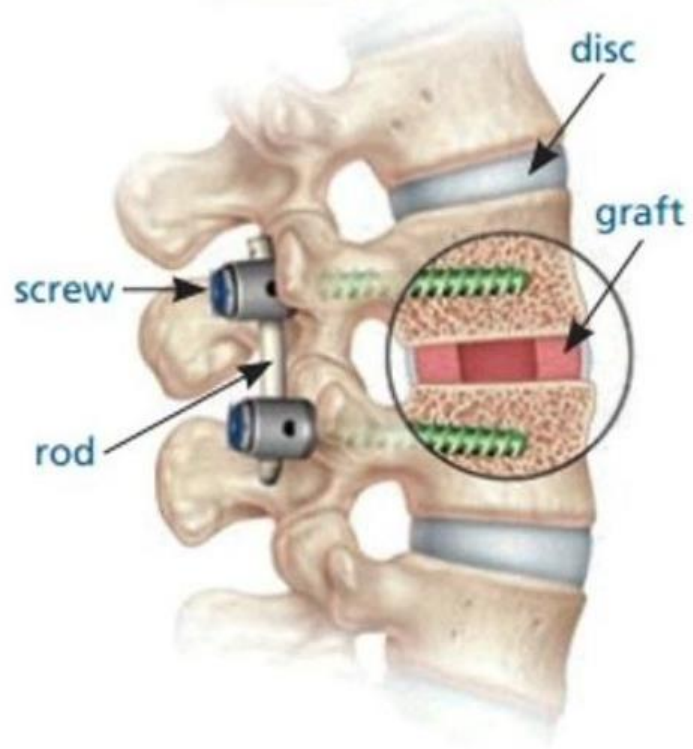
Our Talk is about
the
POSSIBILITIES!

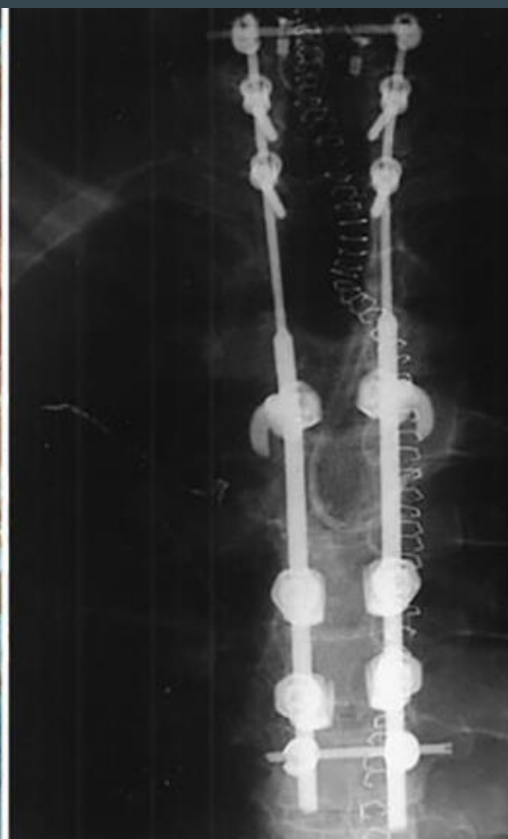
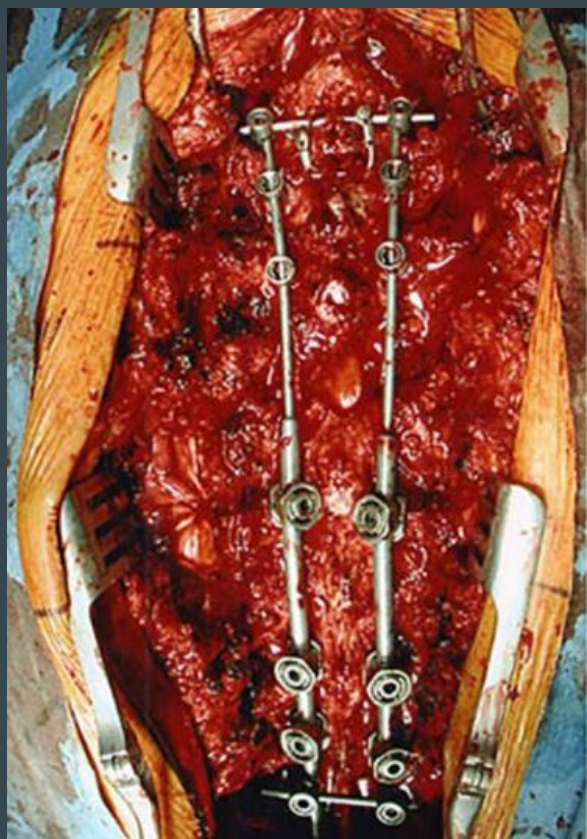


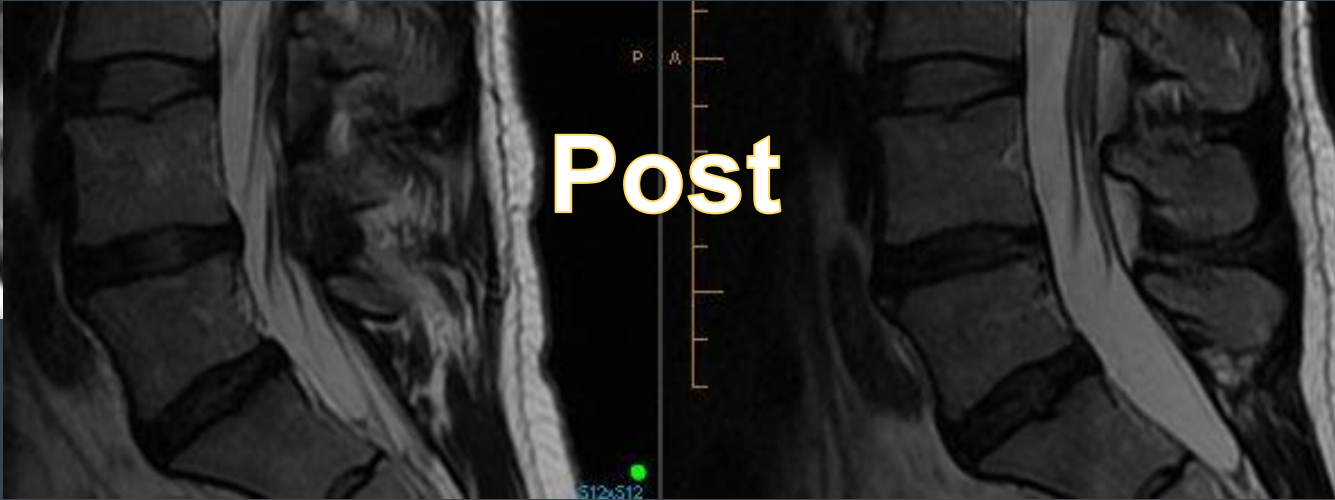
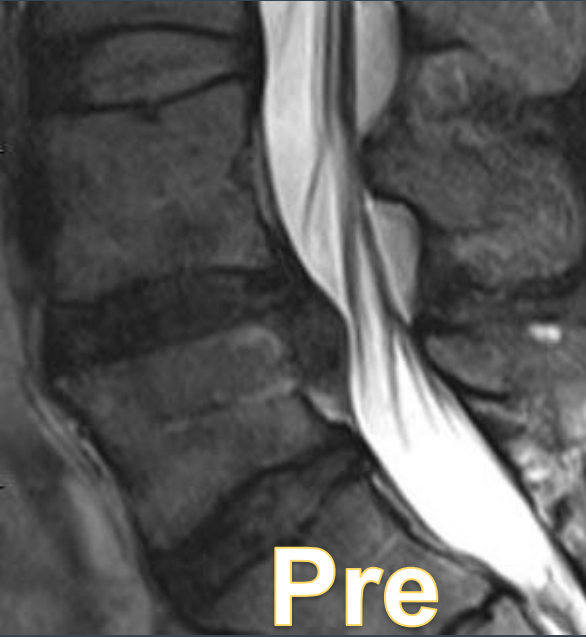Intra-Discal Therapy – The Game Changer

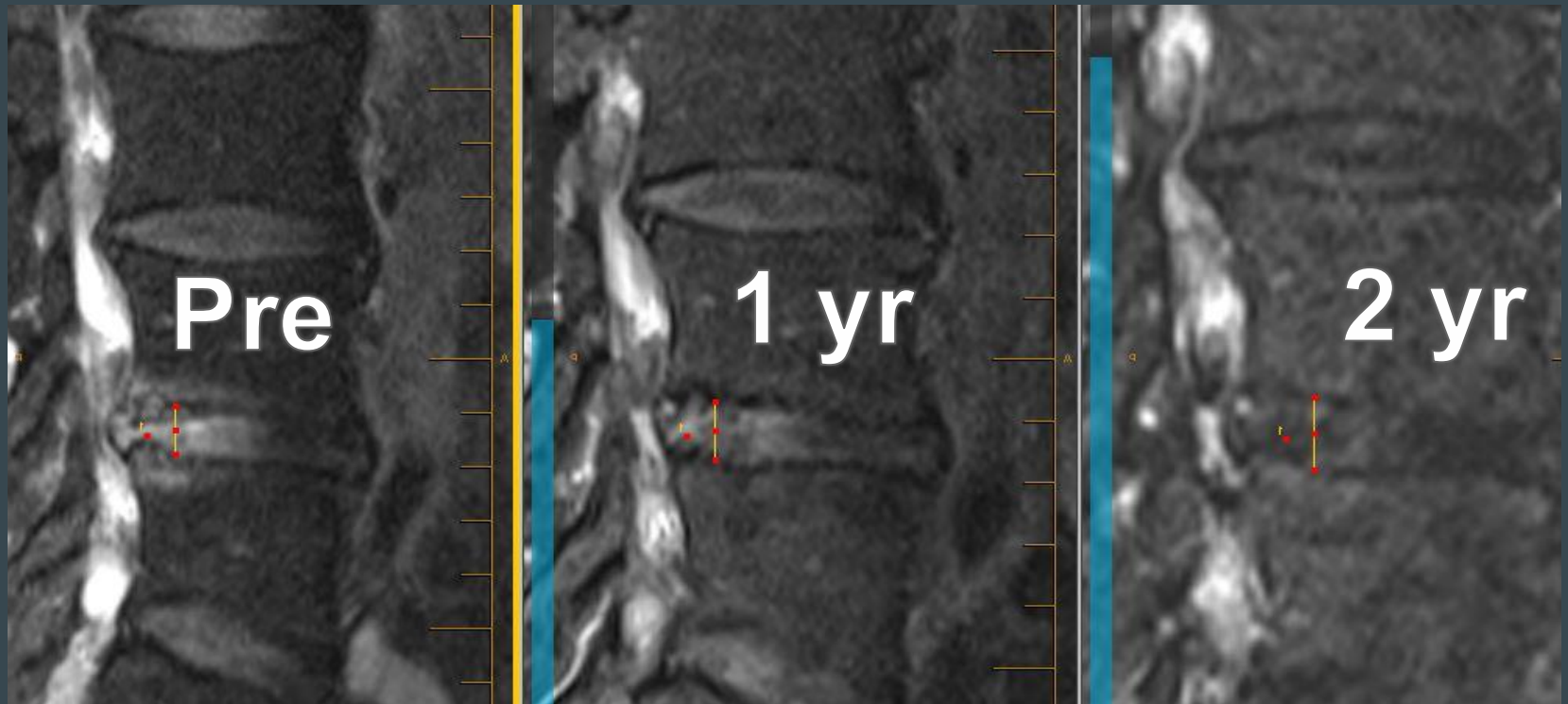


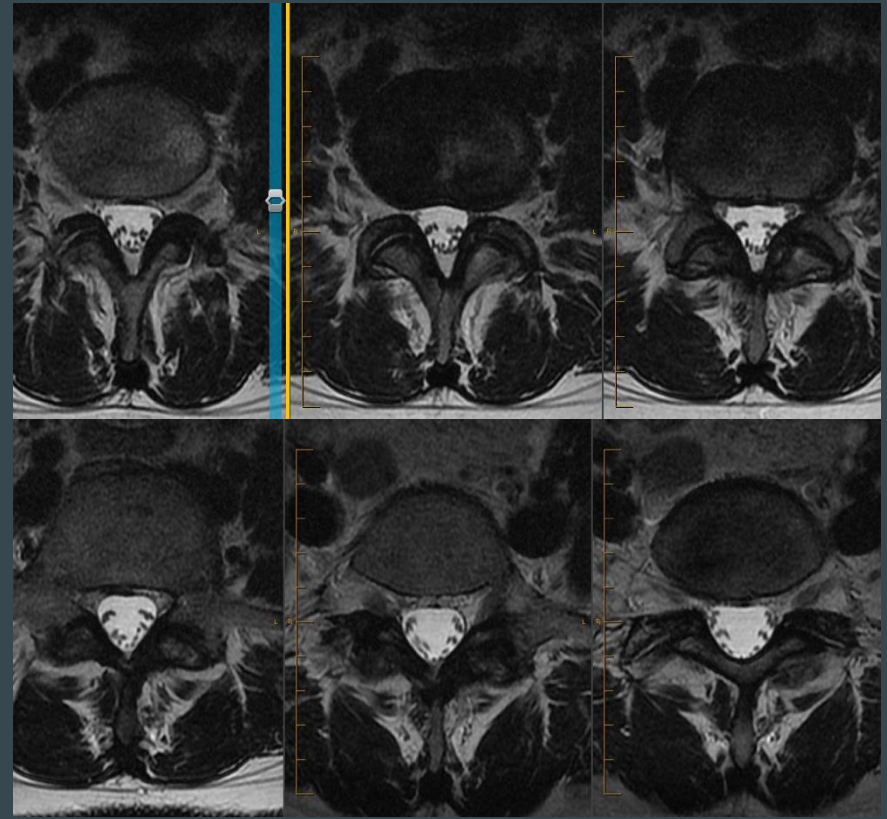
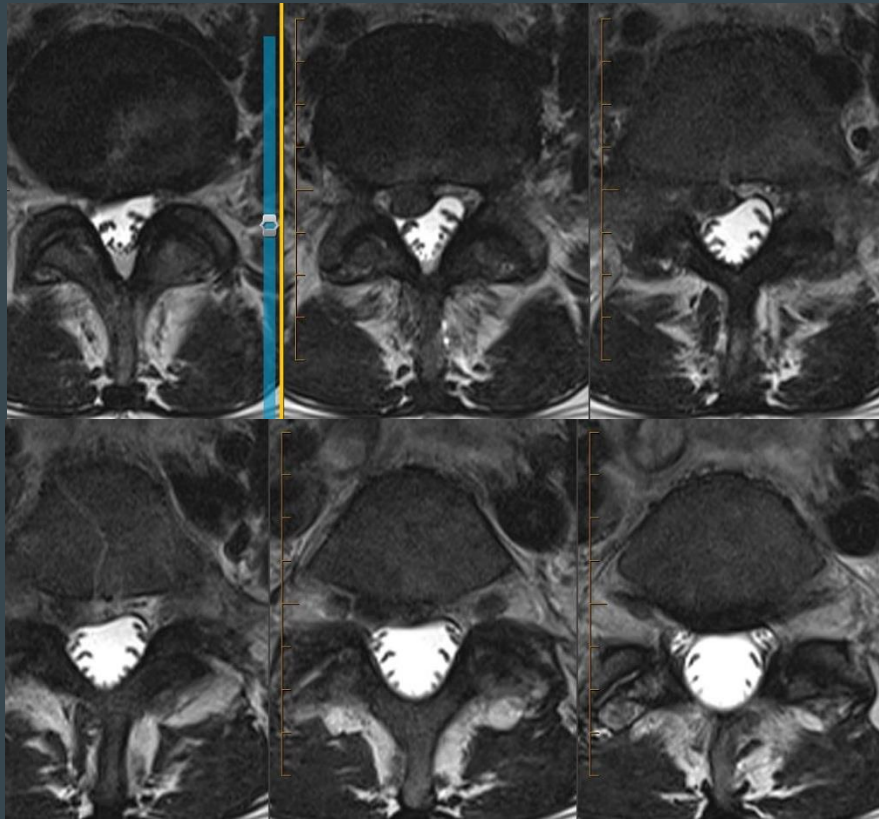
LUMBAR FUSION

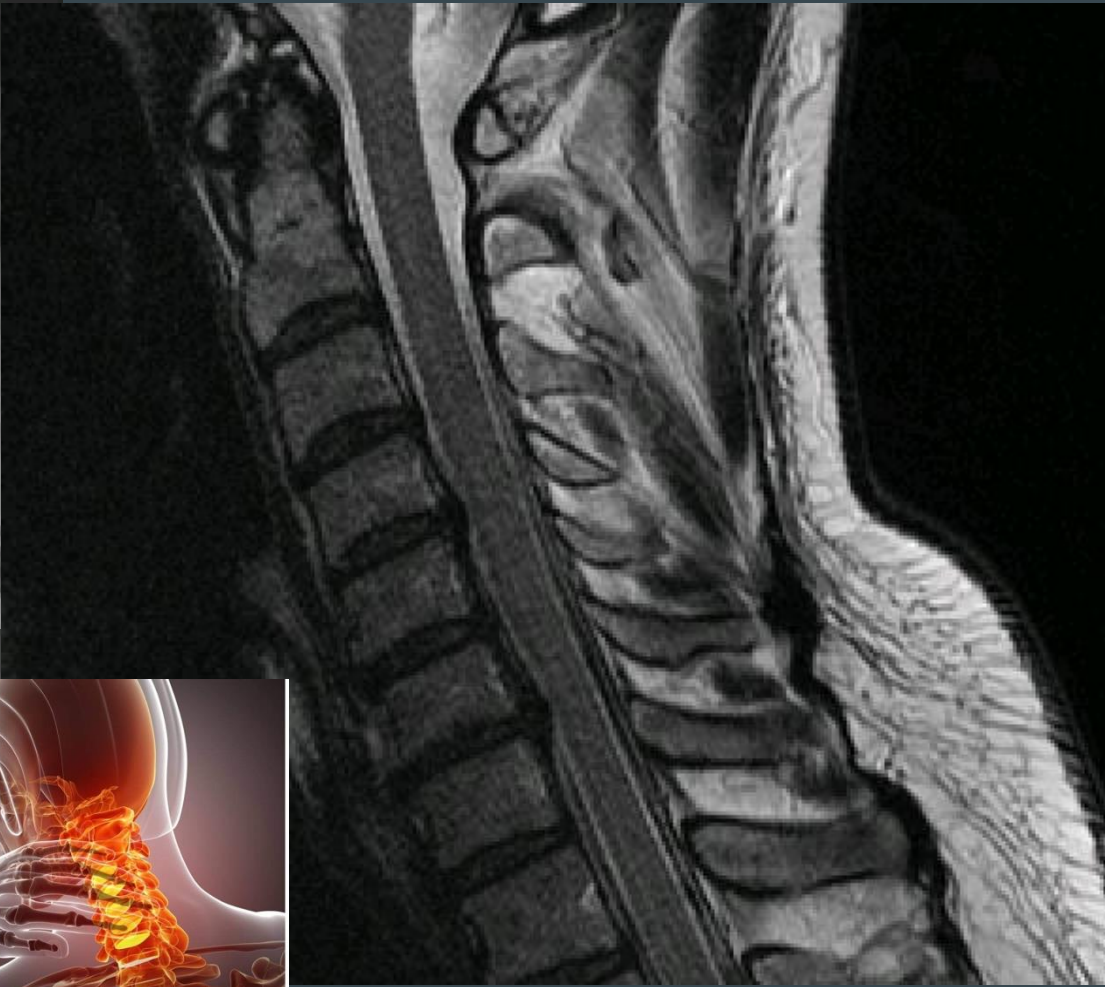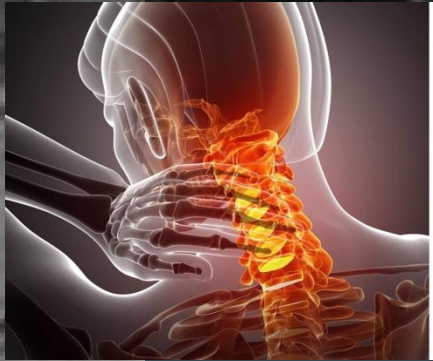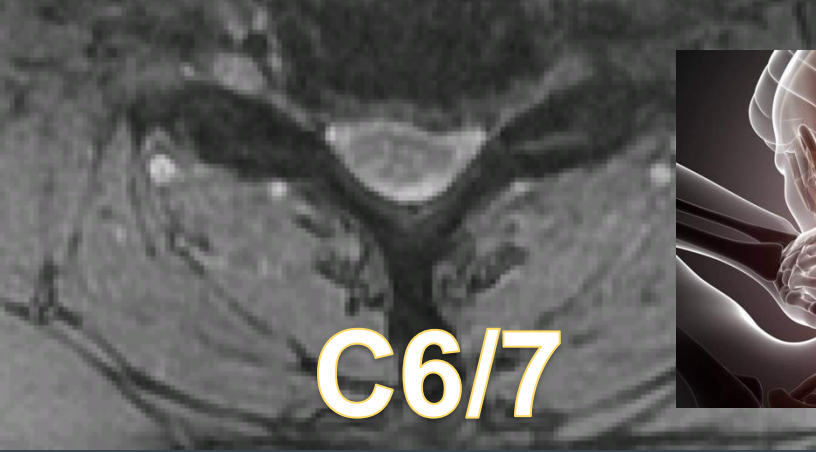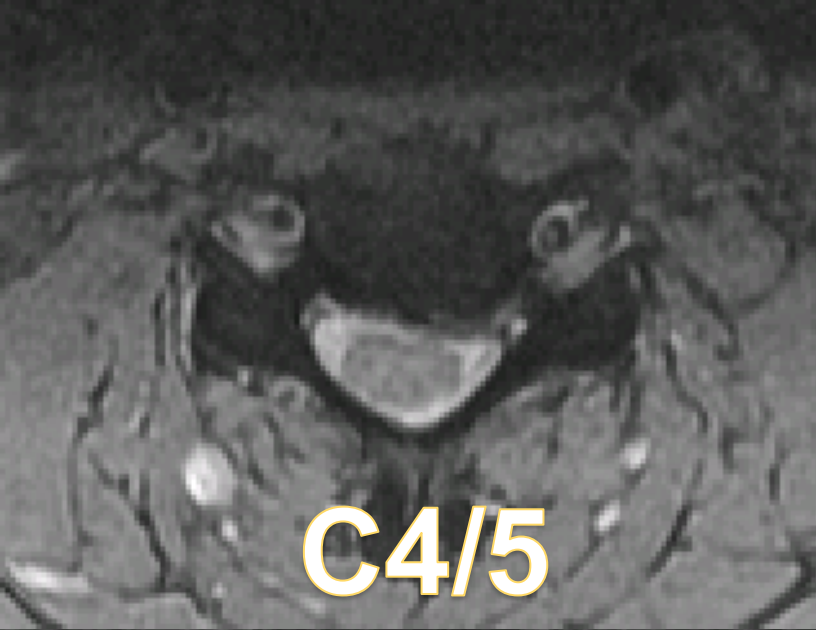


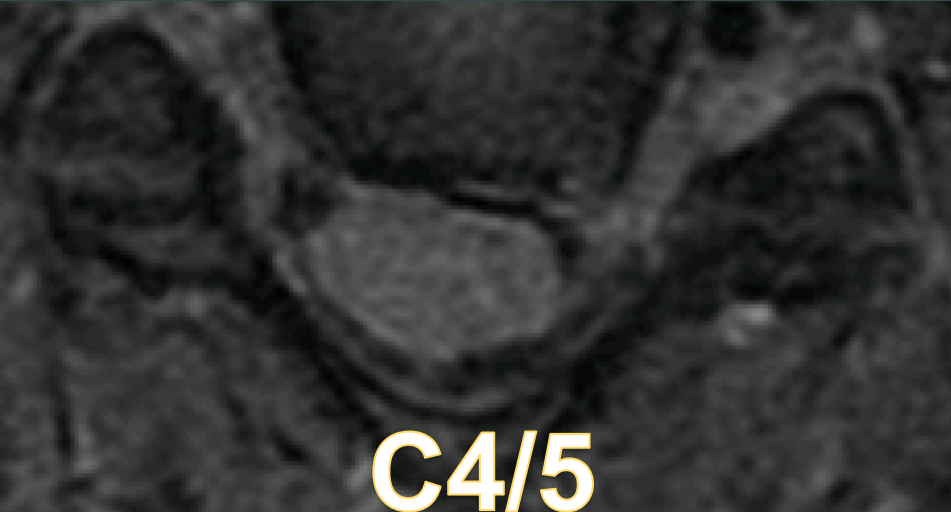







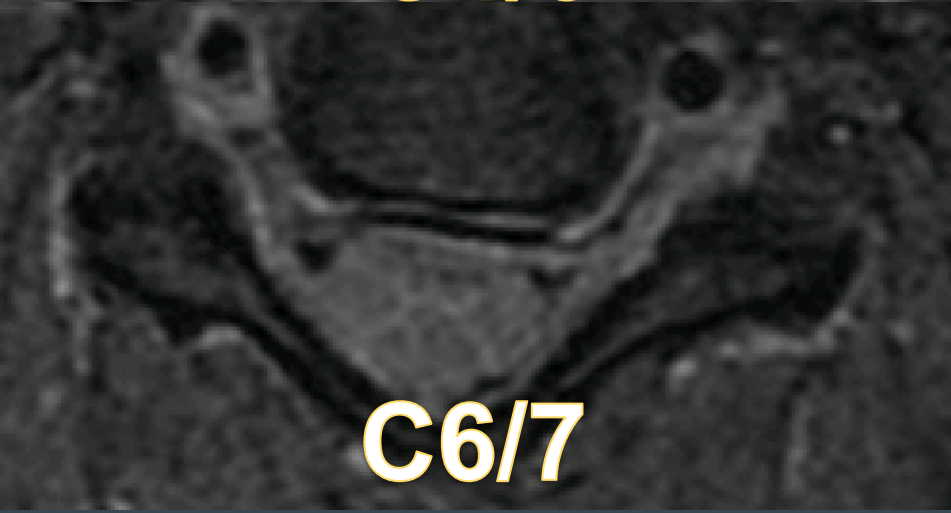




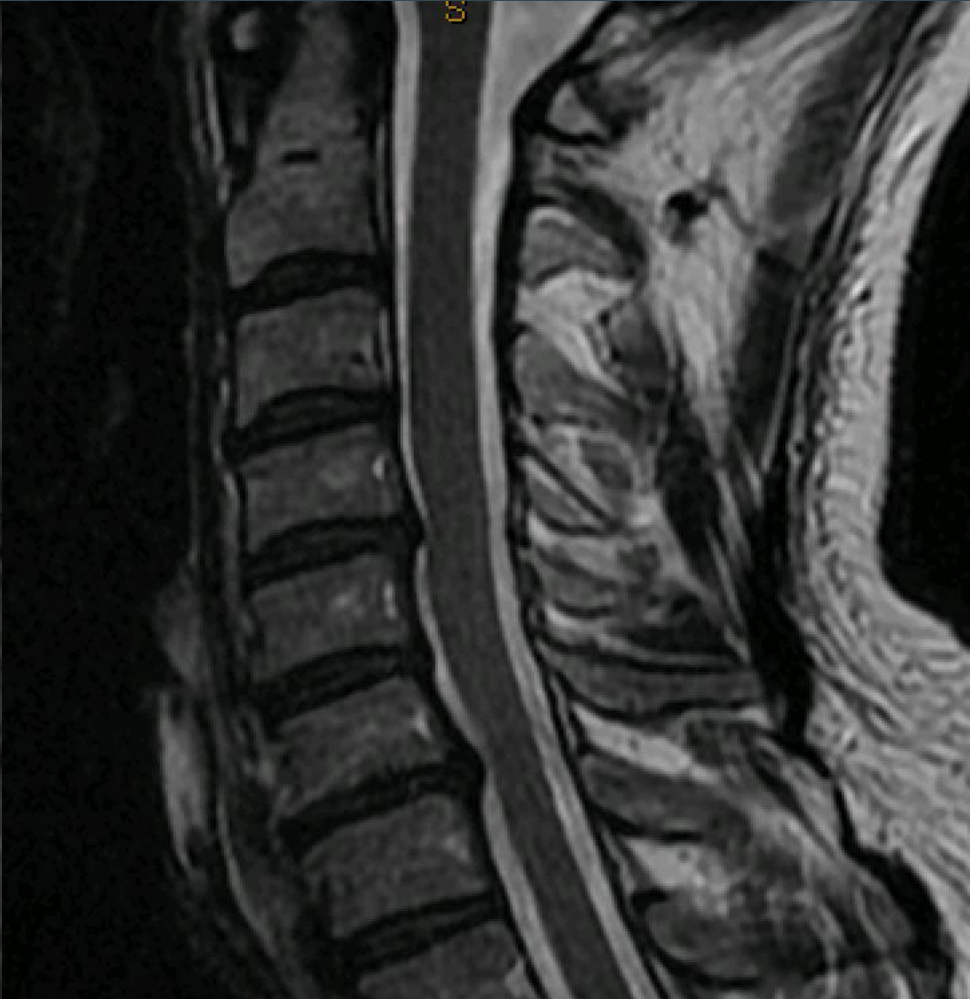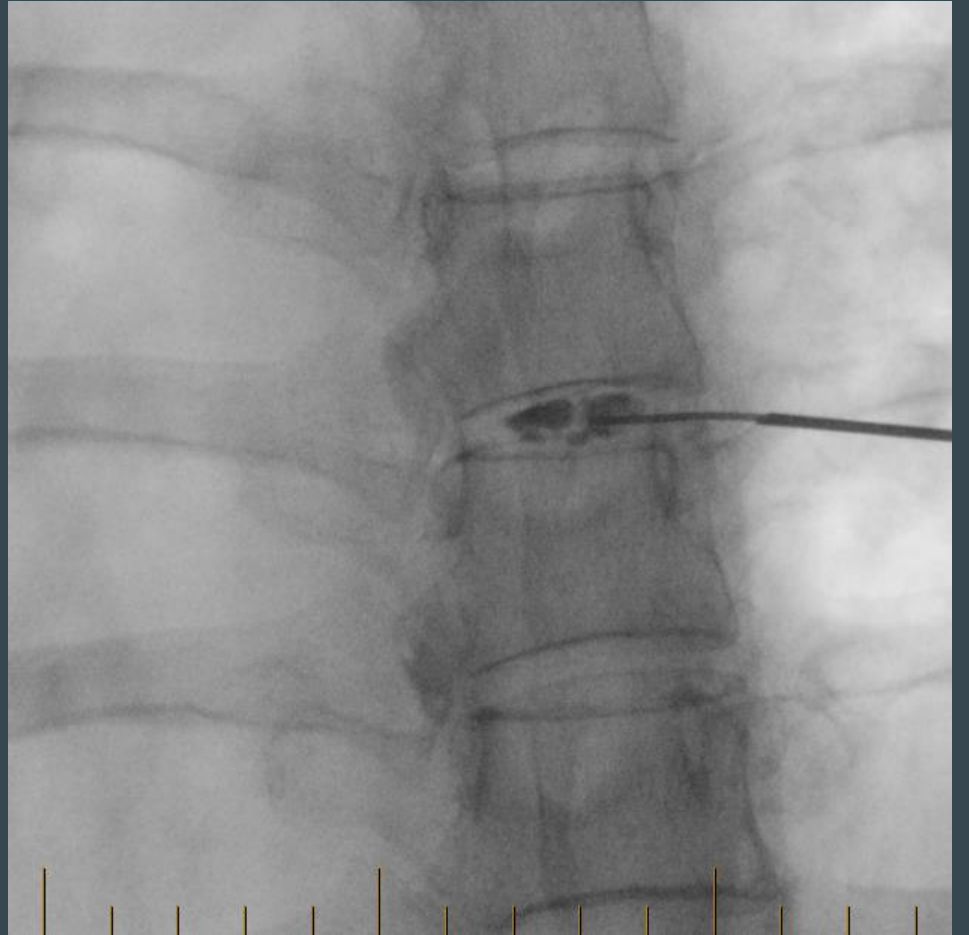
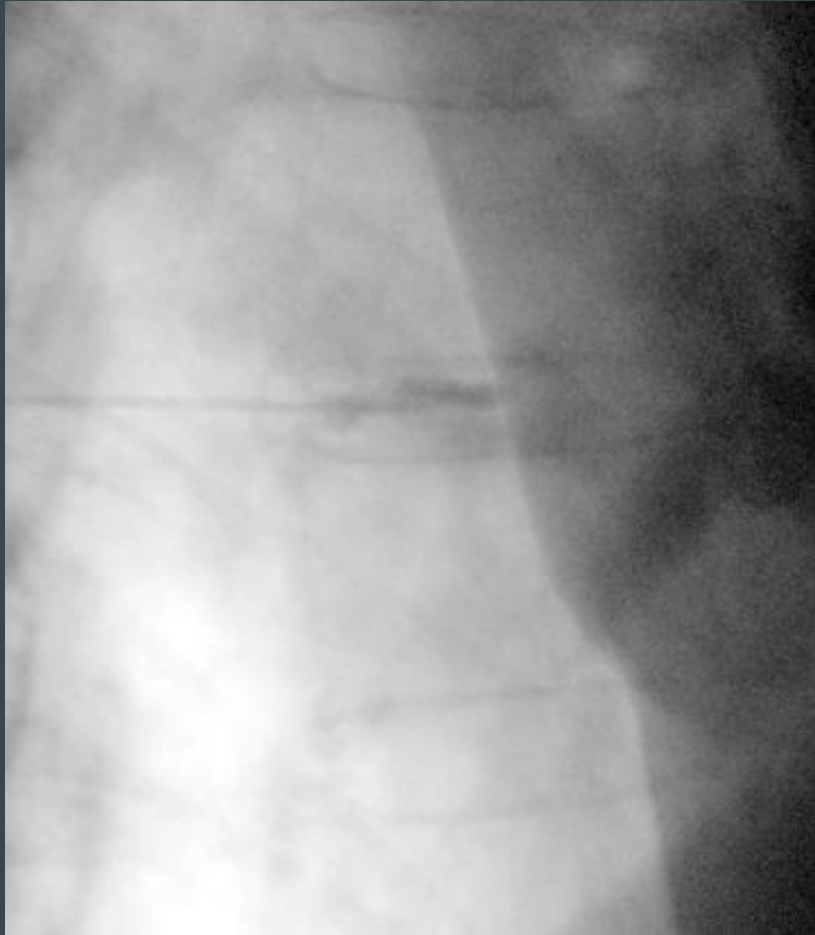
C4/5



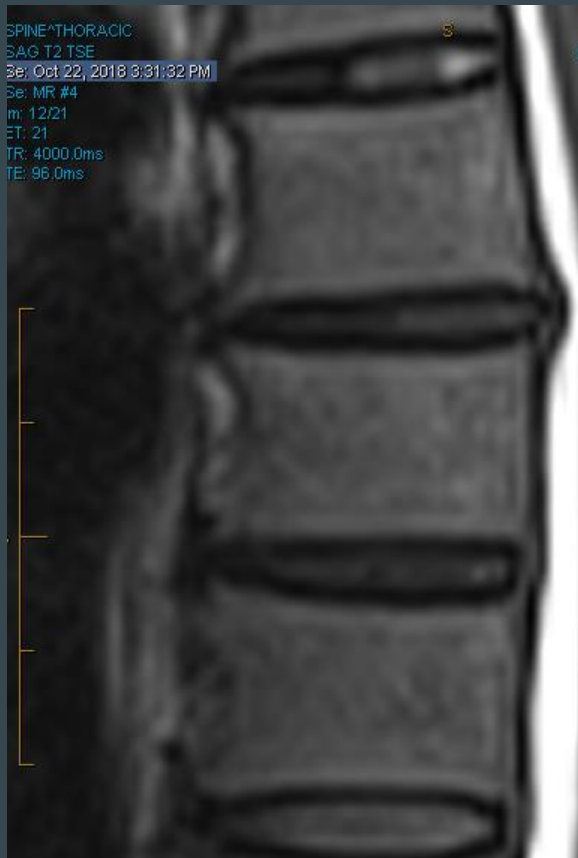C6/7



C6



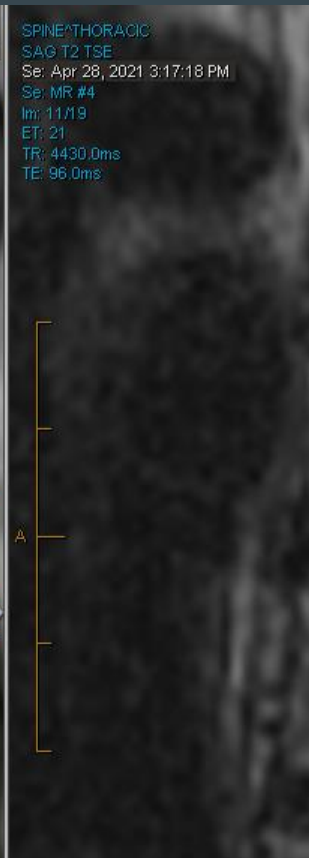
SPINE^THORACIC
SAG T2 TSE
Se: Oct 22, 2018 3:31:32 PM
Se: MR #4
In: 12/21
ET: 21
TR: 4000.0ms
TE: 96.0ms



Siker Imaging WEST
[MELISSA^MELISSA^M^L^W^B^H^U^T^T^]
[Jun 7, 1975]
[F][043Y]
[51504R3T]



SPINE^THORACIC
SAG T2 TSE
Se: Apr 28, 2021 3:17:18 PM
Se: MR #4
In: 11/19
ET: 21
TR: 4430.0ms
TE: 96.0ms



Siker Imaging
[SHAW^MELISSA^A^]
[Jun 7, 1975]
[F][043Y]
[51504R3T]

