



# Weil Foot & Ankle Institute

**Anthony H. Borrelli, D.P.M., FACFAS**



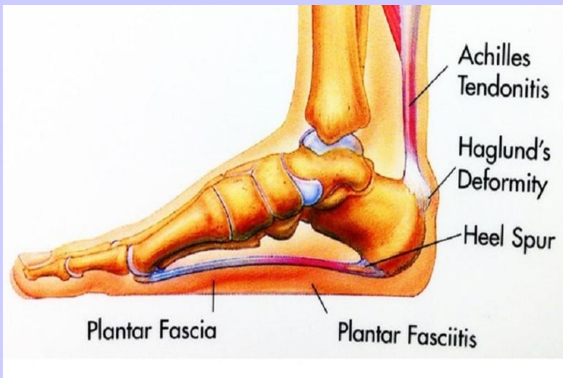
**The Incidence and Association  
of  
NEURITIS and PLANTAR FASCIITIS**

**Treatment Considerations**

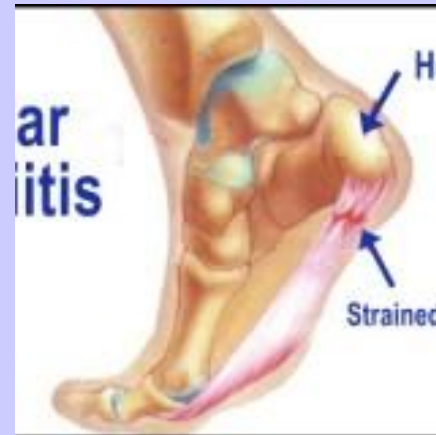**Anthony H. Borrelli, D.P.M., FACFAS**

# Plantar Fasciitis

- One of THE most common conditions seen by D.P.M. (nih 2024/10%)
- Pain to Longitudinal Band/Plantar Posterior of the heel
- Can have disabling pain levels; vas 8-10
- LIFE ALTERING

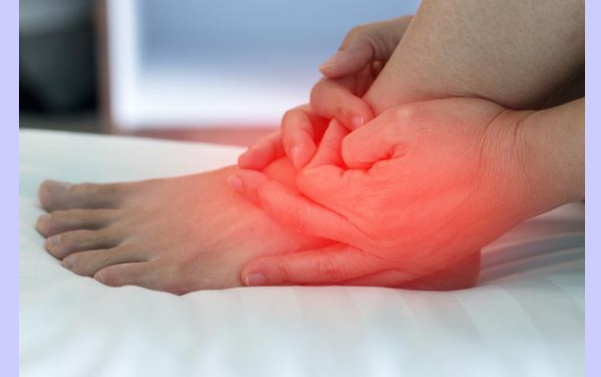

**Normal Presentation**  
**Thickness 3-5 mm**  
**MRI -Homogenous low signal**  
**Sonogram- Hyperechoic on**



Chronic overuse injury  
potentially due to  
Instability of the mid tarsal  
joint

# Overview of Plantar Fasciitis



- **Characterized by post static dyskinesia**
- **Often represented by SPURS on plantar surface calcaneus (Forman, Clin Pod 1990)**
- **Literature: With mechanical Treatment  $\approx$  60-85% success**
- **Literature: Low Neurological involvement**
- **THE INJURY IS CONSIDERED TO BE AN OVERLOAD INJURY**
- **BUT...**



**WHERE**

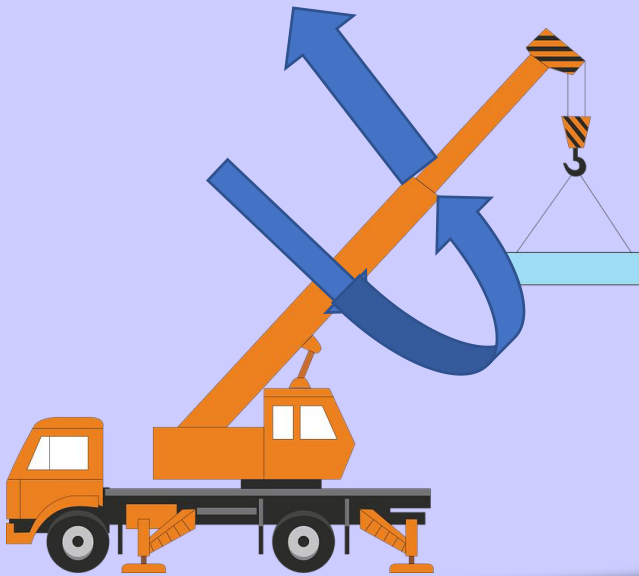
**DOES THE**



**OVERLOAD COME FROM????**

# MTJ - Tri Plane Axis

- **Movement in three planes - triplane**
- **More movement in plane furthest from axis**
- **Therefore, most movement in sagittal and transverse planes**
- **Forefoot locks on the rearfoot with FF loading**

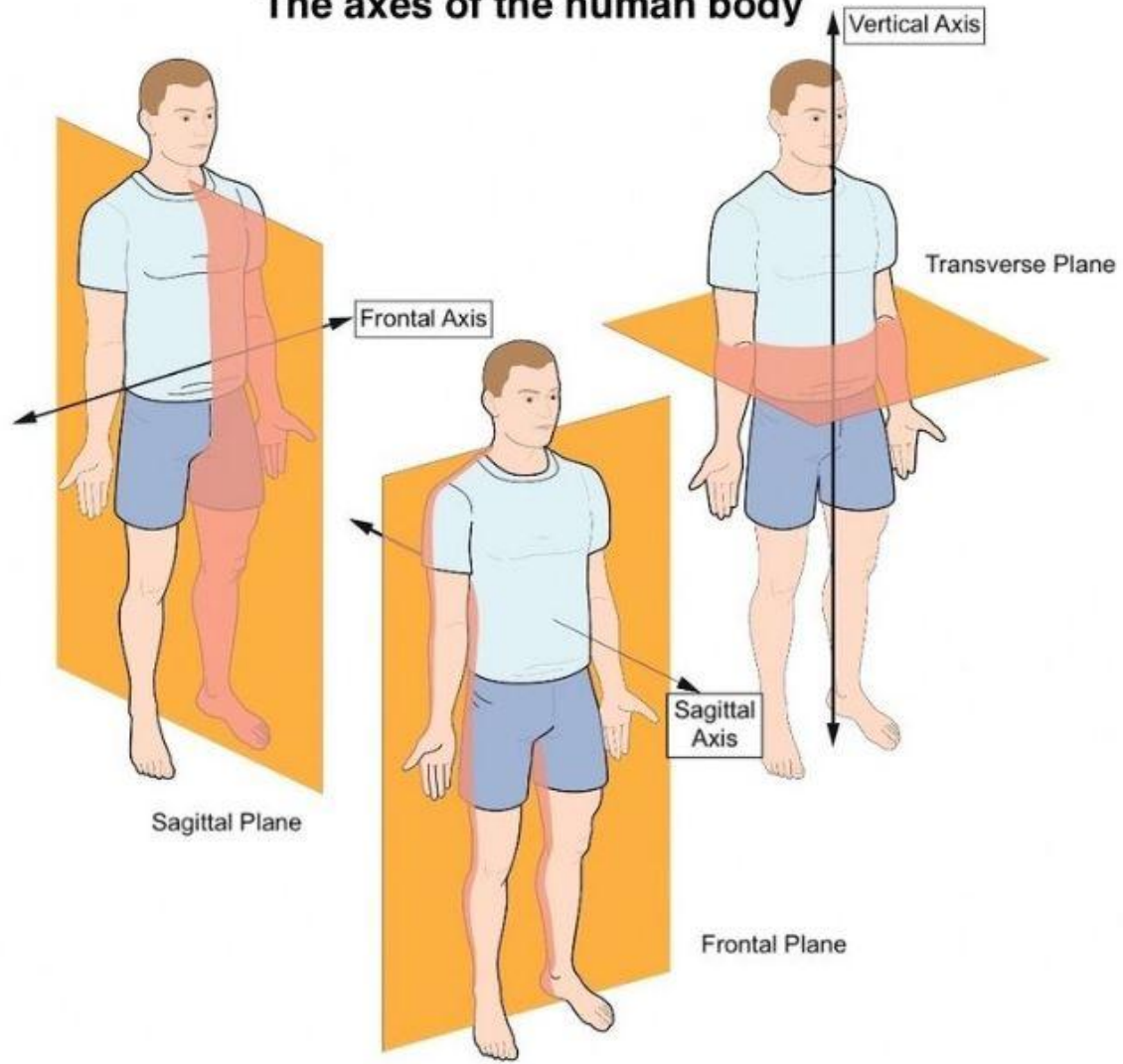


**OMTJA**

**52 deg from TRANSVERSE—movement in TRANSVERSE**

**57 degrees from SAGITTAL—movement in SAGITTAL**

## The axes of the human body

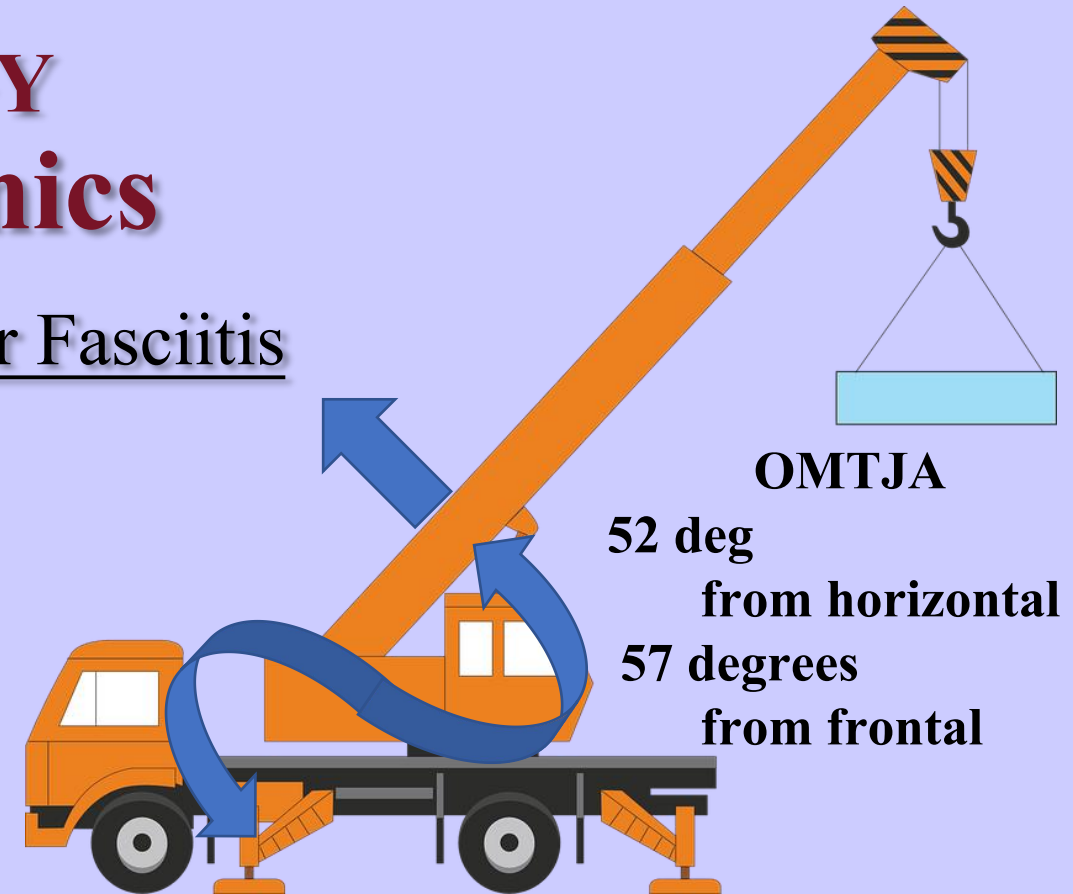


# Cardinal Body planes

# ETIOLOGY

## Biomechanics

- No locking of the MTJ in diagnosis of Plantar Fasciitis
- Lack of locking indicates MTJ instability
- Increased sagittal plane load overwhelms the primary restraints of bone-to-bone articulation and secondary constraints of soft tissue , notably the PLANTAR FASCIA
- Can only occur if the **oblique MTJ axis is HORIZONTAL** producing increased motion in the SAGITTAL PLANE



# **Etiology**

## **OMTJA - Horizontal Axis**

- **Axis more horizontal, more sagittal motion allowed**
- **Evidence - NO locking MTJ /459 study patients**
- **No inherent osseous restraint**
- **Increased weight/strain on primary osseous constraints**
- **Soft tissue strain**

# Mid Tarsal Joint


- True of all joints: greatest motion in a plane is when axis is 90° away
- Horizontal axis = sagittal motion; sagittal axis = frontal motion; frontal axis = horizontal motion
- Longitudinal axis FLAT, frontal plane motion, 9 sagittal, 15 horizontal
- Oblique axis, motion in transverse and horizontal, 57 sag, 52 horizontal
- Primary constraint, aka, Locking joint
- Articular surfaces are irregular and motion stops, subluxation
- If oblique axis more horizontal, then, more motion in sagittal
- Lack of primary constraints, increased force...
- **OVERLOAD**

# Etiology

## OMTJA - Horizontal Axis

- Secondary Soft Tissue must support primary osseous constraints
- PF parallel to axis of motion MTJ / crosses MTJ
- Plantar Fascia major support MTJ
- Overload force leads to soft tissue injury to Plantar Fasciitis

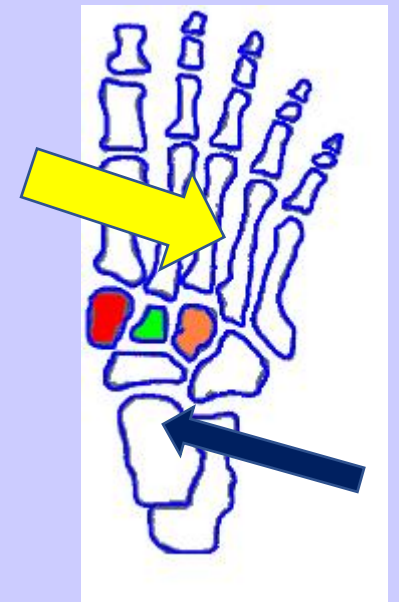
# Vertical Oriented Axis



**Axis of motion – vertical**  
**Plane of motion – Horizontal**

**Movement in Horizontal Plane**  
**develops Pes Planus**

**Root et al, 1977, page 43**



This Photo by Unknown  
Author is licensed under  
[CC BY-SA-NC](#)

This Photo by Unknown Author is licensed under [CC BY-NC-ND](#)

# Horizontal Oriented Axis



This Photo by Unknown Author is licensed under [CC BY-SA-NC](#)

## Sagittal Plane Movement

# PAIN - Plantar Fasciitis - Etiology

- Primarily seen as a MECHANICAL overload injury

- \* **Acute**

- \* **Chronic**

**BUT .....**

- Heel pain may also present as a result of having :

- METABOLIC etiology

- NEUROLOGICAL etiology

- Can two or more occur CONCURRENTLY?

# Clinical Findings - SAMPLE

- Post static dyskinesia
- Pain intensity varies
- Pain gets worse over time
- Fasciiosis? end point of damage
- Sub Tuberosity edema? = PERIOSTITIS, (bursa ?)
- Clinical finding of NO LOCKING MIDTARSAL JOINT

# Evaluation - Plantar Fasciitis

**X-rays**

**Sonogram**

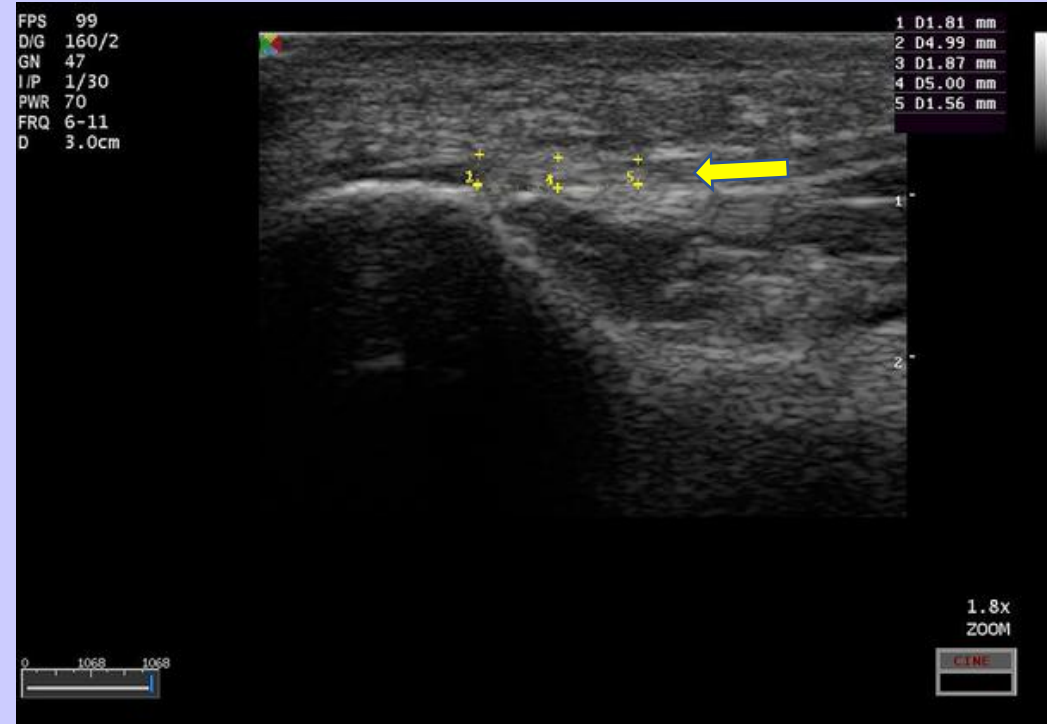
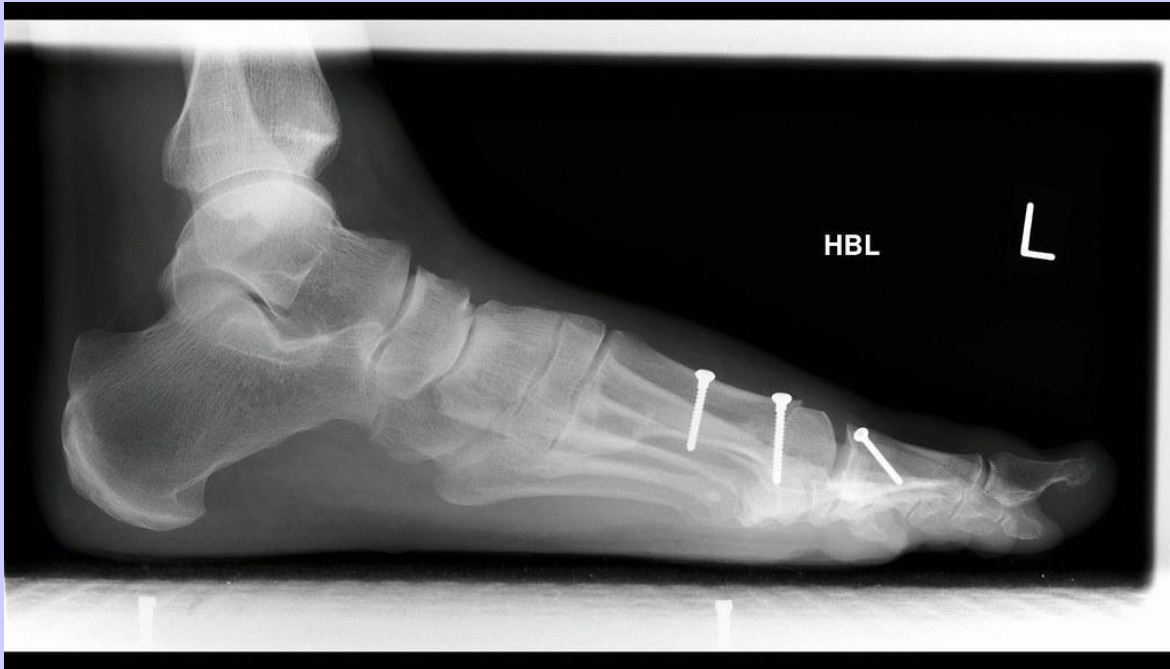**CT scan**

**MRI★**

★ *Only study that can provide actual tissue constitution*

# Evaluation Plantar Fasciitis

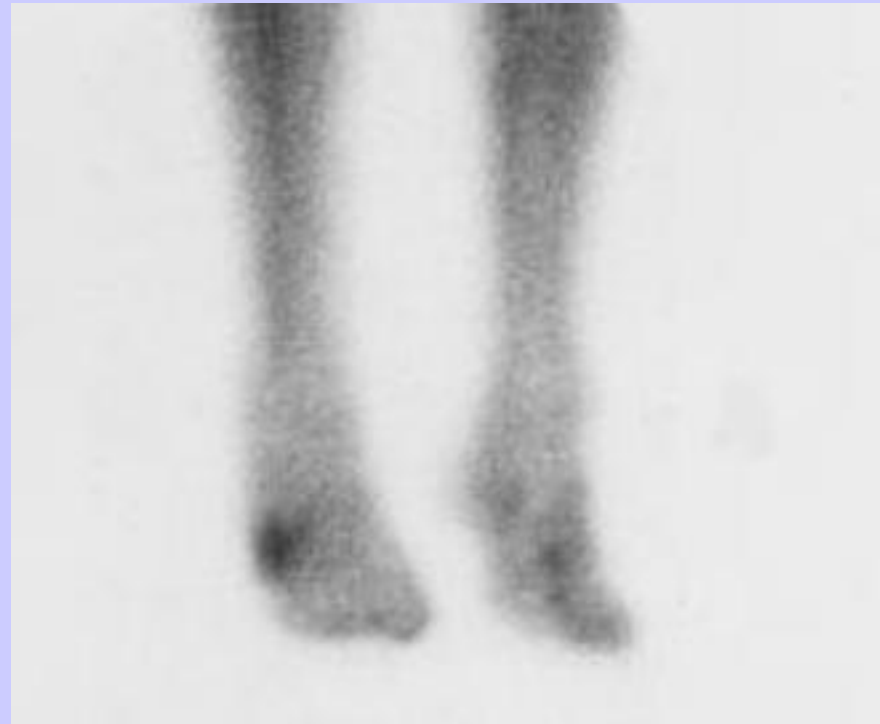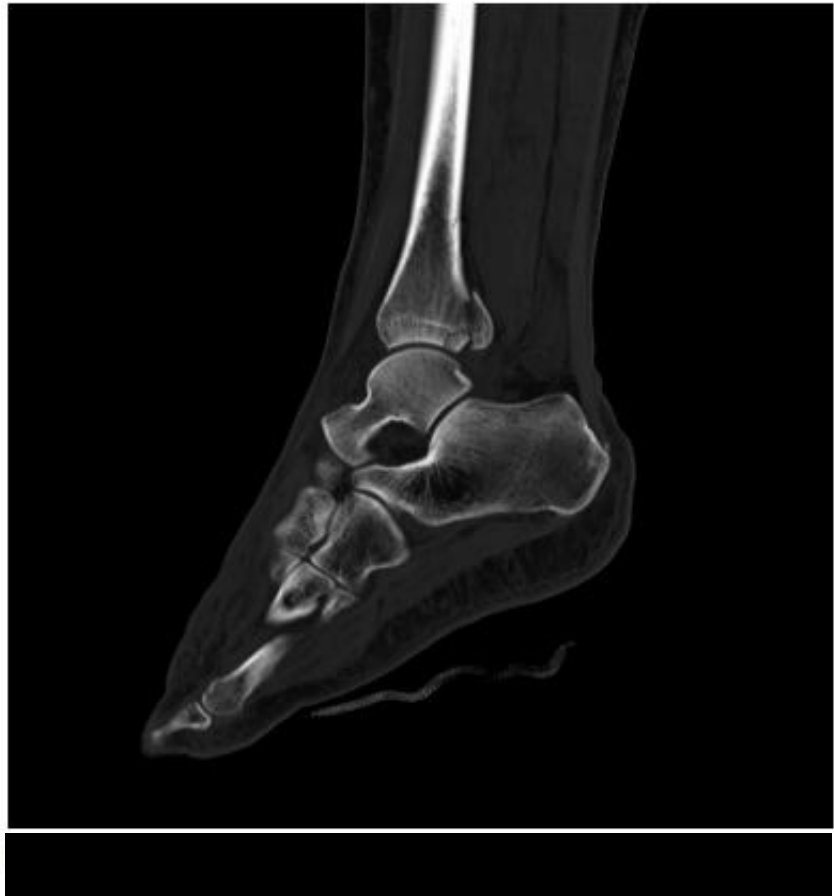## X-Ray - - / - - Sonogram

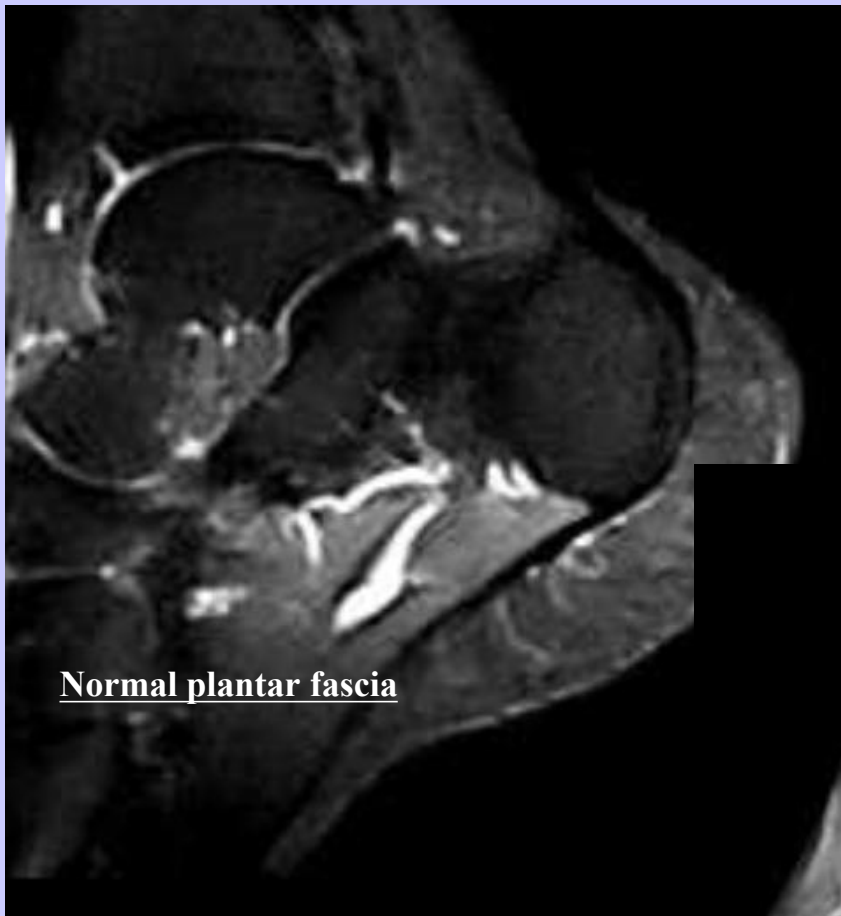

This Photo by Unknown Author is licensed under [CC BY-NC](https://creativecommons.org/licenses/by-nc/4.0/)

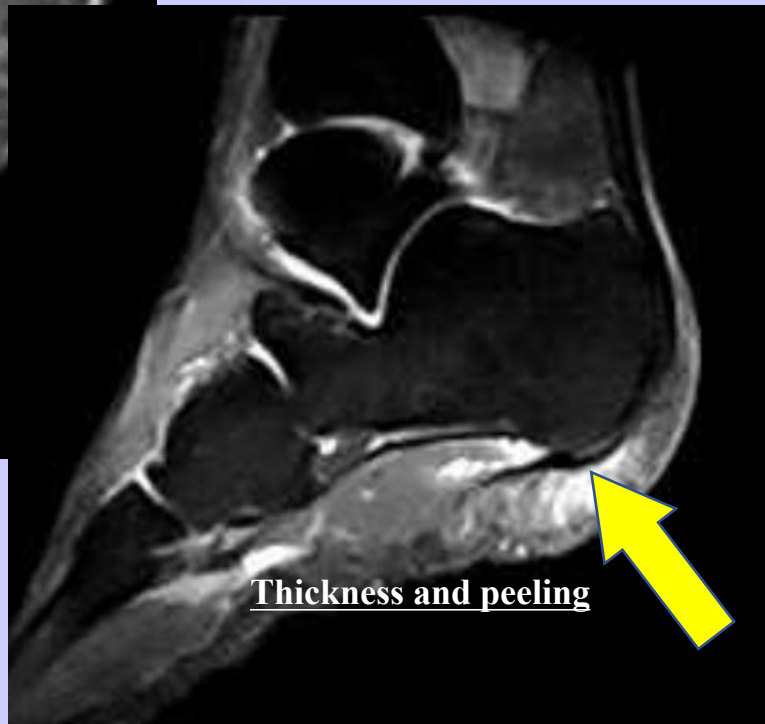# Evaluation Plantar Fasciitis

## CT scan / 3 Phase Bone Scan

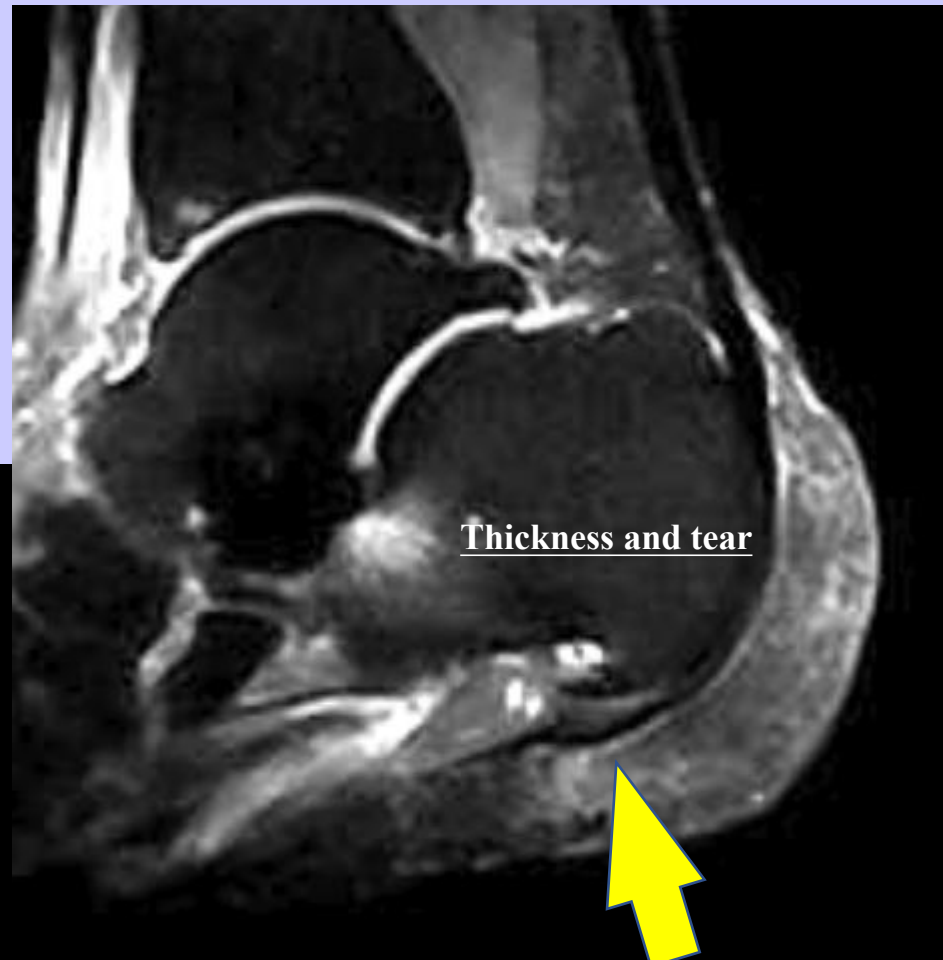



Normal plantar fascia



Thickness and peeling

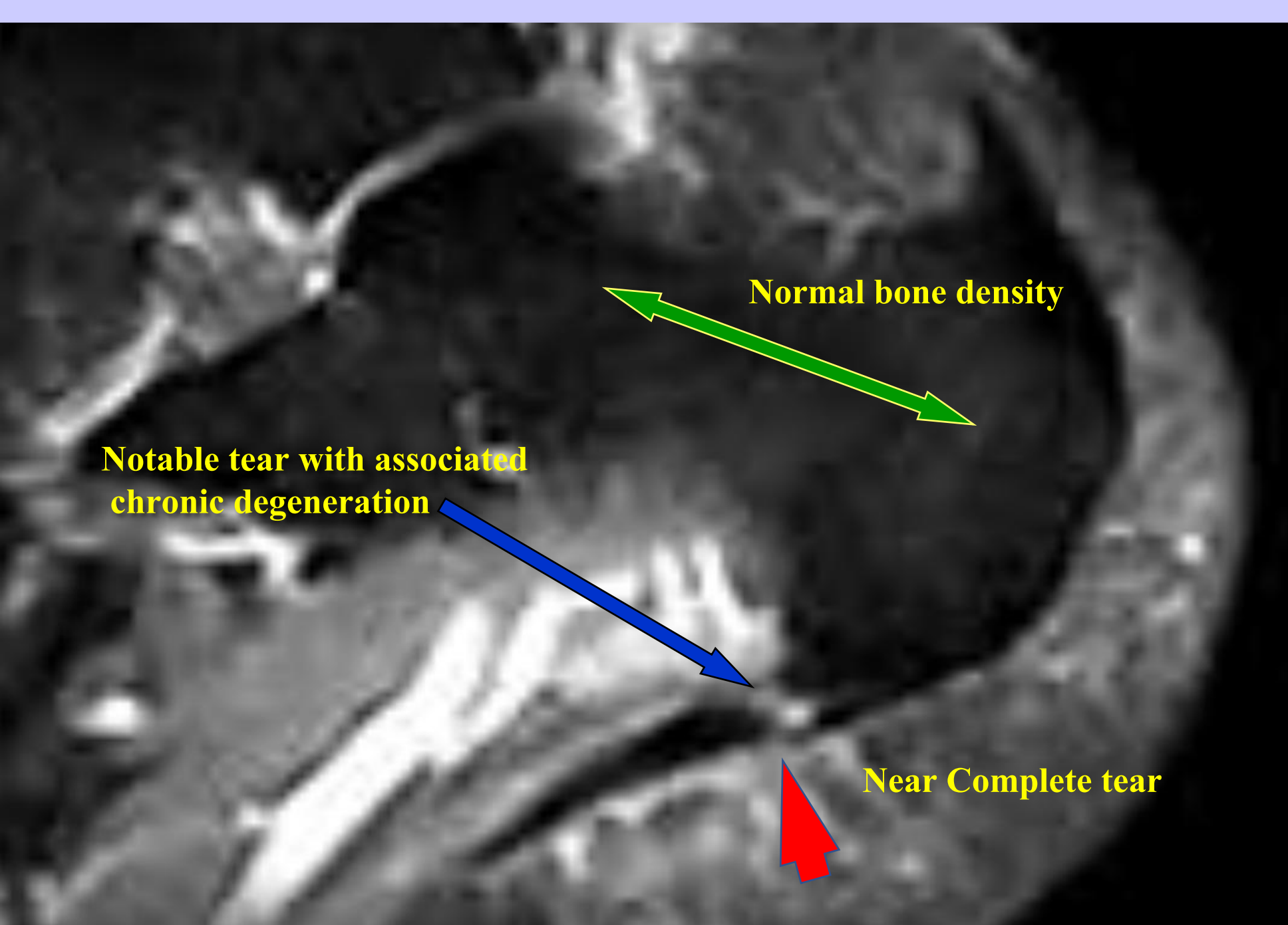


Thickness and tear

**MRI Study  
Sagittal Stir**

**Chronic  
Degeneration with  
near complete tear**

**Normal thickness  
and density**



**Normal bone density**

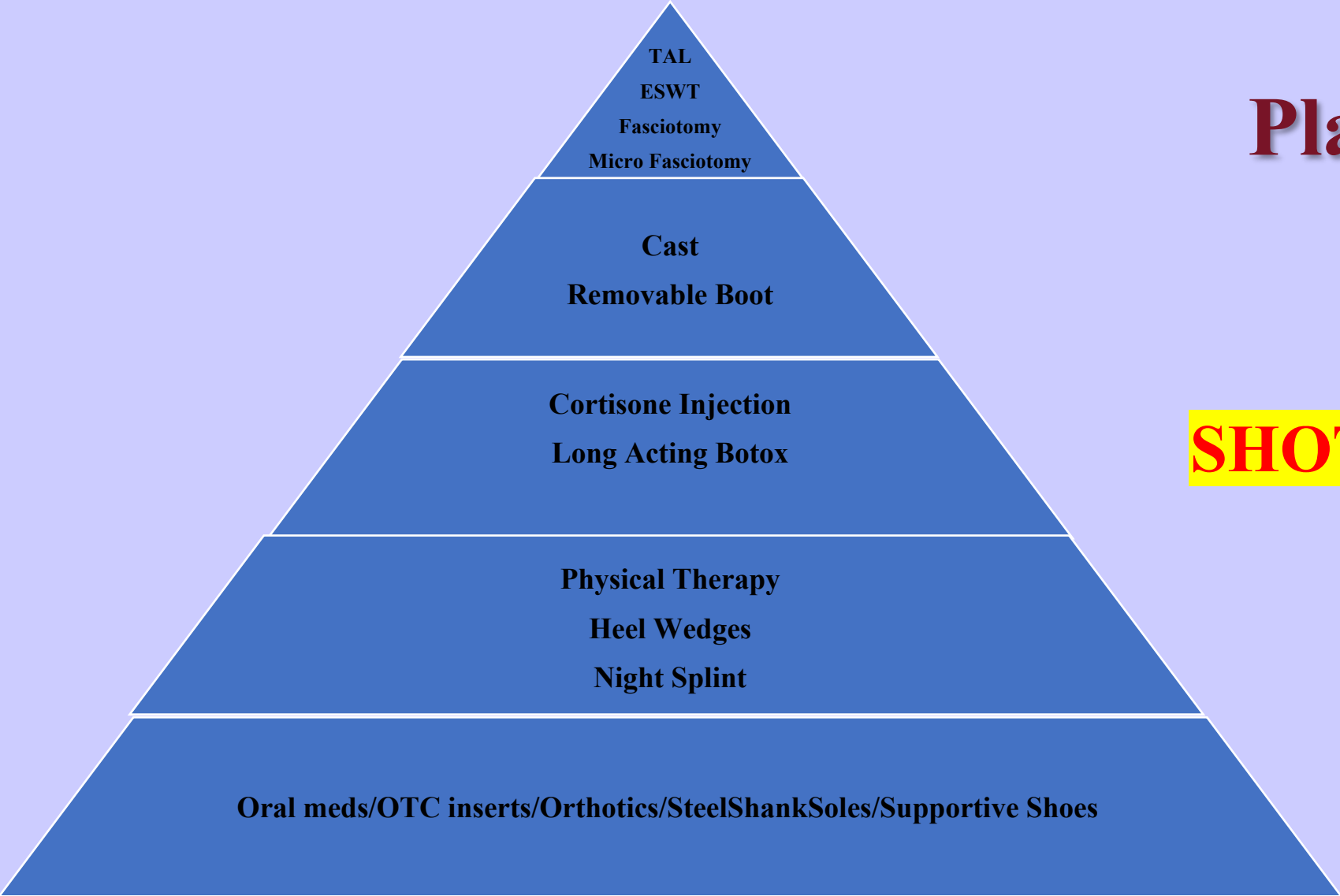
**Notable tear with associated chronic degeneration**

**Near Complete tear**

# Plantar Fasciitis Treatment

**SHOTGUN APPROACH**

**BUT...**



# •WHAT IS BEING TREATED?



# •HOW DO YOU KNOW WHAT IS WORKING?

# Plantar Fasciitis Clinical Evaluation

**Metabolic Pain** – admittedly rare

**Mechanical Pain**

**Post static dyskinesia**

**Morning pain that improves with activity**



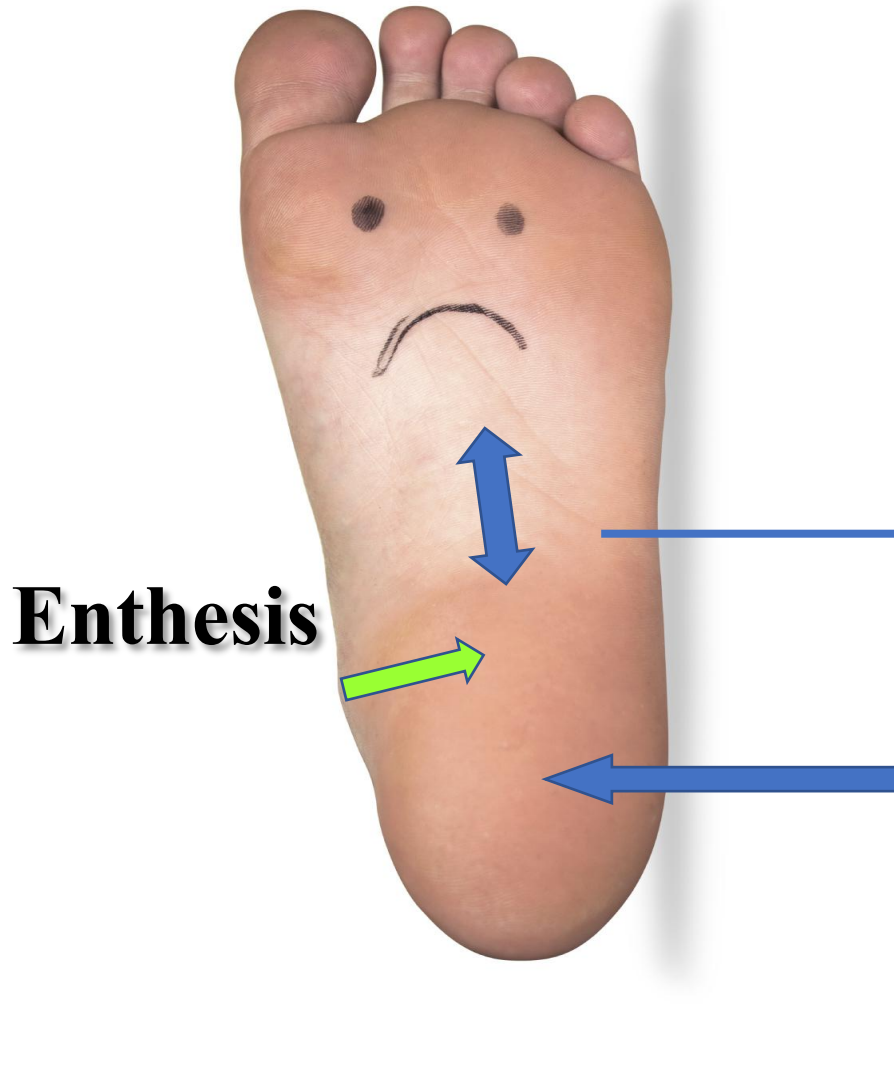
**Neurological Pain**

**Burning pain / Pain at rest / Ill defined pain**

# Mechanical Pain

- **Most notably under the tuberosity of the calcaneus**
- **Edema may or may not be present**
- **No clinical or surgical evidence of BURSA**
- **Periostitis noted by side to side compression**
- **Pain to the enthesis may/may not be nerve related**

# Plantar Fascia Anatomic Markers



**Longitudinal Band**

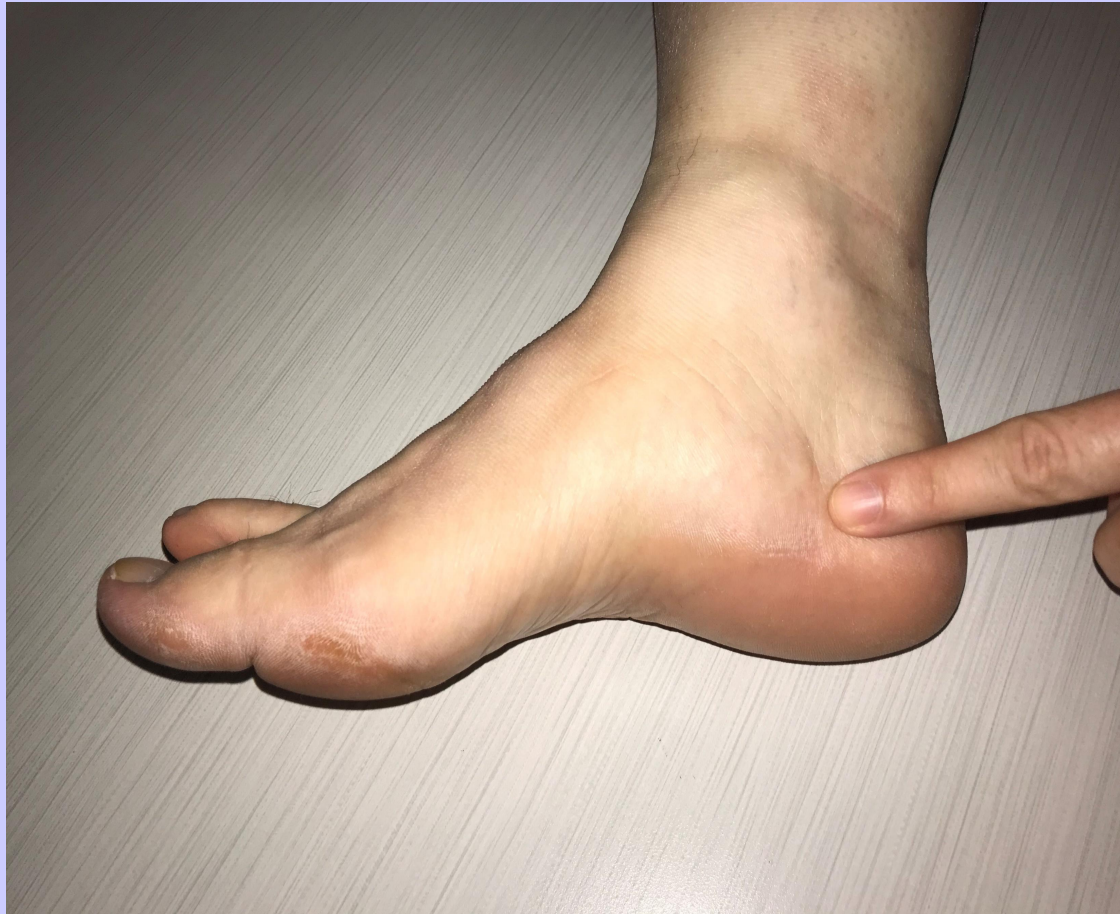**Enthesis**

**Sub Tuberosity**

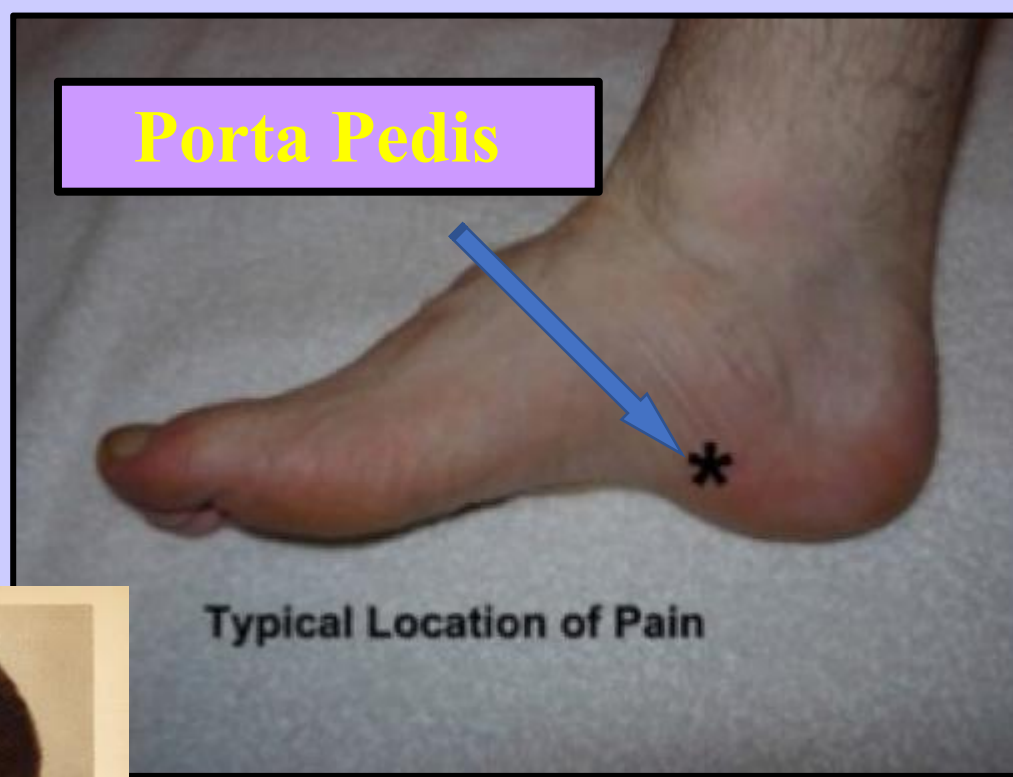
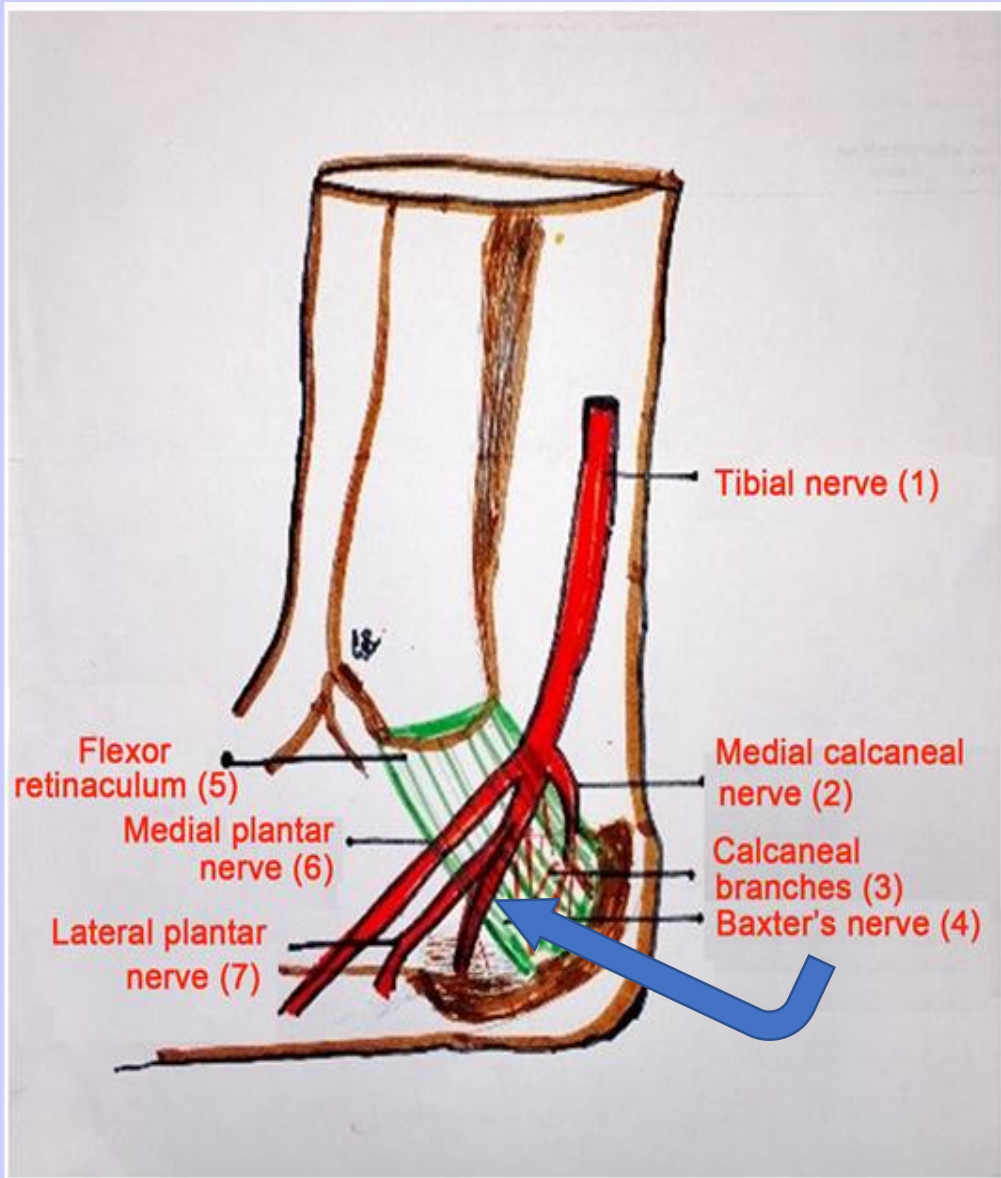
# Neurological pain

- ***NEUROLOGICAL INNERVATION of the plantar of the heel is via post. tibial nerve and its respective branches***
- **Clinical, Pain over tarsal canal w/wo radiation to plantar**
- **Clinical, Pain over porta pedis w/wo radiation to plantar**
- **Can also be induced via referred pain from back/dx of suspicion**
- **Pain at rest, night pain, shooting/burning pain**
- ***Baxter's nerve involvement.....***

# Porta Pedis

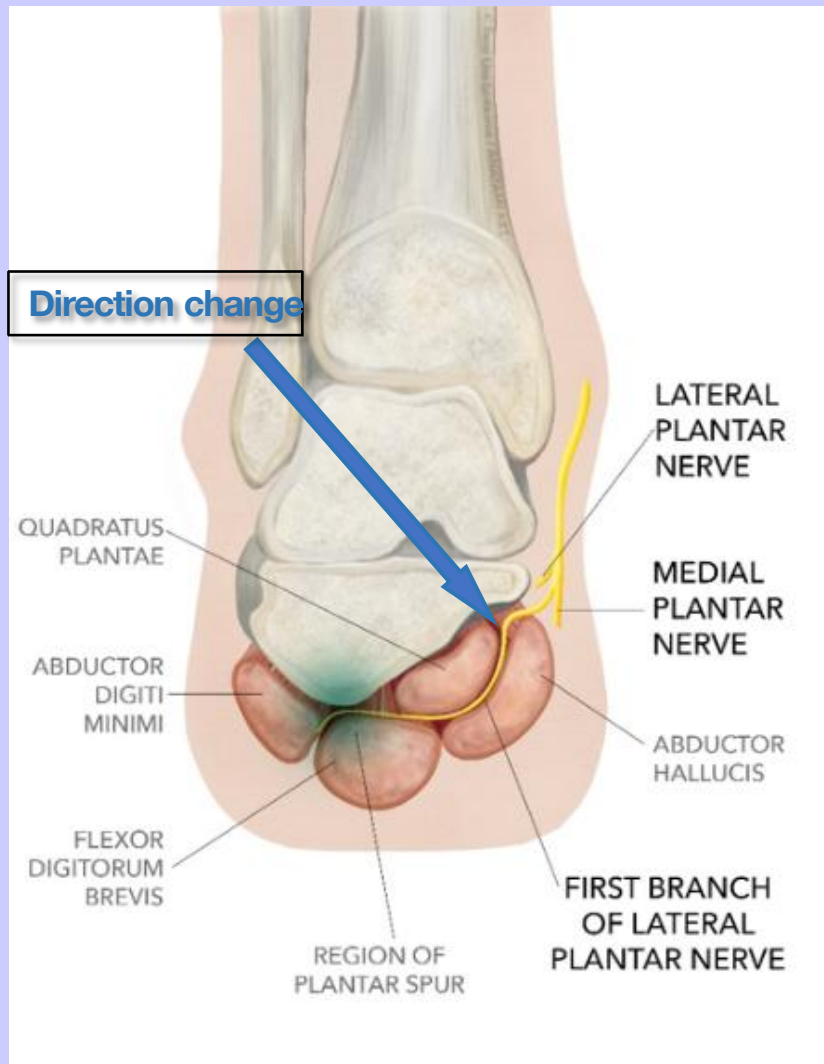


**Neurological pain**

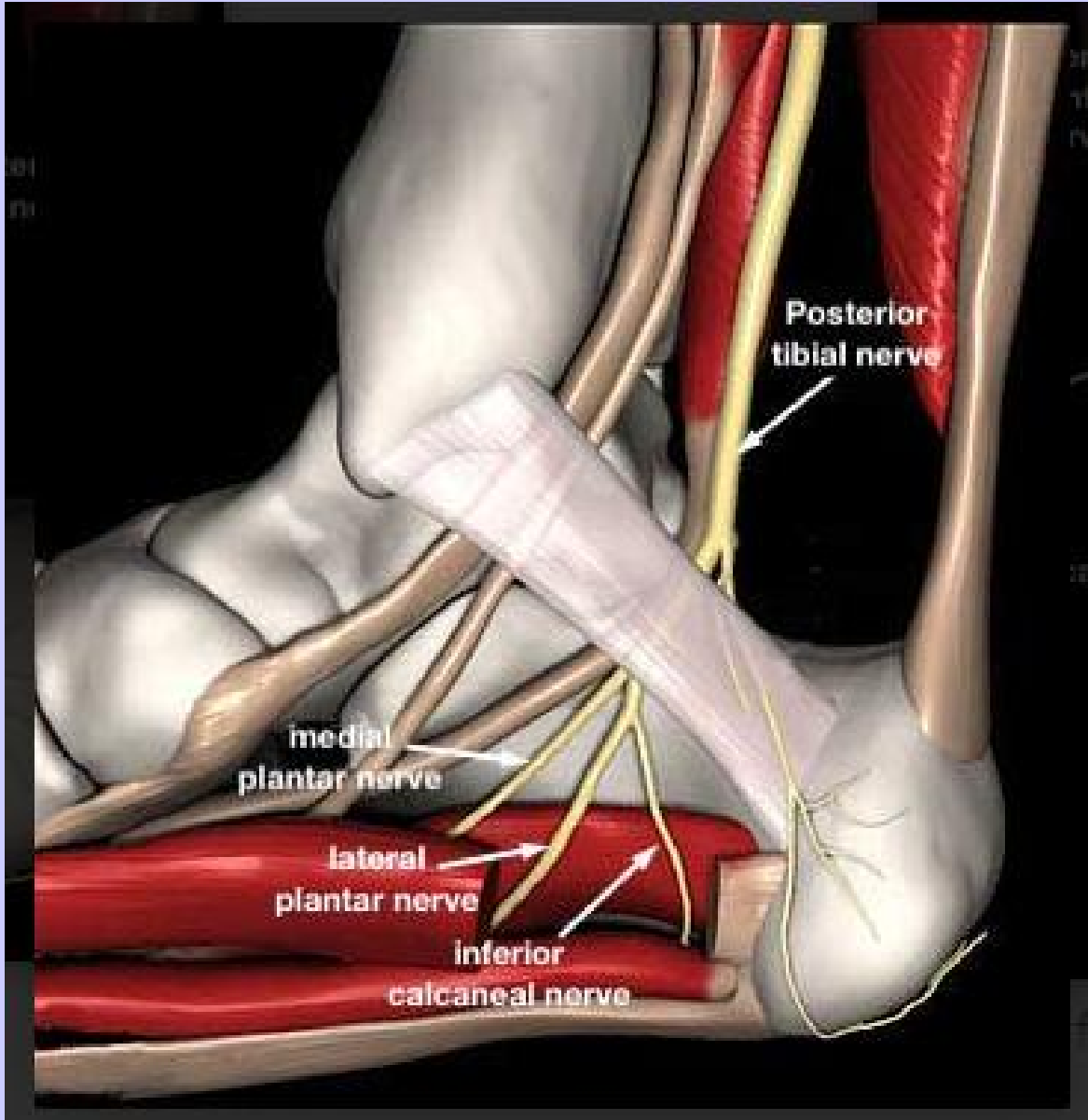


THIS IS  
 NOT Dr.  
 Baxter

# Baxter's Nerve



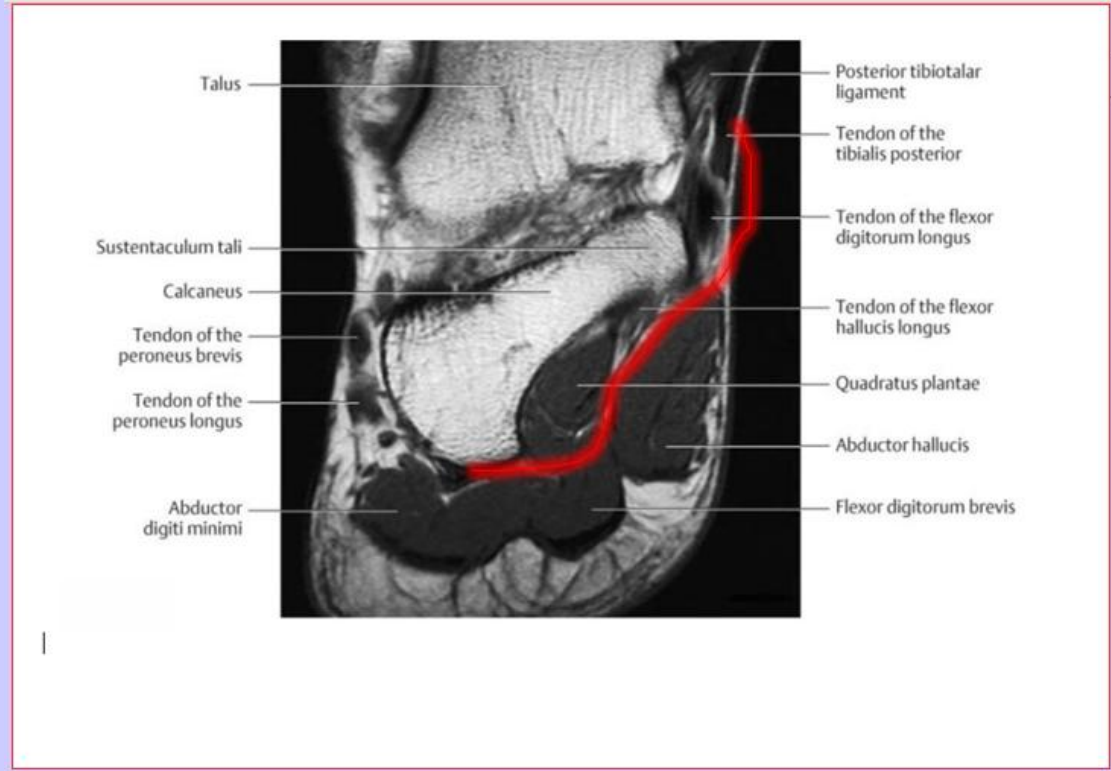
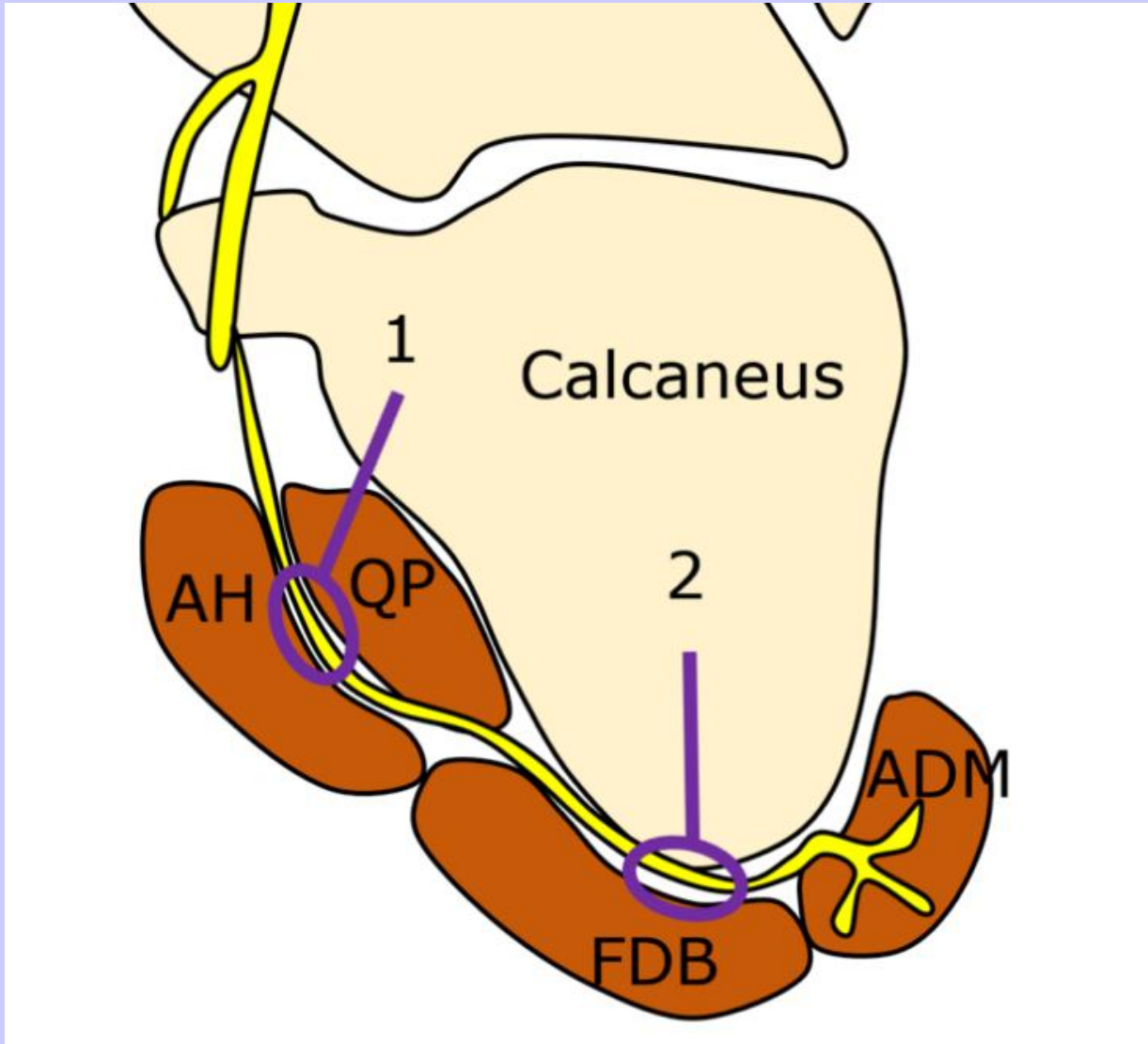
- Baxter/Thigpen, Foot Ankle, 1984. 5; 16-25
- Motor branch to the Abductor Digiti Minimi
- 82% of time first branch of Lateral Plantar Nerve
- Motor fibers to Quadratus Plantae, FDB, ADM
- Sensory branch to Calcaneal periosteum and long plantar ligament.

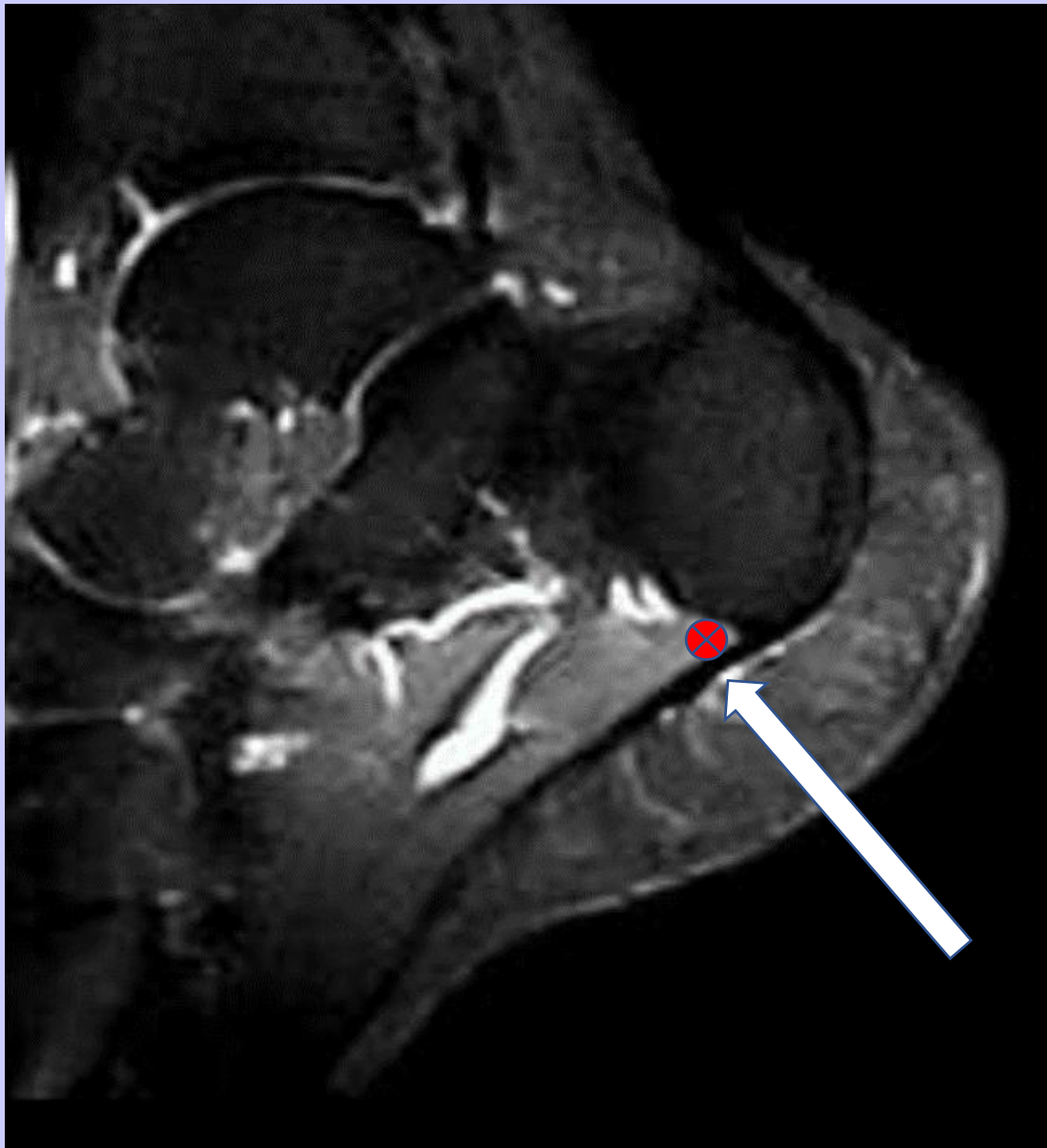

**Deep to Abductor Hallucis the nerve dives and turns**

**Most likely to have compression at this location**

**★ *In Tarsal Tunnel surgery I now transect the proximal muscle fibers of the Abductor Hallucis along with the most medial fibers of the plantar fascia***



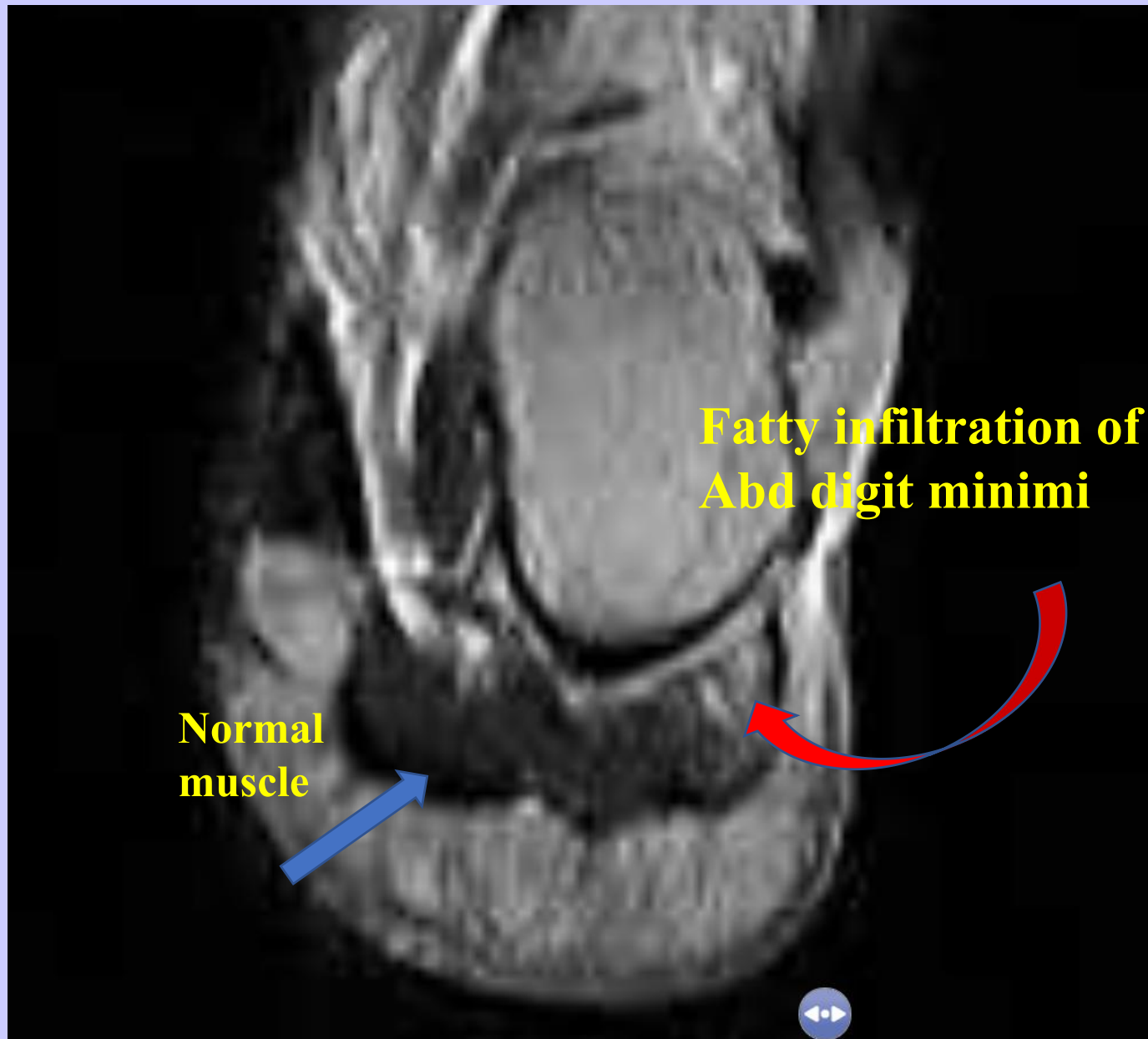


**Location of  
Baxter's nerve**

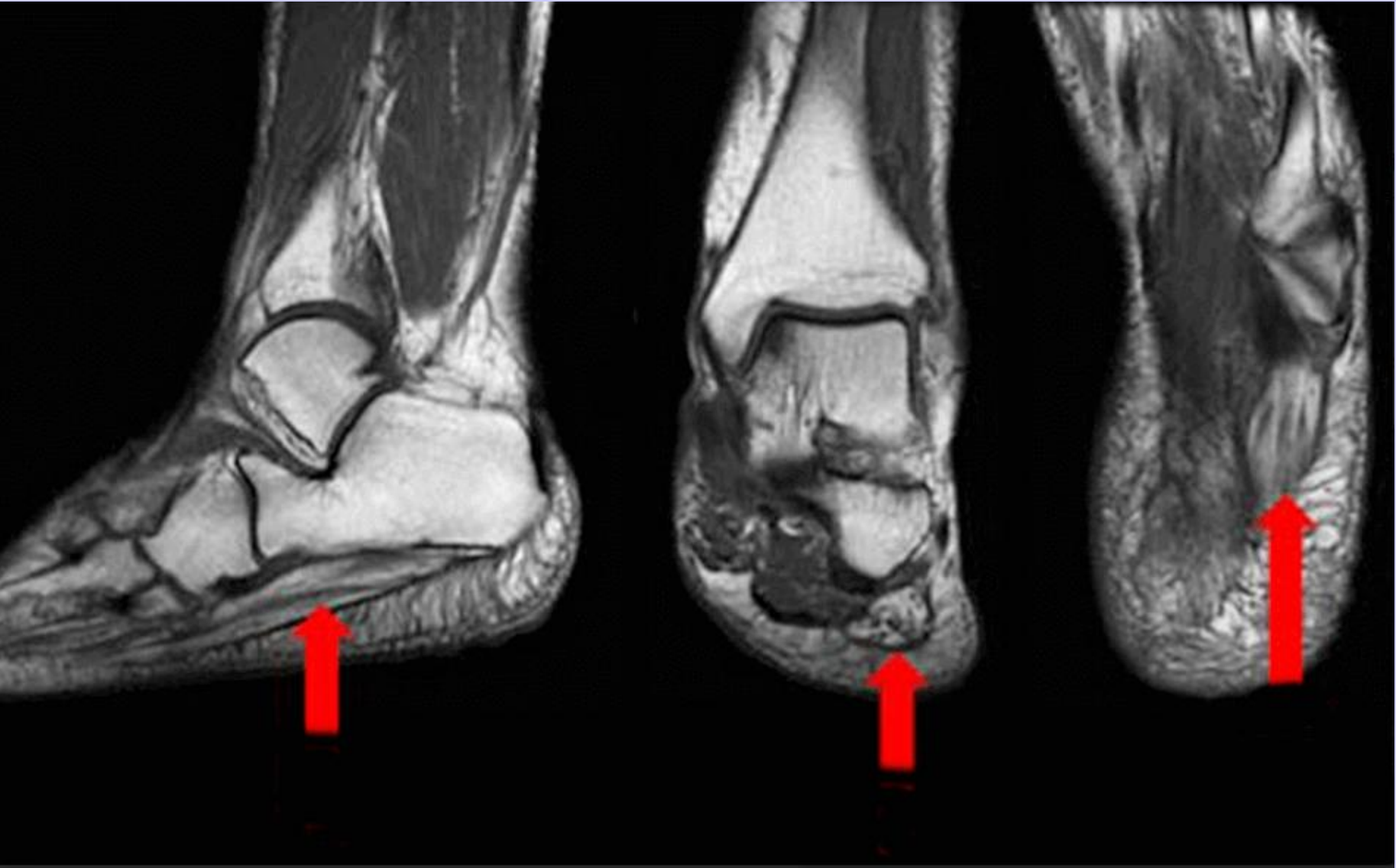# MRI findings of Neurological Entrapment

- **The Abd. Digiti Minimi is the motor endpoint of Baxter's nerve**
- **Alteration of conductivity of the nerve will induce changes to the end point muscle.**
- **Findings include:**
  - **Fatty infiltration**
  - **Muscle wasting**

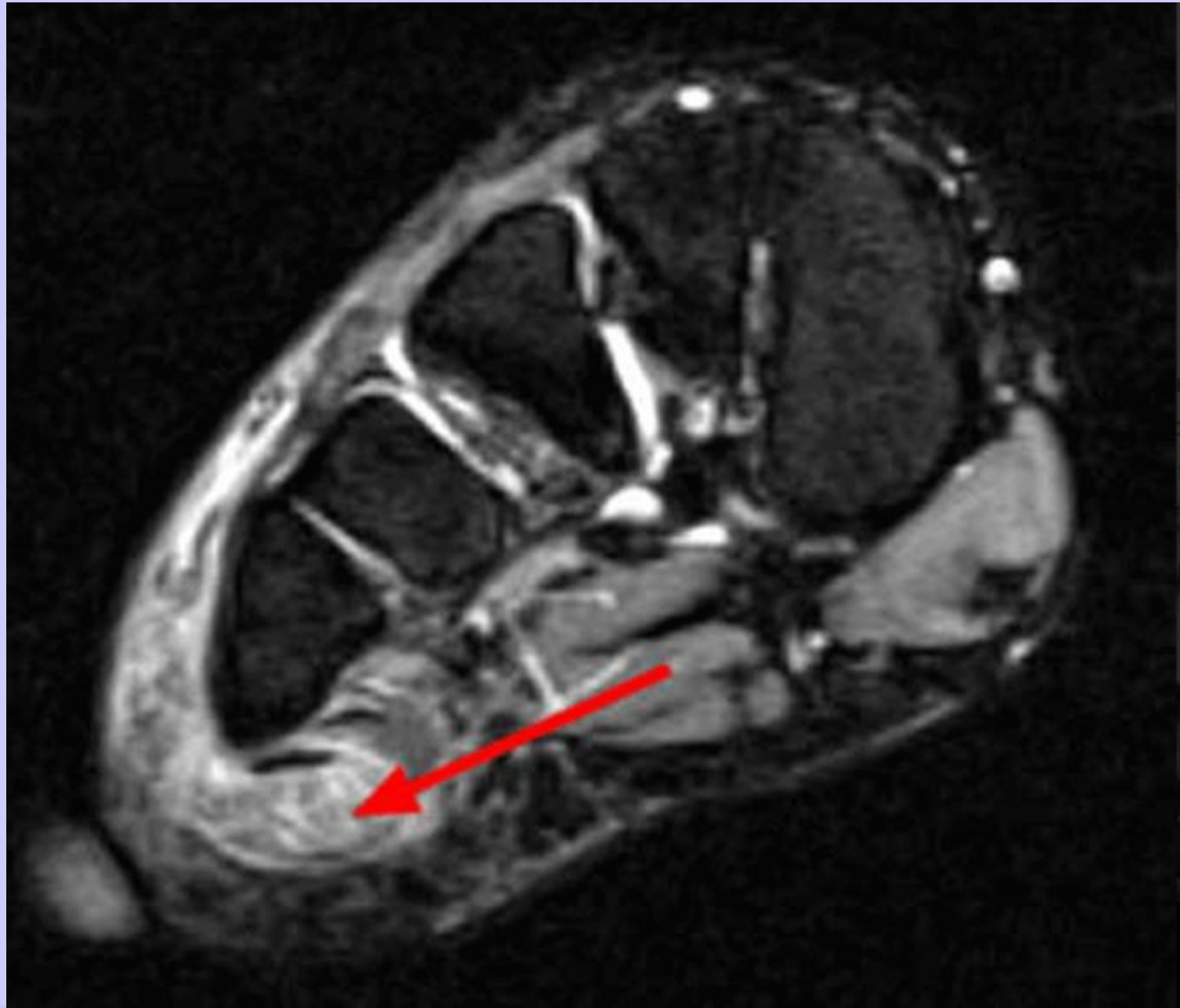
**MRI study  
Coronal T-2**



;  
N  
o  
r



changes from chronic Baxter's neuritis



**Significant  
Fatty  
infiltration  
noted**

## **MRI Evidence of Neuritis Incidence**

**Separate study by this author of 102 MRI**

**8 of 102 had Radiologist comments of signs of  
fatty infiltration or wasting**

**7.8%**

# Plantar Fasciitis

Novel Study of Neurological Involvement

# Scope of Study Terms

- 459 patient's chart review over three (3) yrs.
- Single examiner to prevent treatment bias
- All patients with initial diagnosis of plantar fasciitis
- Resolution defined as FULL and 100% pain free on both CC and exam

# Plantar Fasciitis Definitions

Plantar Fasciitis defined as:

**pain to the longitudinal band**  
**pain to the sub tuberosity**

Neurological pain defined as:

**Pain to the tarsal canal**  
**Pain to the porta pedis**  
**Radiating / non-radiating pain from the back**  
**Associated trans-enthesis pain**

# Incidence of Neuritis

**TOTAL PATIENTS**  
**459**  
All with dx of Plantar  
Fasciitis

225 of 459  
**49%**  
Plantar Fasciitis and  
Tarsal Canal and/or Porta Pedis pain

234 of 459  
51%  
Plantar Fasciitis  
alone

# Plantar Fasciitis Treatment Analysis

**Of all 459 patients post mechanical  
87% resolution (344 of 459)**

**Of 225 patients with neurological findings  
original resolution (126 of 225)**

**99 patients recommend emg/ncv  
Final resolution 75%**

**12% difference  
Nerve involvement**

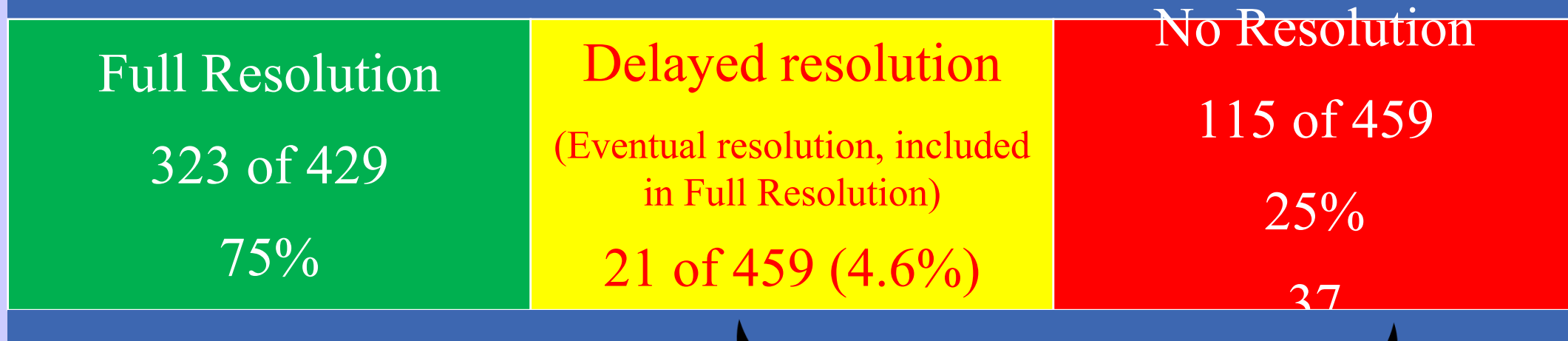**73/99 EMG performed on**

**52 - of no resolution group**

**21 - of pain free group that had delayed resolution**

# Analysis

## 429 Plantar Fasciitis patients



**68 EMG  
performed**

# 429 patients - 58 EMG's EMG Analysis

21 EMG on patients with delayed positive response and outcome

37 EMG on patients with negative response and negative outcome

45 had both tarsal tunnel and radiculopathy	45/68	66.17%
15 had radiculopathy findings alone	22/68	22.05%
<u>8</u> had tarsal tunnel findings alone	8/68	<u>11.76%</u>
68		90.04%

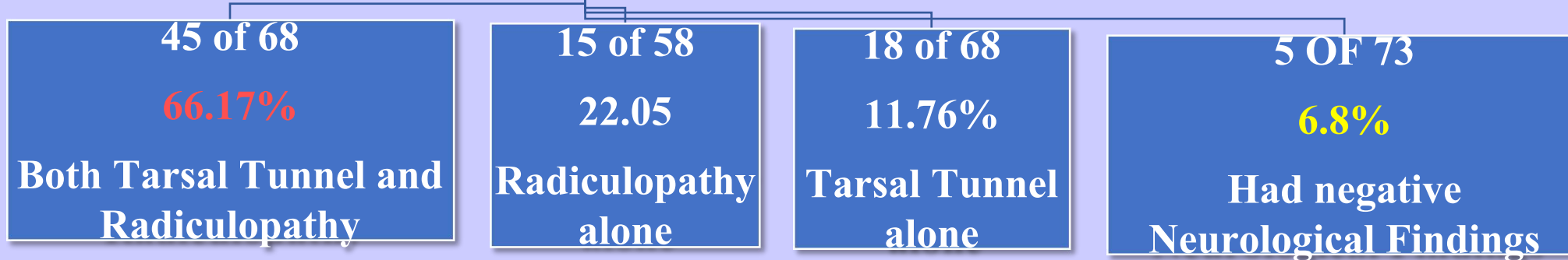
5 only had negative neurological findings 5/73 6.8%

73

Did not or difficult to get better, 92% had significant neurological issues

# EMG ANALYSIS

459 Patients  
73 EMG  
21 EMG delayed response  
52 EMG on NO RESPONSE



93.15%  
**POSITIVE NEUROLOGICAL FINDINGS**

# Plantar Fasciitis

## Methods of Neurological Treatment

### EMG requested for\_:

- Obvious TT/PP neurological pain**
- Active back pain**
- Nonresponsive plantar fascia treatment**
- Essentially negative MRI**

### Treatment:

- Tarsal Tunnel/Porta Pedis cortisone injection**
- Topical capsaicin compound (EBM)**
- Iontophoresis (EBM) / Interferential stimulation**
- Tarsal Tunnel Release**
- Lumbar Epidural injection**
- More...**

# Capsaicin

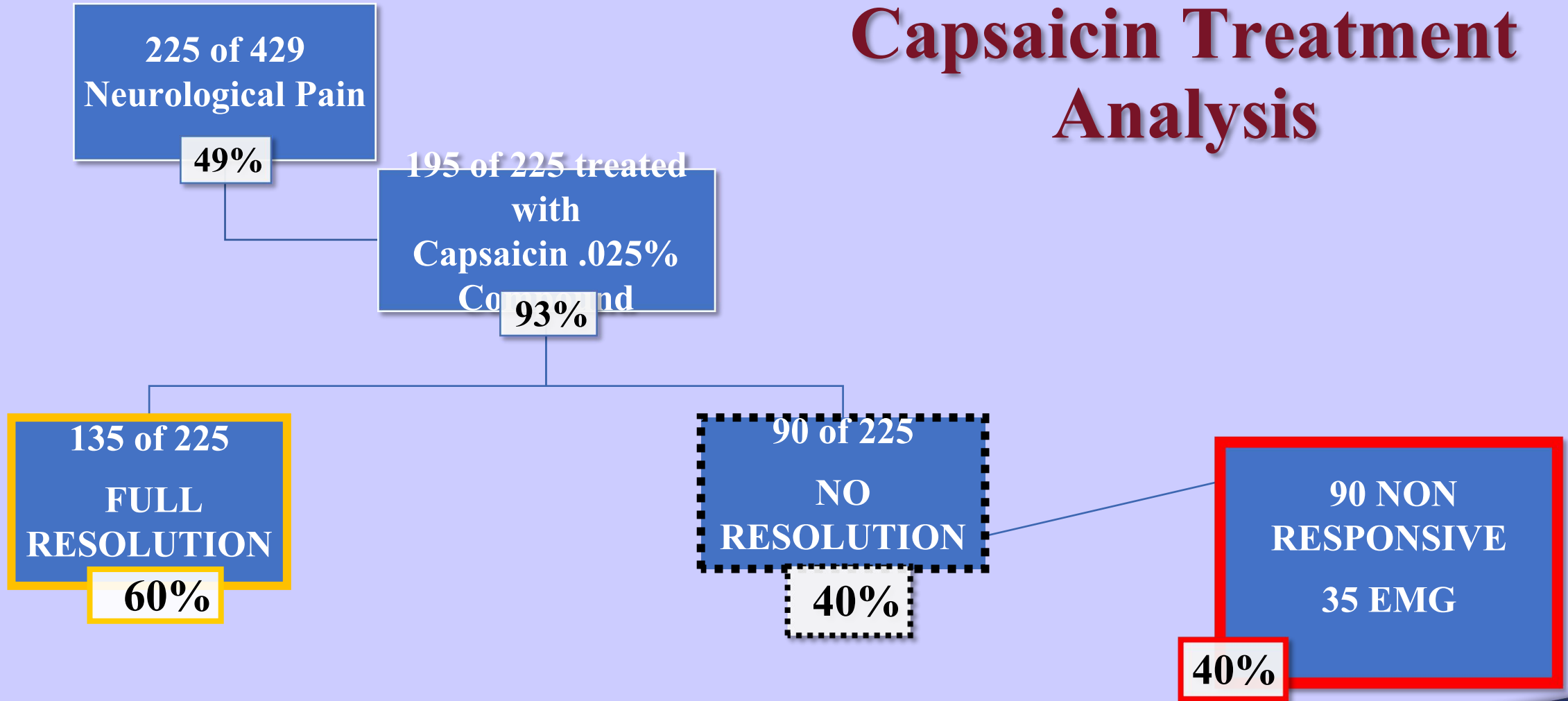


- Capsaicin (8-methyl-N-vanillyl-6-nonenamide)
- Puts the **HOT in hot foods** / Scoville scale
- Produced to sustain species and prevent decimation
- In internal lining, fleshy parts of fruit, **NOT SEEDS**
- **NOT** water soluble, lipid soluble with alcohol and organic solvents
- Topical medication as analgesic, peripheral neuropathy  
(shingles, diabetic, HIV), pepper spray, animal repellent
- Compounded and ordered through EBM
- Mode of action.....

# Capsaicin Mode of Action

- **Suggested Mode of action.....**
- **Attaches to and activates vanilloid receptor sub type receptor  $TRP_{ccsf} V_m 1$  on nociceptor fibers (also activated with abrasion/heat) which is responsible for the sensation of heat above  $109^{\circ}F$  and/or burning**
- **The sensation is received at spinal cord level and transferred to Thalamus for higher center identification of location and intensity**
- **Substance  $P_{ip2}$  is neurotransmitter, causes pain**
- **Initial sensitization and then with loss of P, less mediator, less pain**
- **Decreases substance  $P_{ip2}$  to decrease nerve electrical impulse**
- **Provides sensitization and desensitization of nerve**

# Capsaicin Treatment Analysis



# Failed Capsaicin Treatment EMG Analysis

**88.56% (31 OF 35)**  
had POSITIVE  
**NEUROLOGICAL**  
**FINDINGS**

4 NEGATIVE EMG FINDINGS

22 of 35  
62.85%  
Both Tarsal Tunnel and  
Radiculopathy

2 of 35  
5.71%  
Tarsal Tunnel alone

7 of 35  
20%  
Radiculopathy alone

# Capsaicin Conclusion

## Therapeutic Effect – local irritation

60% of time it will decrease nerve sensitivity induced through irritation from inflamed/damaged plantar fascia

## Diagnostic Effect – significant neurological damage

40% no response indicates neurological problem is beyond ability to moderate local irritation

88.56% (31/35) condition such as Tarsal Tunnel or radiculopathy, or both, present

# Capsaicin Conclusions

✓ Neuritis clinically accompanies Plantar Fasciitis OFTEN **49%**

Local inflammation via the Plantar fascia ... **60%** (60% of 49%)

✓ Etiology Associated tarsal tunnel syndrome

Associated radiculopathy ..... **40%**

✓ Topical Capsaicin THERAPEUTIC and DIAGNOSTIC modality (~ 60% improvement)

✓ Lower back related symptoms exacerbate and compound symptoms

✓ Nerve injury consistently inconsistent.....

✓ Nerve injury can be difficult to dx and tx

✓ Suggest **DISCUSS EARLY IN TREATMENT**

# Treatment of condition

Plantar fascia:

inserts / boot / orthotics

cortisone / nsaid / Medrol pac / narcotics

PT (equines)

ice

Iontophoresis/interferential

shoes

interferential

amniotic graft)

\* Surgery (Coblation)

Neuritis:

cortisone injection

capsaicin cream

CBD

nsaid / narcotics

\* Nerve Release (with

# Summary

- **Plantar fasciitis often has neurological involvement**
- **Take time to diagnosis**
- **Treat each condition separate**
- **Order specific tests: mri/emg – ncv**
- **Do try all available treatments prior to surgery as 88% of time they work**





# Weil Foot & Ankle Institute

**Anthony H. Borrelli, D.P.M., FACFAS**

# Plantar Fasciitis Incidence of Neuritis

- Total patients 429, 100% of patients had signs and symptoms of plantar fasciitis
- 210 of 429 had Tarsal Canal or Porta Pedis pain along with above Plantar Fasciitis S/SX  
★ 49%
- 219 of 429 had pain longitudinal band/sub tuberosity alone
  - **51% had PF alone**

# Plantar Fasciitis Clinical Presentation

**Primary presentation - Pain**

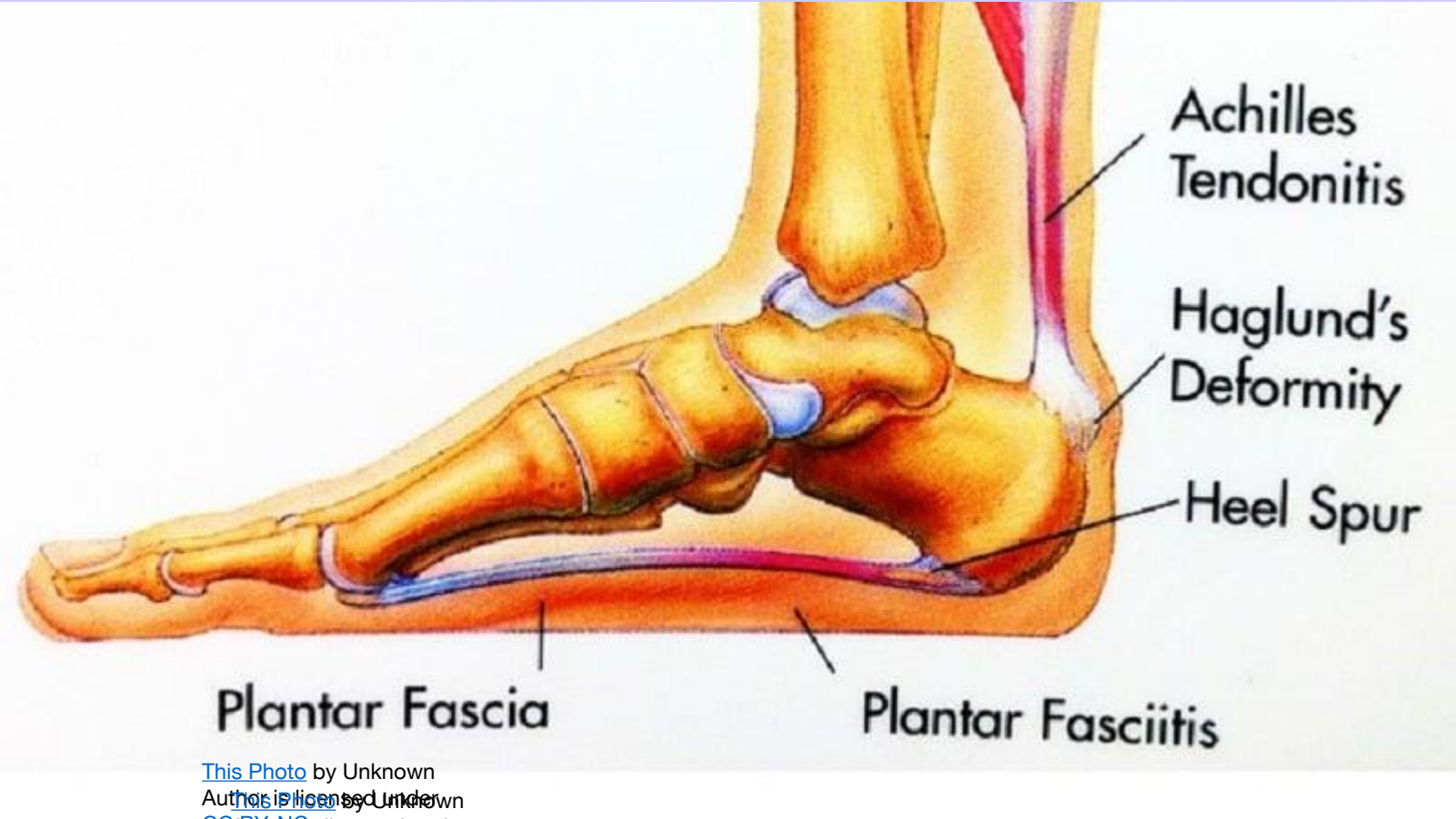
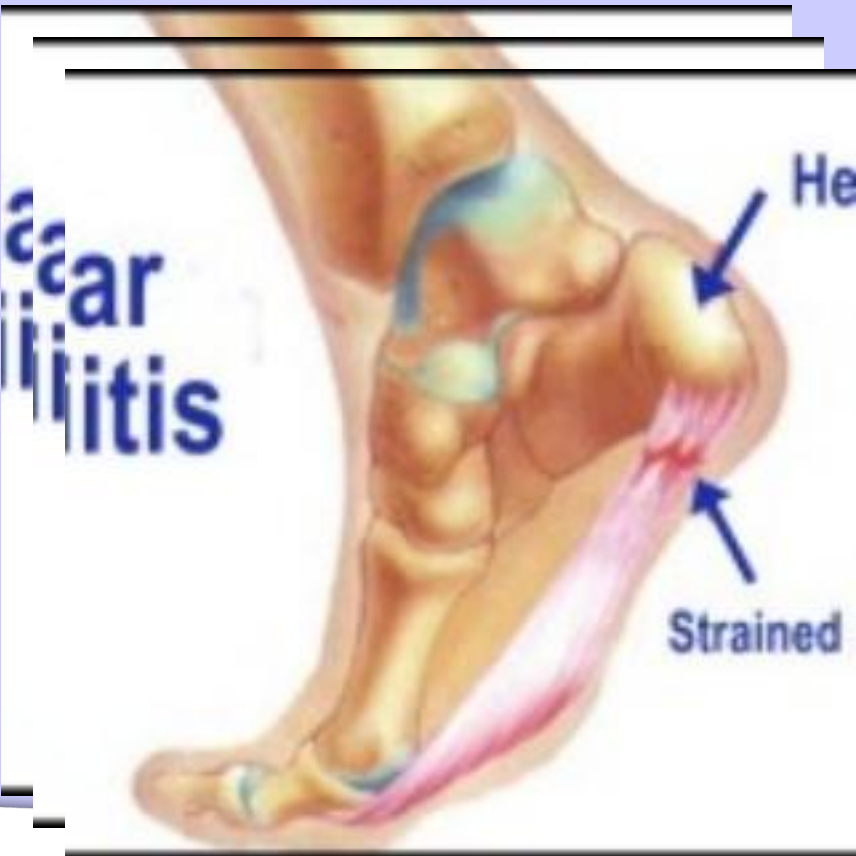**Seeing patients 38 years**

**Inconsistent presentation of Pain P/P heel**

**?Questionable origin? Neurological involvement ?**

**Conduct study/evaluation**

**Chronic overuse injury due to  
Instability of the mid tarsal joint**



This Photo by Unknown  
Author is licensed under  
CC BY-NC  
Author is licensed under  
CC BY-NC  
Author is licensed under  
CC BY-NC

**Normal thickness 3-5 mm  
Homogenous low signal MRI  
Hyperechoic on sonogram**

# Plantar Fasciitis failed capsaicin treatment – EMG result

Of 35 who failed capsaicin and had EMG

**31 had positive Neurological findings 88.56%**

22 both tarsal tunnel and radiculopathy  $22/35 = 62.85\%$

2 tarsal tunnel alone  $2/35 = 5.71\%$

7 radiculopathy alone  $7/35 = 20.00\%$

Significant neurological manifestation **88.56%**

4 failed with negative EMG findings  $4/35 = 11.4\%$

35

# Capsaicin

## Mode of action

- **Suggested Mode of action.....**
- **Attaches to and activates chemoreceptor TRPV1 which is responsible for the sensation of heat and/or burning**
- **The sensation is received at spinal cord level and transferred to Thalamus for higher center identification of location and intensity**
- **Substance P is neurotransmitter**
- **Decreases substance P to decrease nerve electrical impulse**
- **Provides sensitization and desensitization of nerve**

# 429 patients - 58 EMG's

## EMG Analysis

21 EMG on patients with delayed positive response and outcome

37 EMG on patients with negative response and negative outcome

32 had both tarsal tunnel and radiculopathy	32/58	55.17%
13 had radiculopathy findings alone	13/58	22.4%
<u>8</u> had tarsal tunnel findings alone	8/58	<u>14.79%</u>
<u>51</u>		92.36%

5 only had negative neurological findings 5/58 8.6%

58

Did not or difficult to get better, 92% had significant neurological issues

# Plantar Fasciitis Capsaicin Treatment

210 of 429, (49%), had neurological pain (**219 of 429 plantar fasciitis 51%**)

195 of 210 treated with capsaicin 0.25%

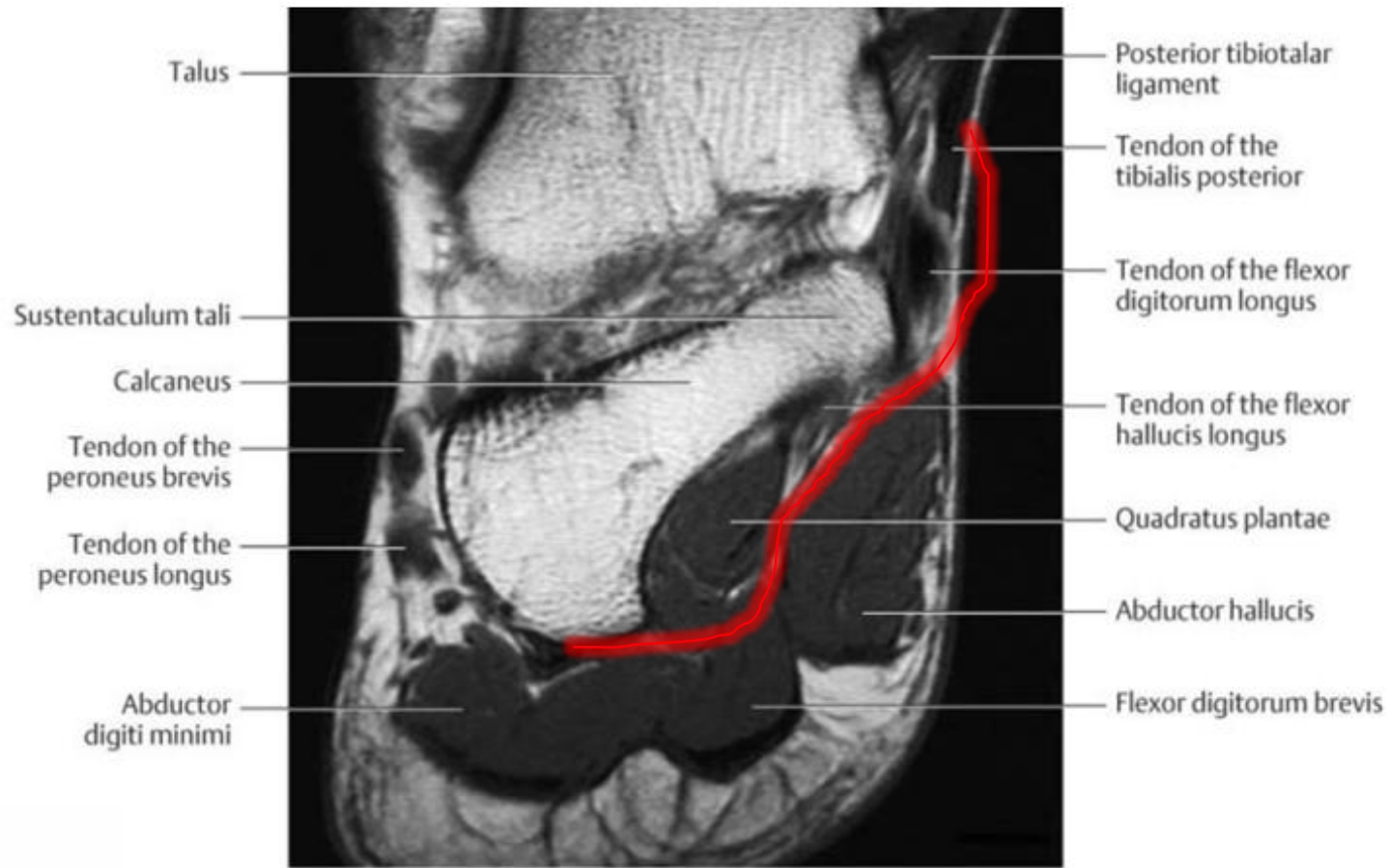
Of 195 treated with capsaicin 0.25% for nerve pain component s/sx:

117 of 195 resolution of pain 60.0%

78 of 195 **NO RESOLUTION** 40.0%

Of 78 tx with capsaicin and no resolution

**35** had EMG 44.87%



# QUESTION: HOW MANY OF ALL PATIENT GROUP RESOLVED

**87%**

**AS THE NUMBER OF POSITIVE EMG SHOWS THAT THERE  
IS A HIGH CORRELATION BETWEEN CLINICAL SIGNS AND  
POSITIVE EMG**