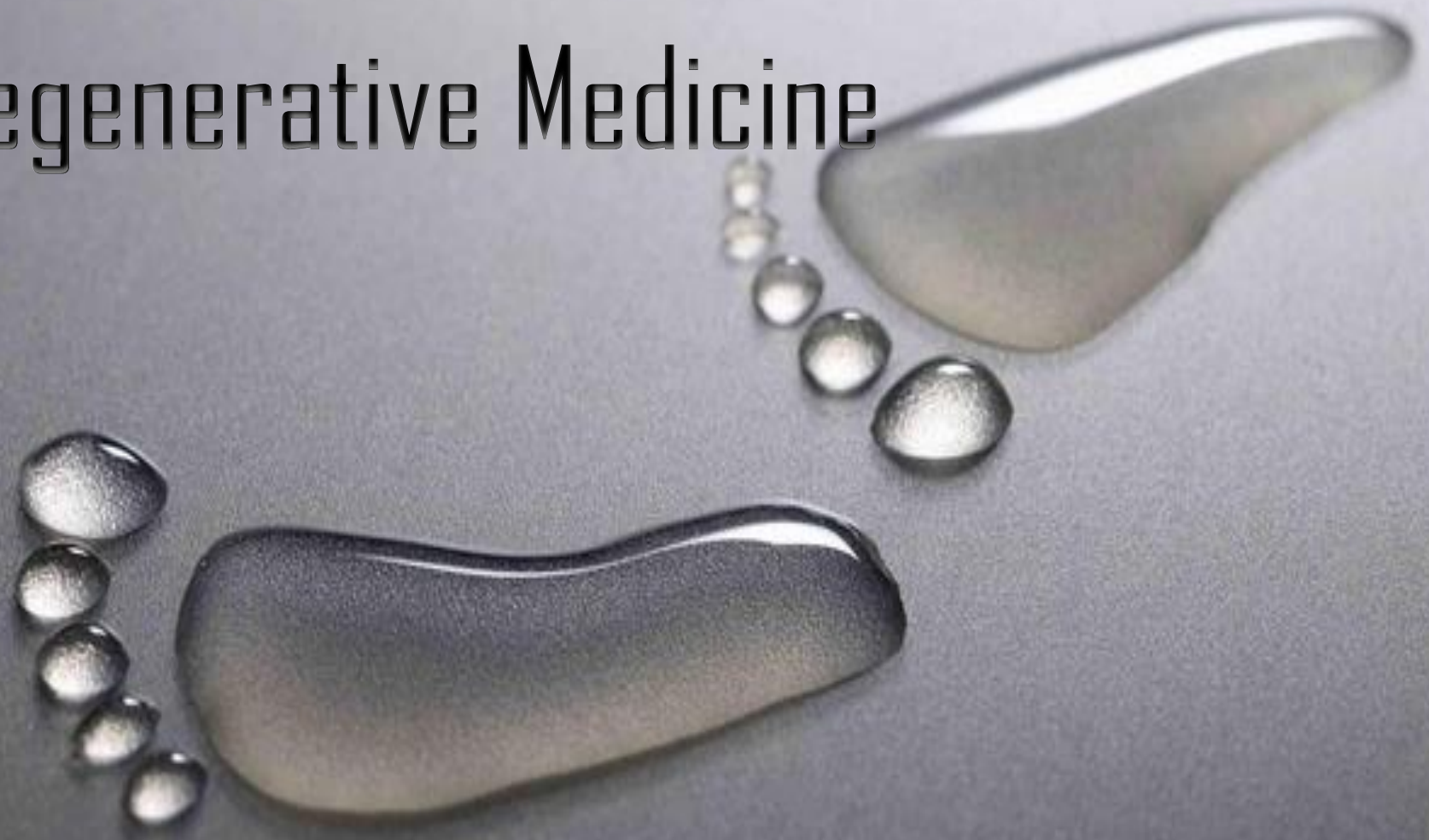

# Foot & Ankle Regenerative Medicine



Rahul N. Desai, MD

# Disclosures

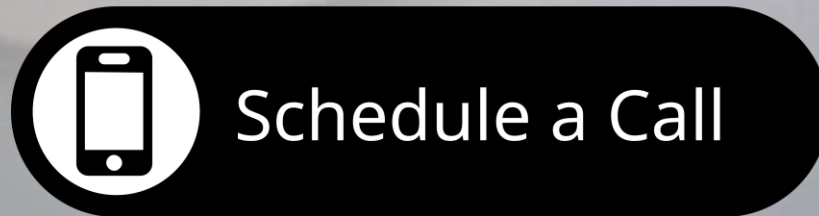
- RedVive Health - CMO and Founding Member
- Regenerative Procedures Institute – Founding Member
- Desai Radiology Consulting
- Arthrex – Consultant
- Tendonova - Consultant

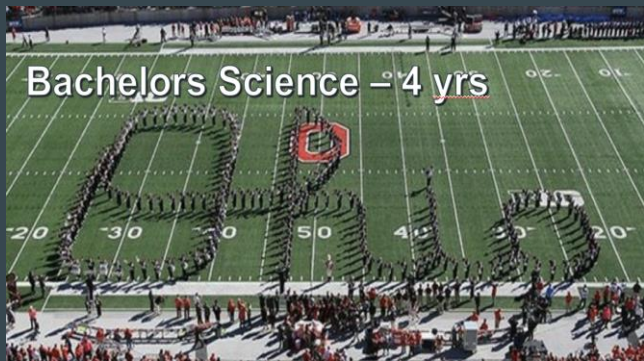Our talks are about  
the  
**POSSIBILITIES!**

# Regen Med & Redlights



# Rahul N. Desai, MD





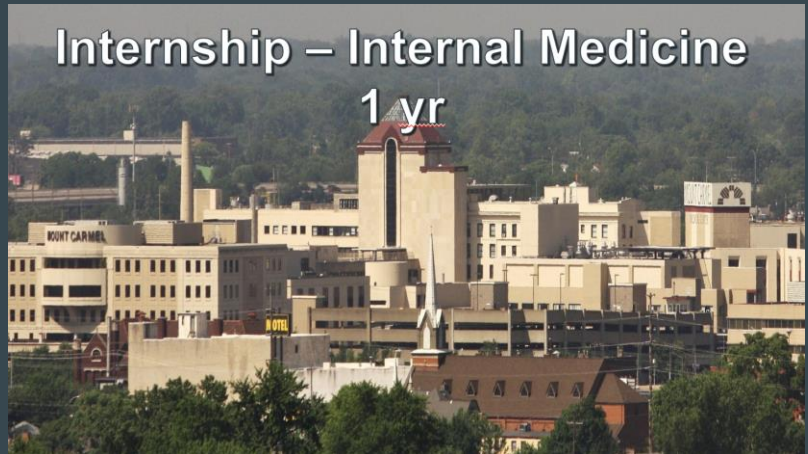
Bachelors Science – 4 yrs



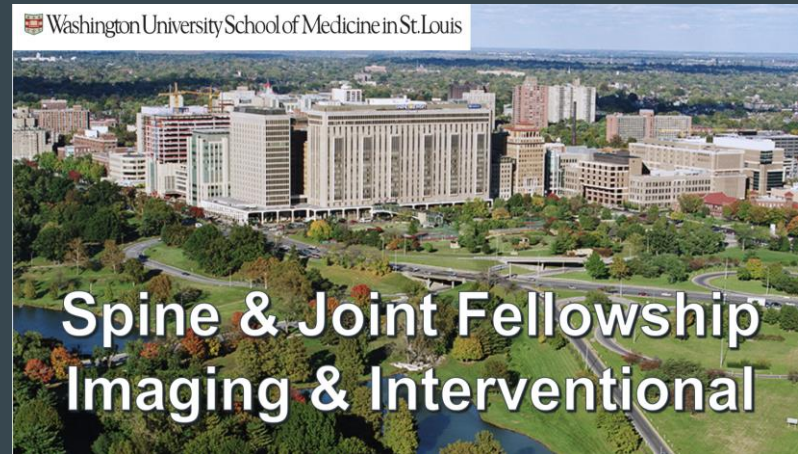MD – 4 yrs



Radiology Residency  
4 yrs



Internship – Internal Medicine  
1 yr



Washington University School of Medicine in St. Louis

Spine & Joint Fellowship  
Imaging & Interventional

14 years of school & training!!!



I was REALLY GOOD AT:

1. FIGURING OUT WHAT WAS WRONG WITH  
SOMEONE

2. PRECISELY PLACING A NEEDLE AND  
**MEDICINE** INTO THE INJURED AREA

# BEFORE REGEN

- PATIENTS ALMOST ALWAYS CAME BACK
- I REFERRED AT A LOT OF PATIENTS TO **SURGERY**
- A LOT OF PATIENTS CAME BACK AFTER SURGERY WITH **MORE PAIN AND DYSFUNCTION**



Physiotherapy



Medications –  
NSAIDS, Narcotics,  
Pain Relievers



Surgery

Alternative Medicine  
Therapies



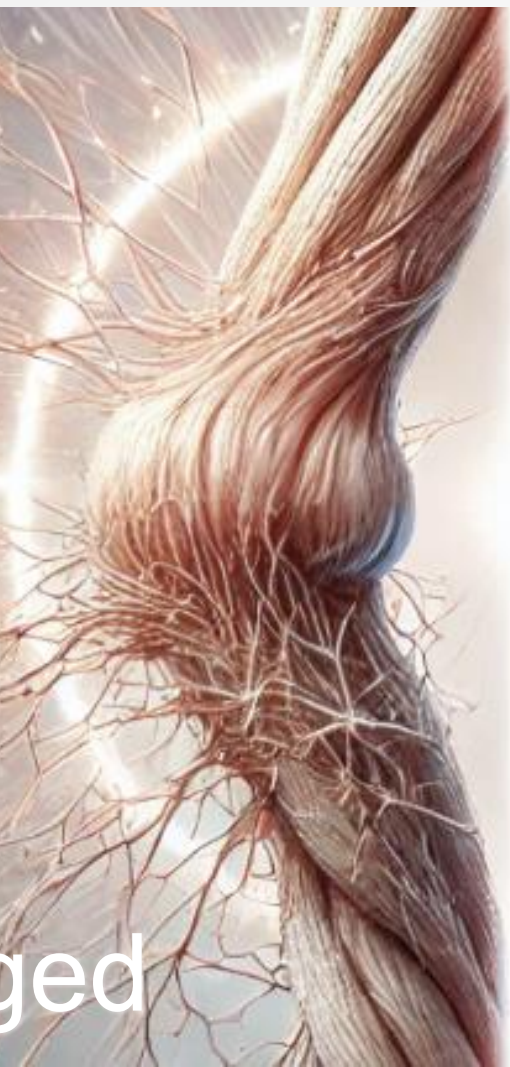
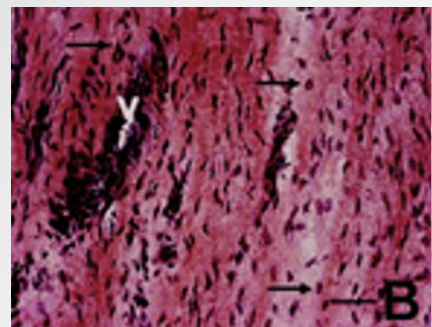
Steroid Injections



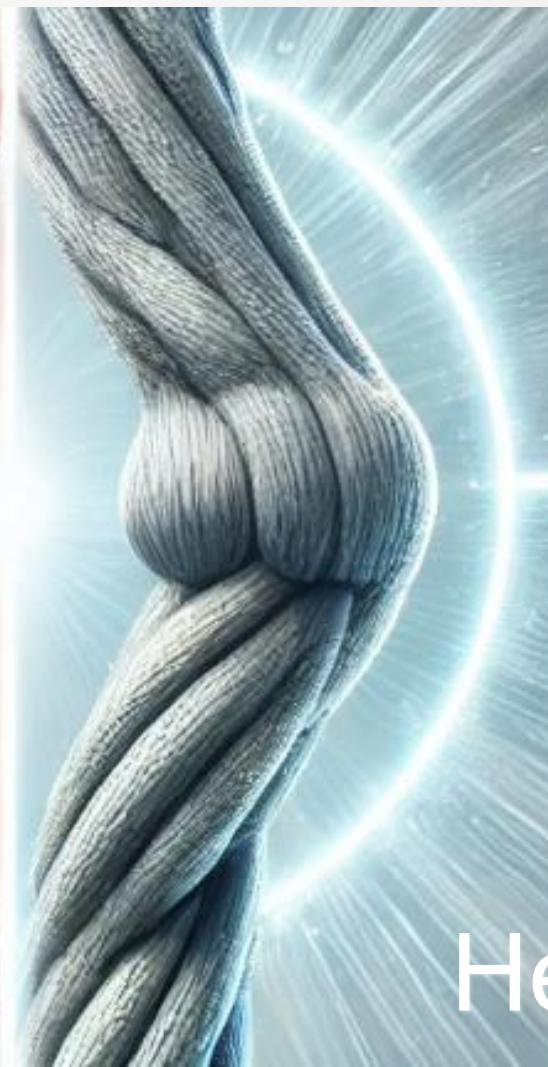



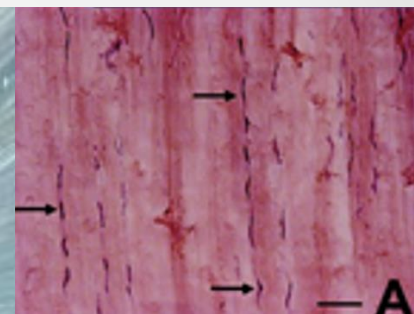
# TAKING THE LEAP 2009



Damaged

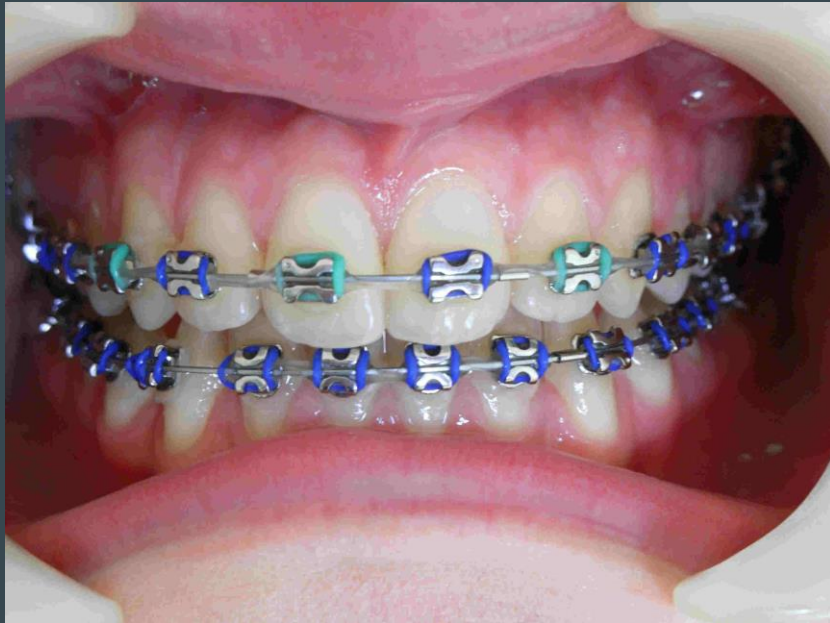

Healing

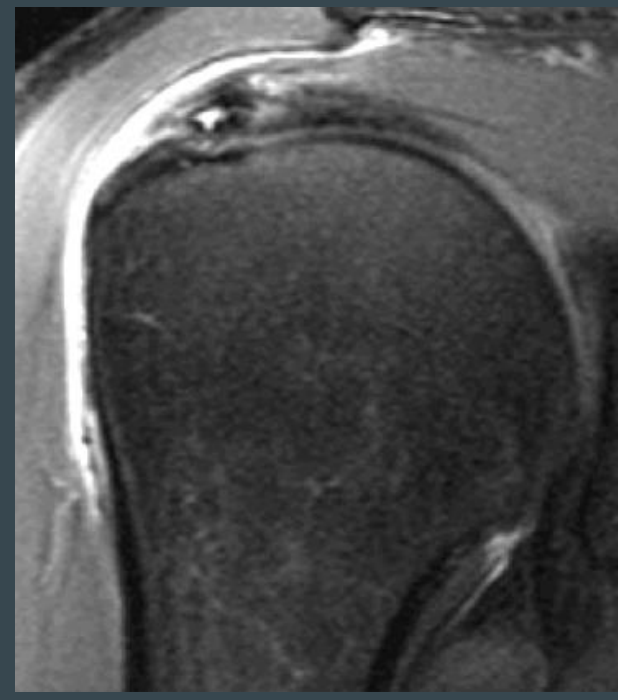
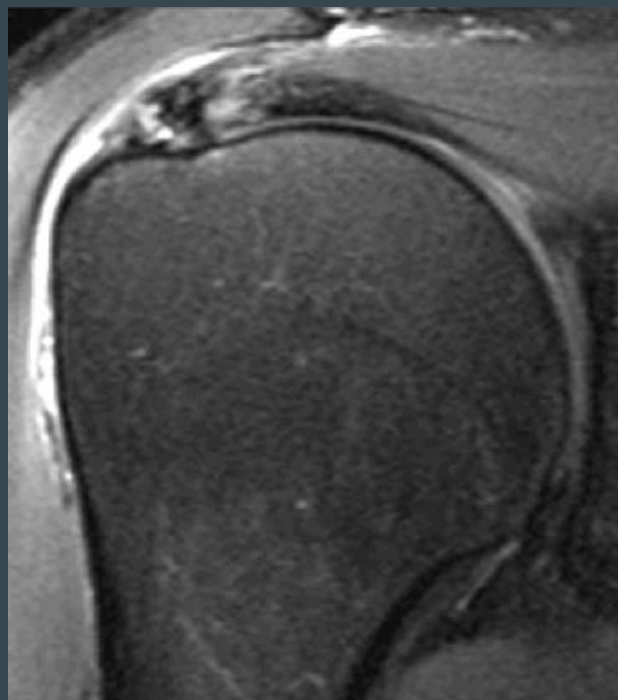
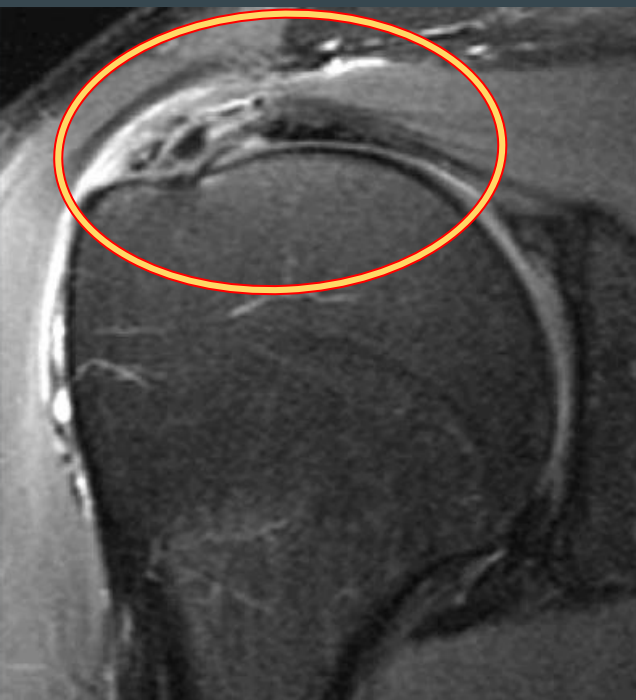

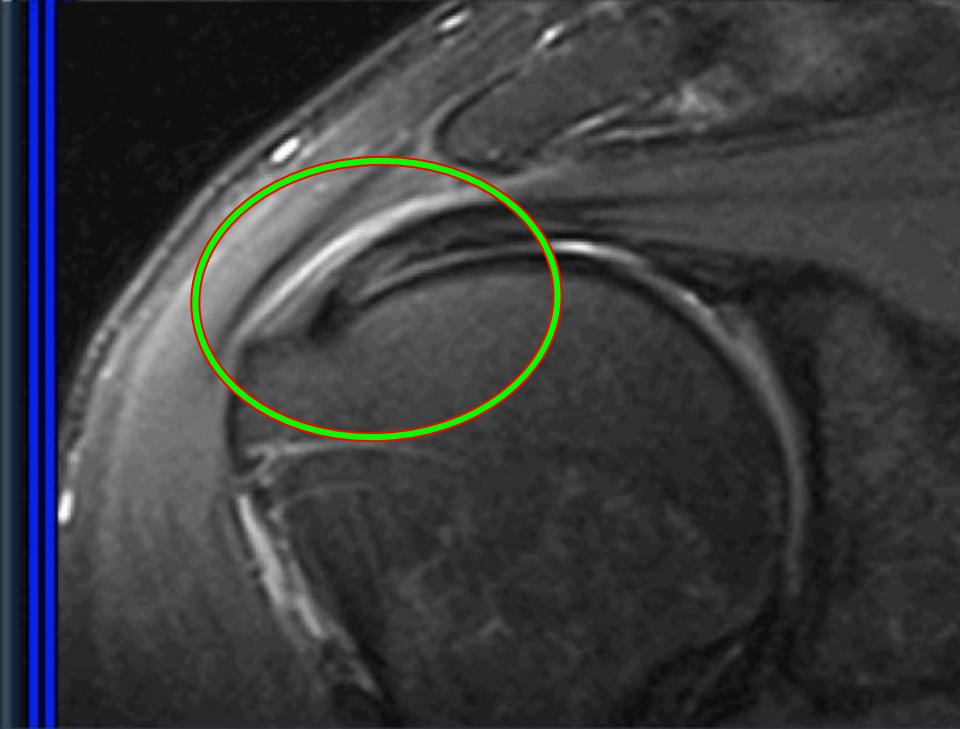
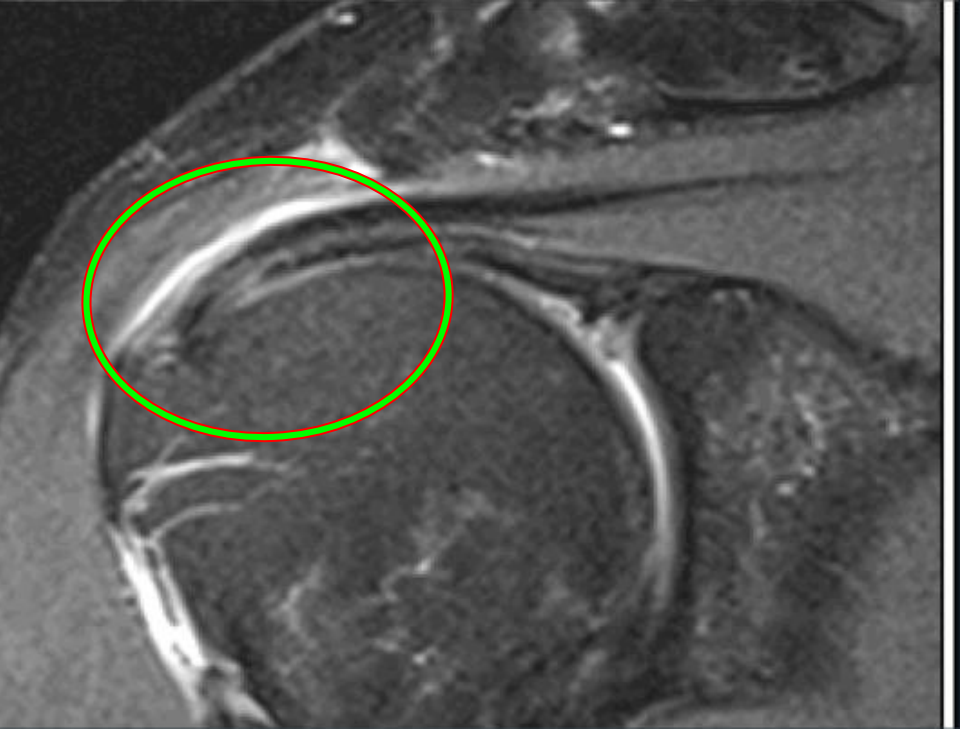
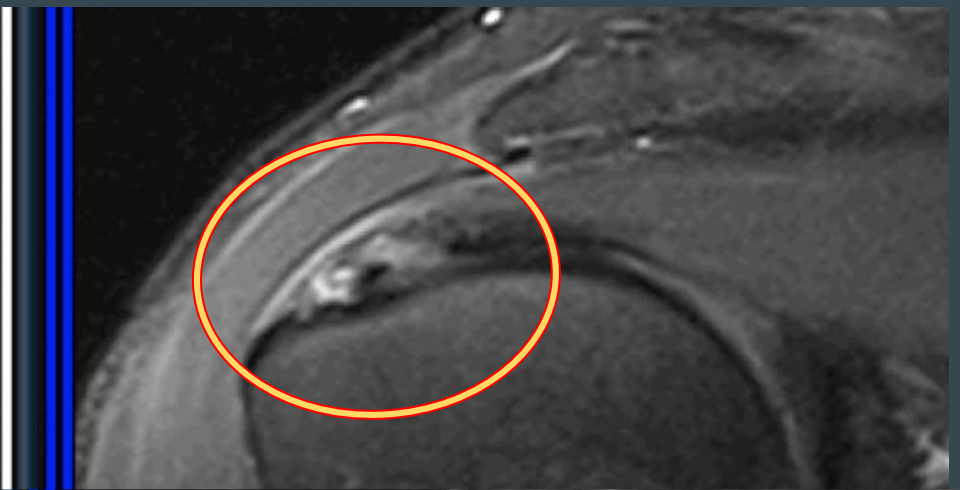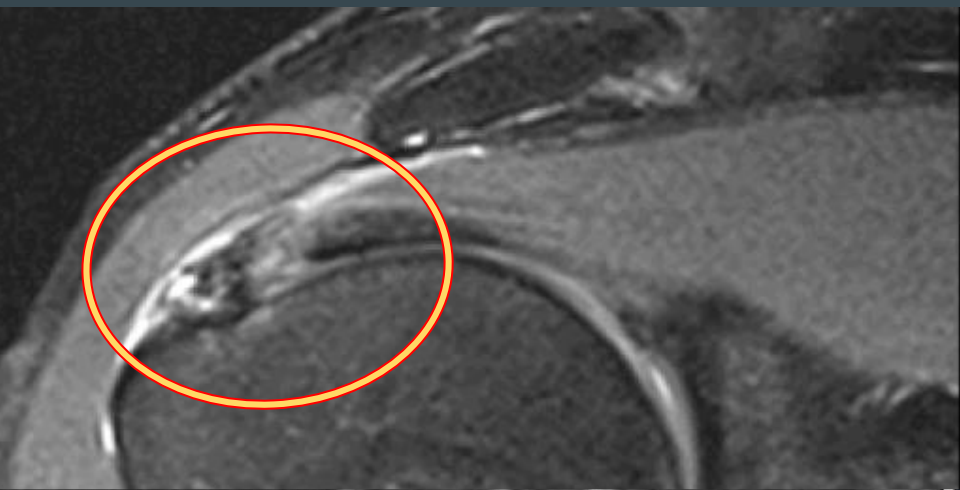- 30 years of experience

# Safety Profile

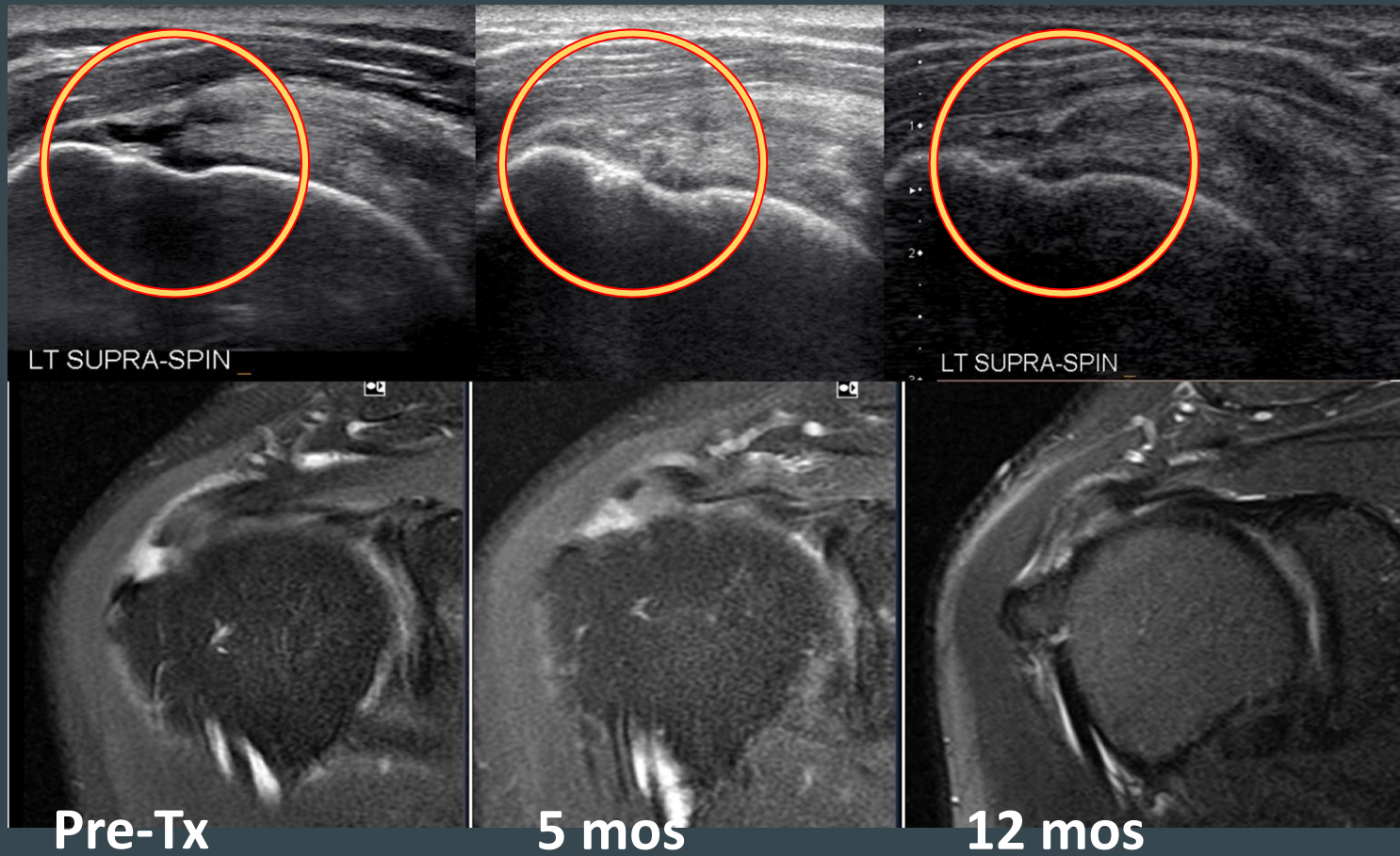


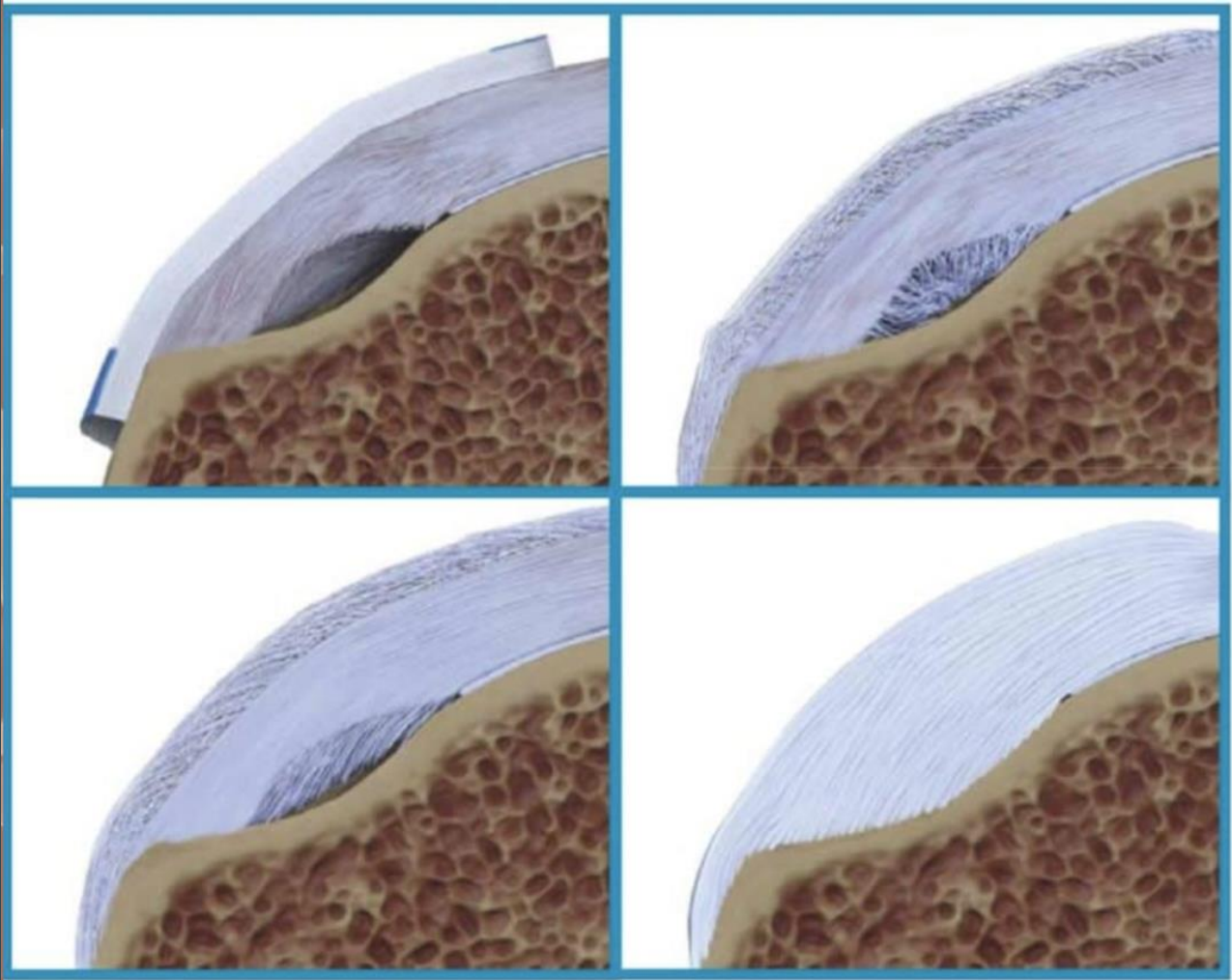
# Male With Shoulder Pain and Calcific Tendinitis of Partial Tears Supraspinatus Tendon



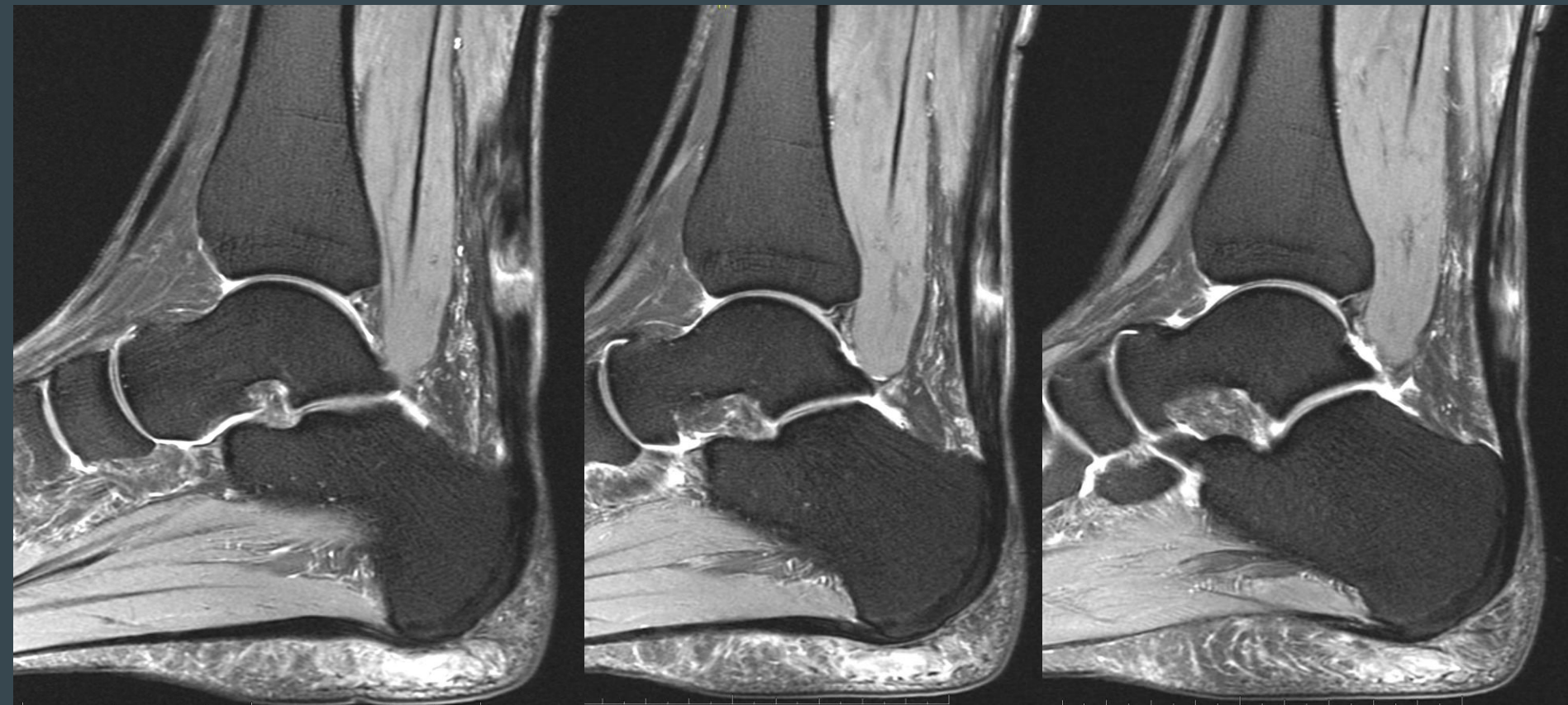


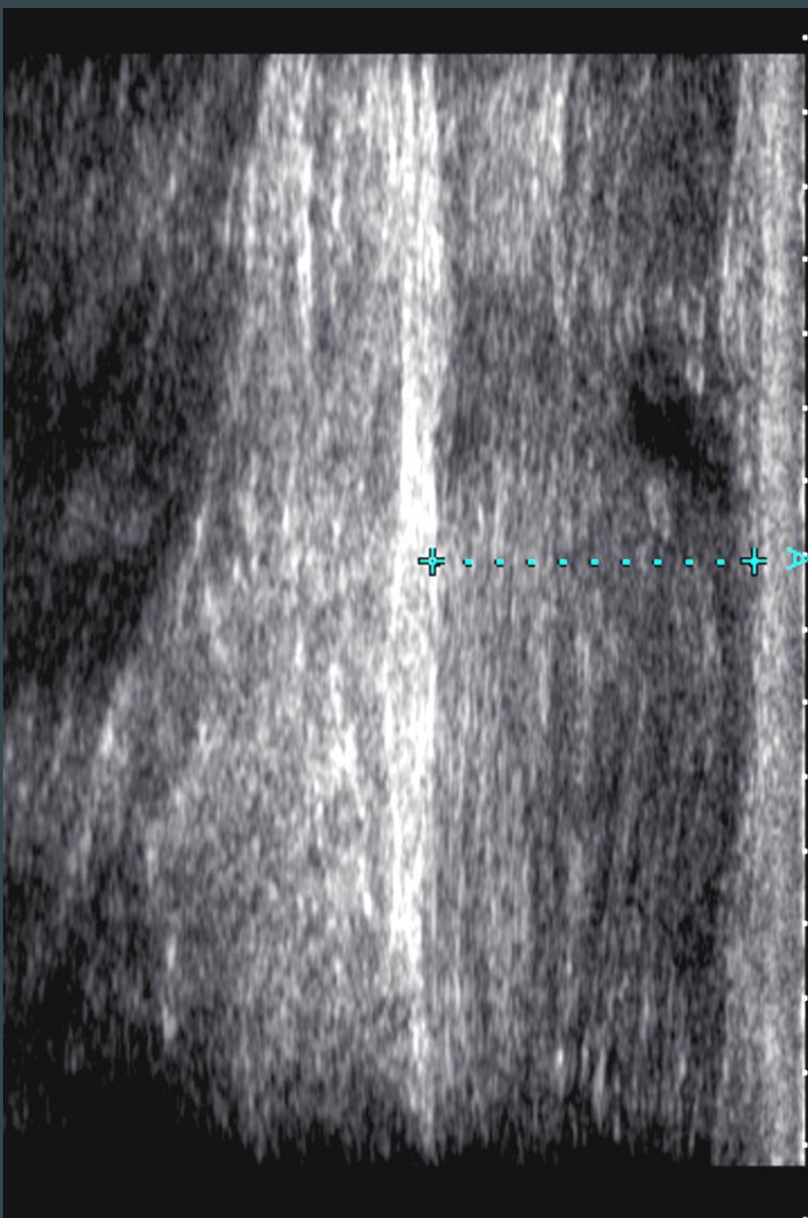
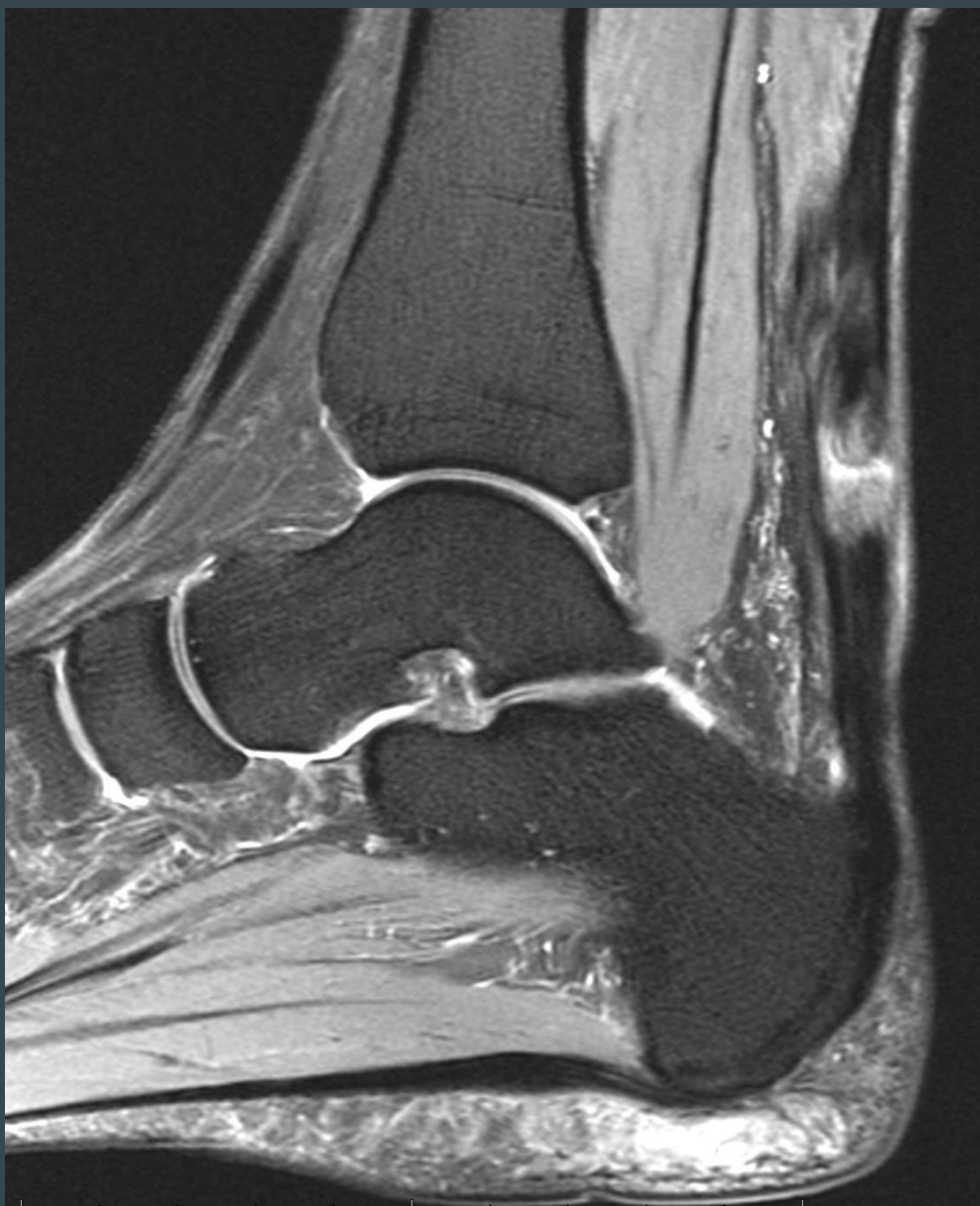# Combination therapy PRP + mdHACM





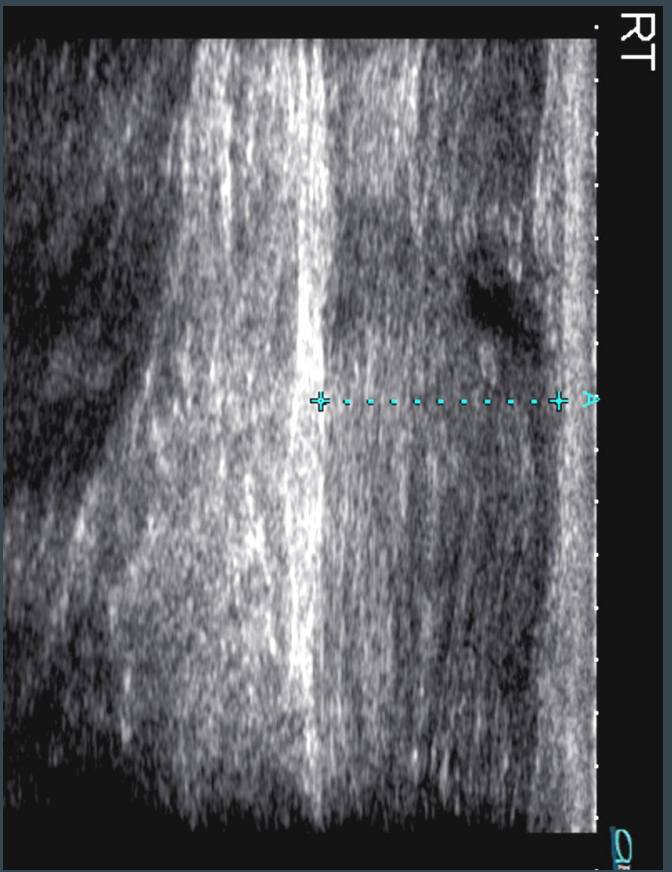
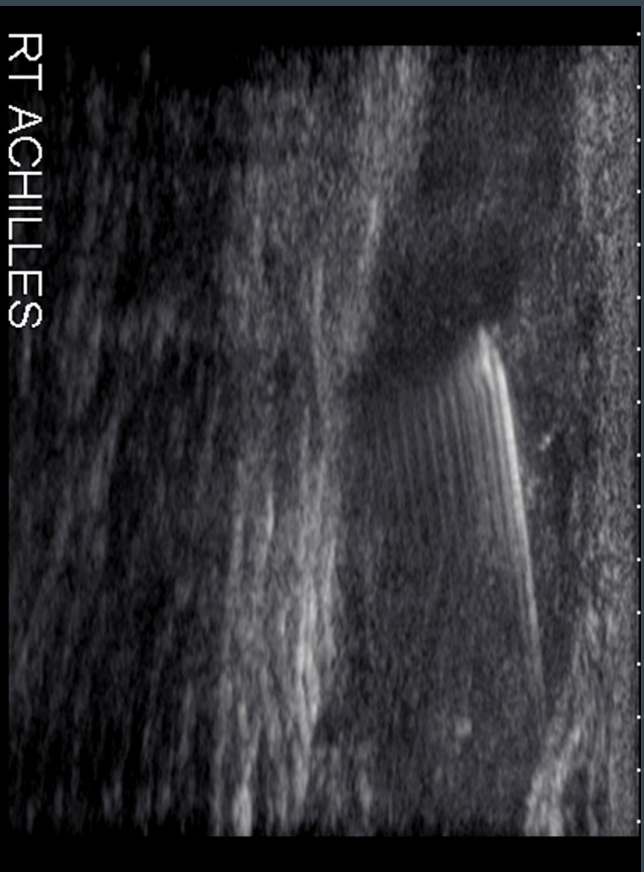
43 yo female w/achilles tear



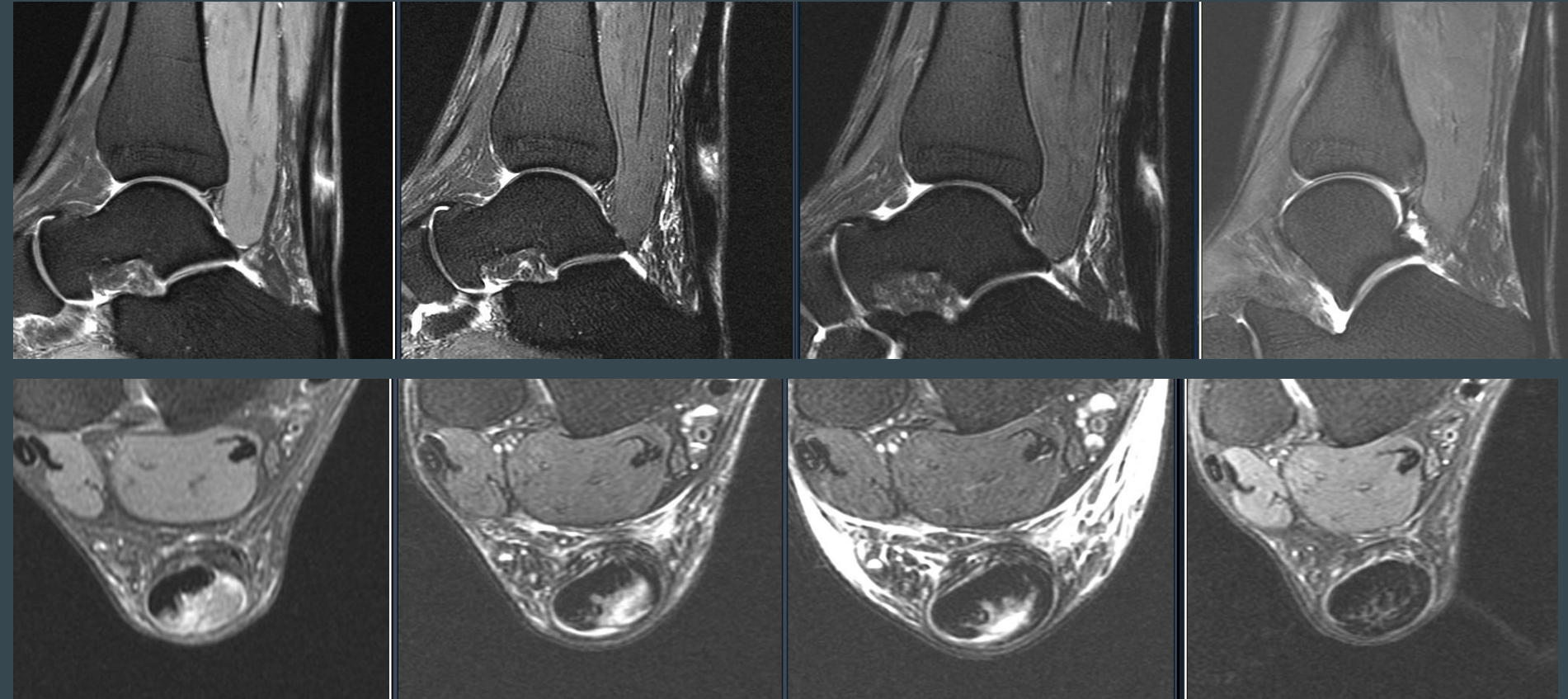


RT

an

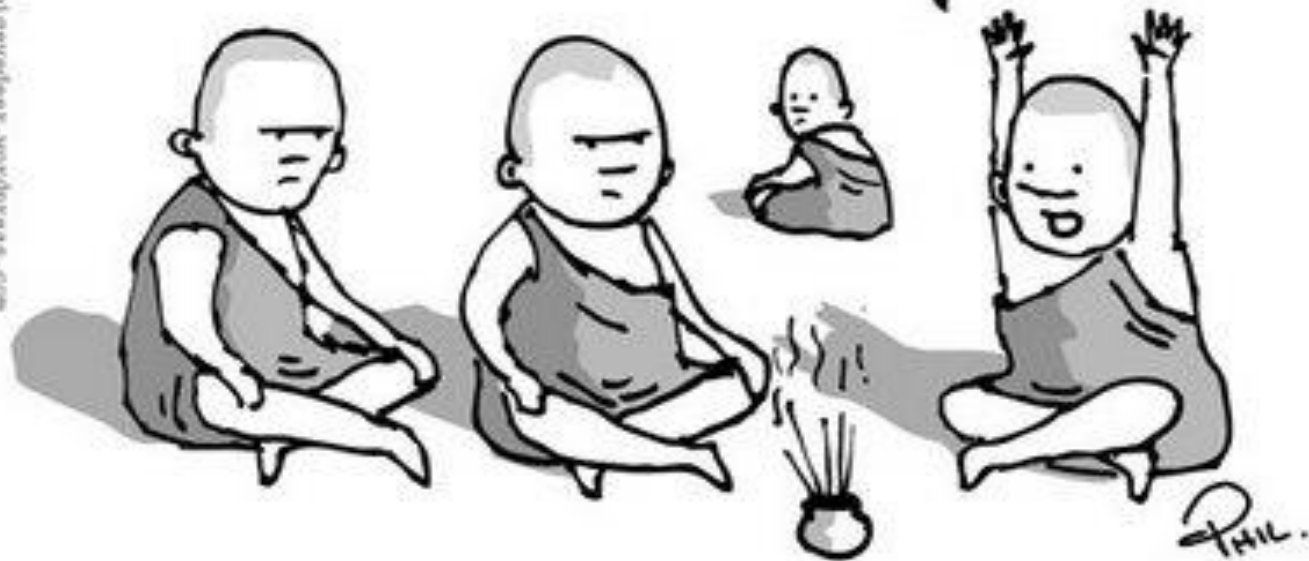

# 70% Achilles Tear – 4 mos interval



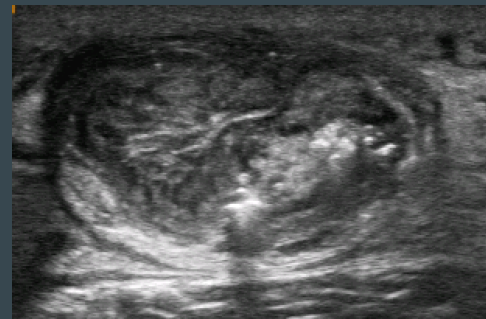
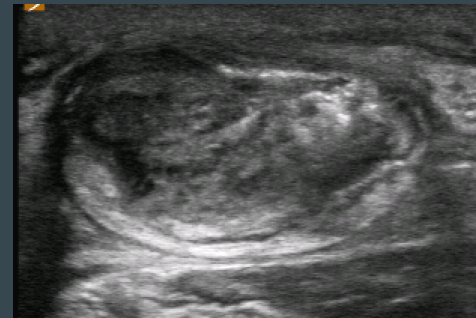
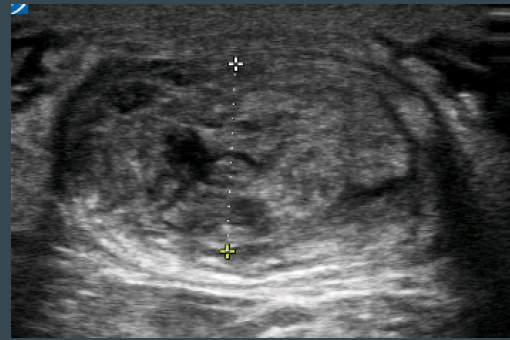
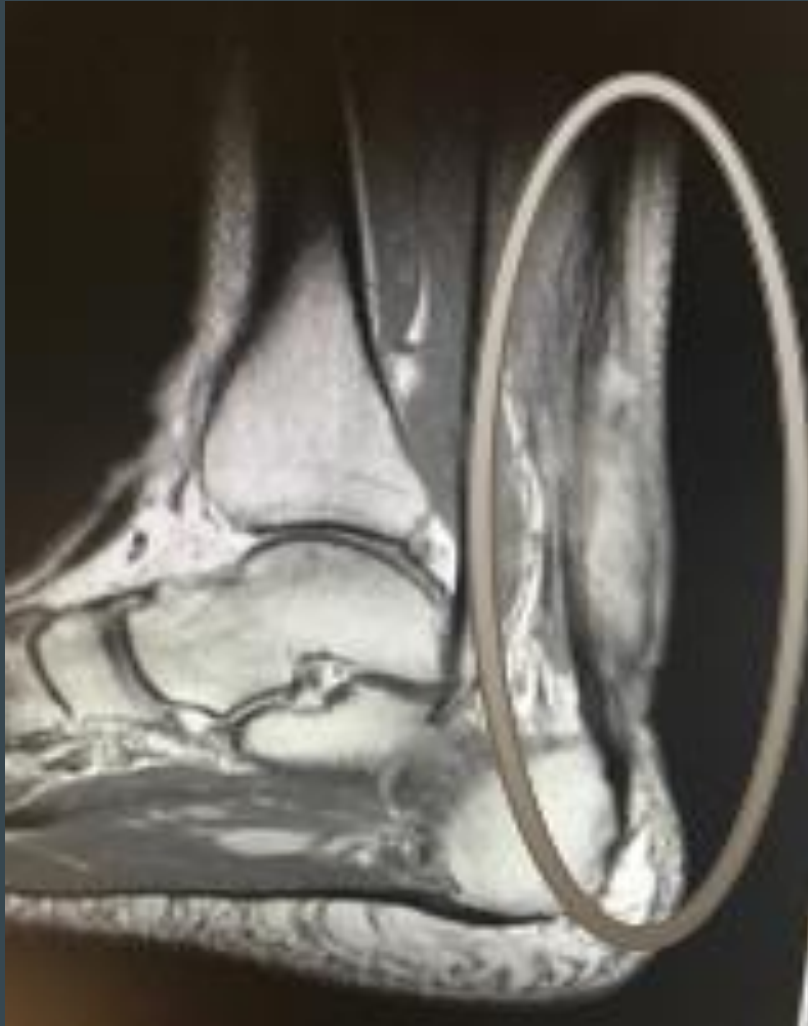Two PRP treatments approximately 2 months apart

OH YEAH! First to reach enlightenment... Right here, people! WOOOO BABY! Eat my dust, ladies!

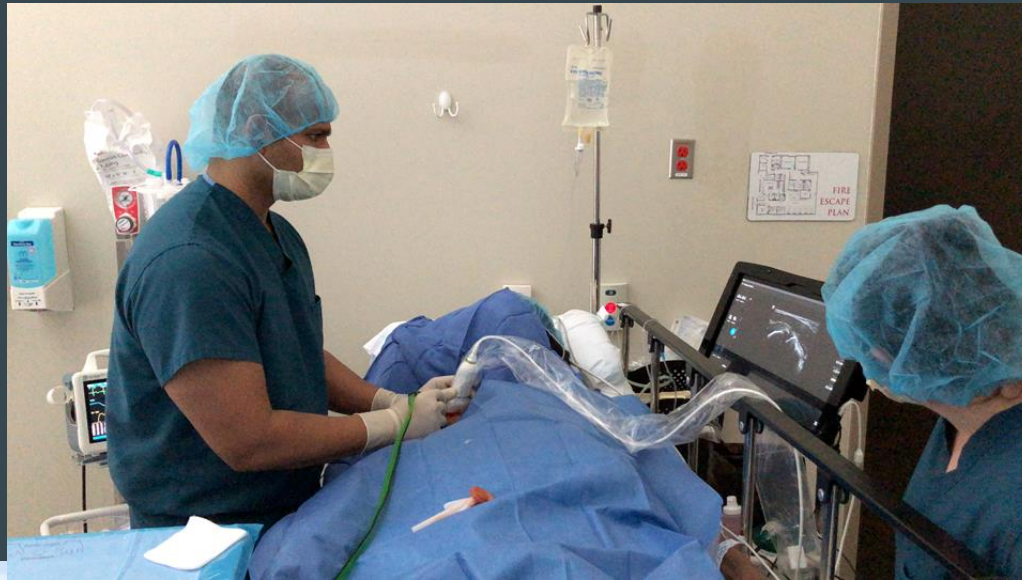

# PRP/Platelet Rich Plasma

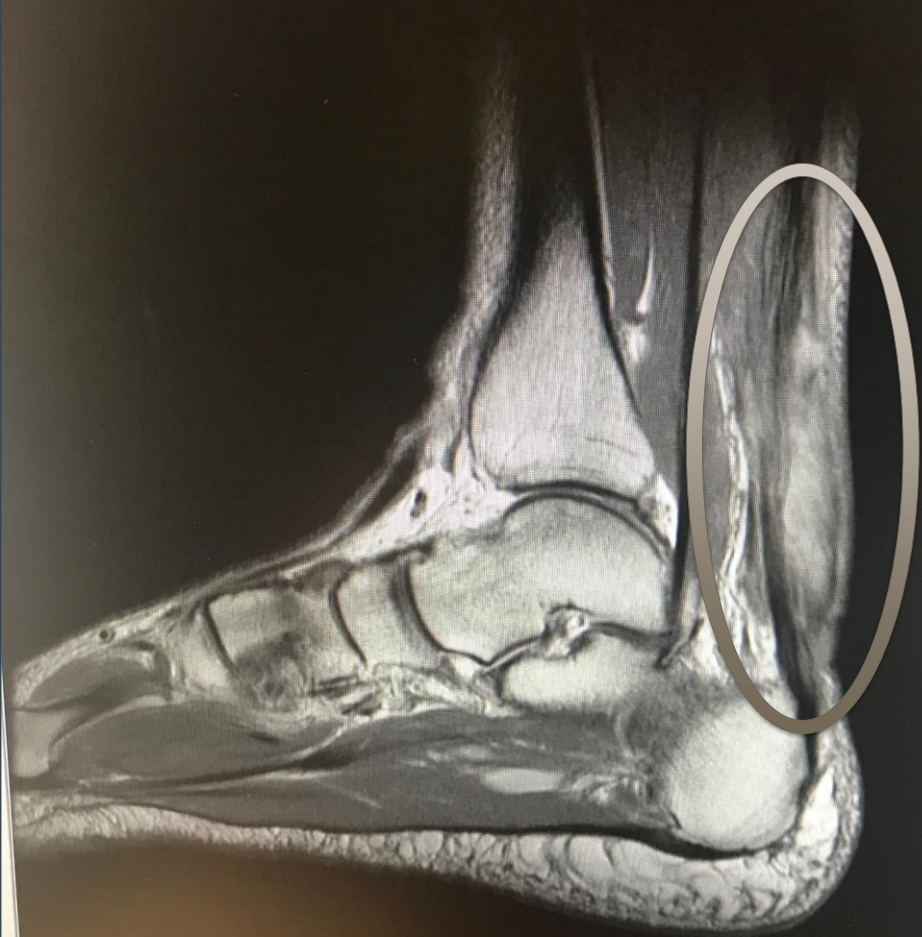



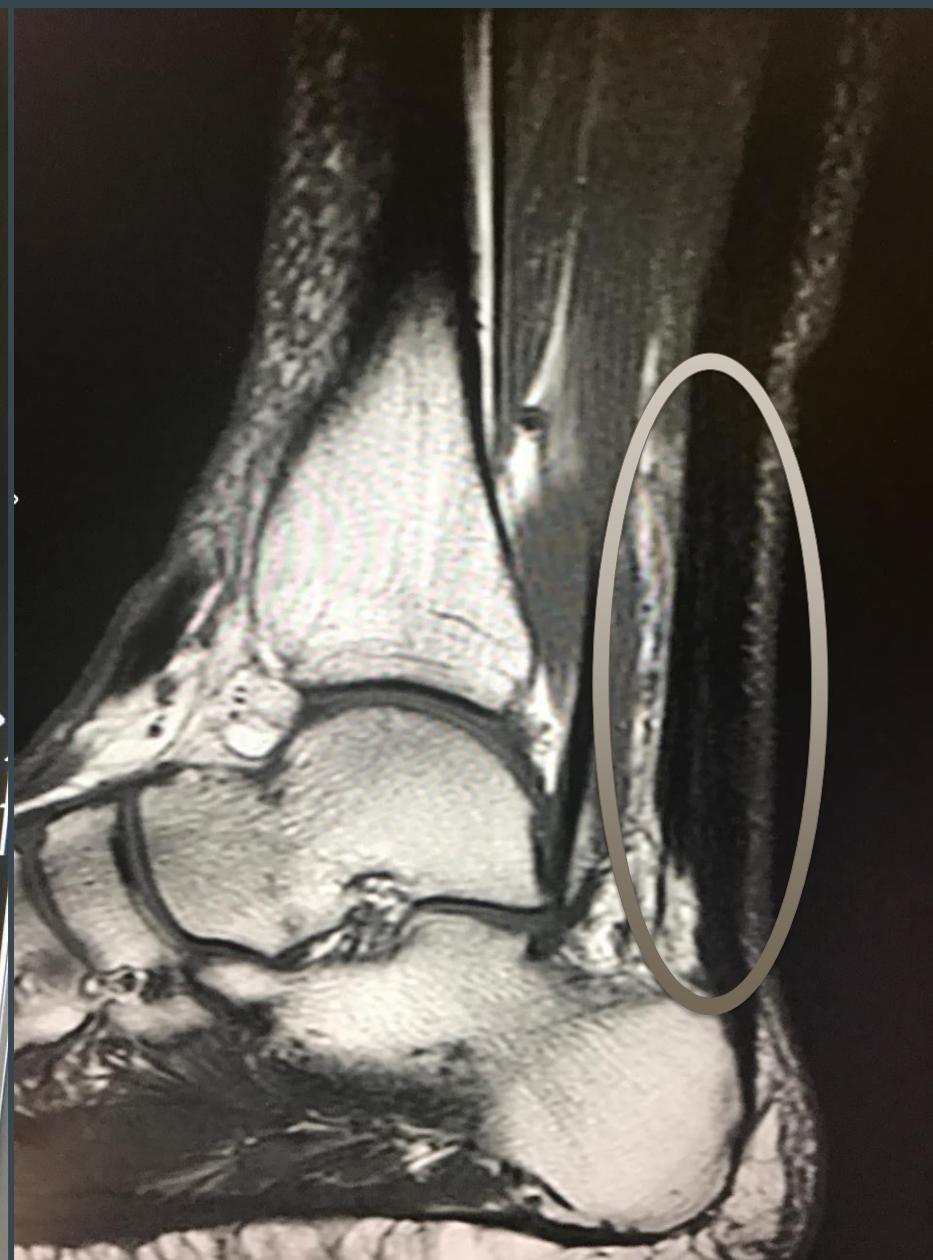# Tenex Debridement Demolition and remodeling



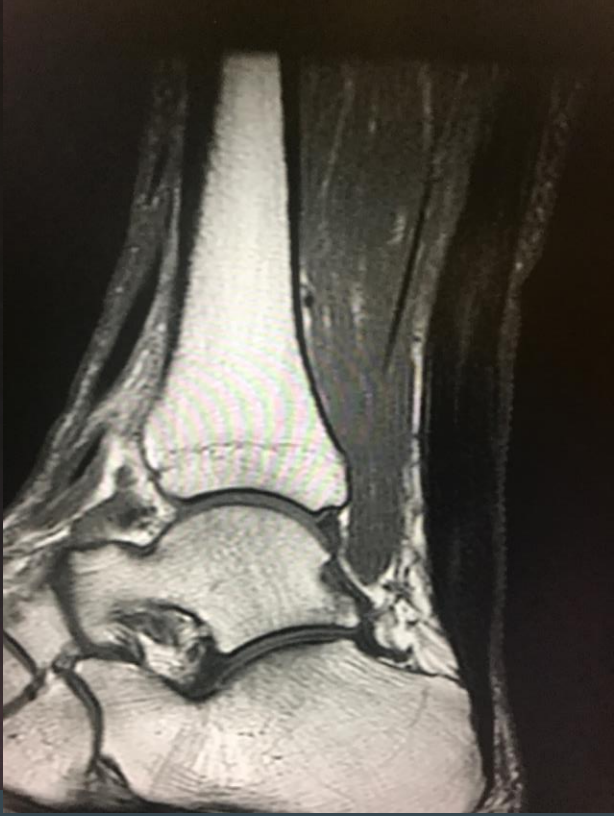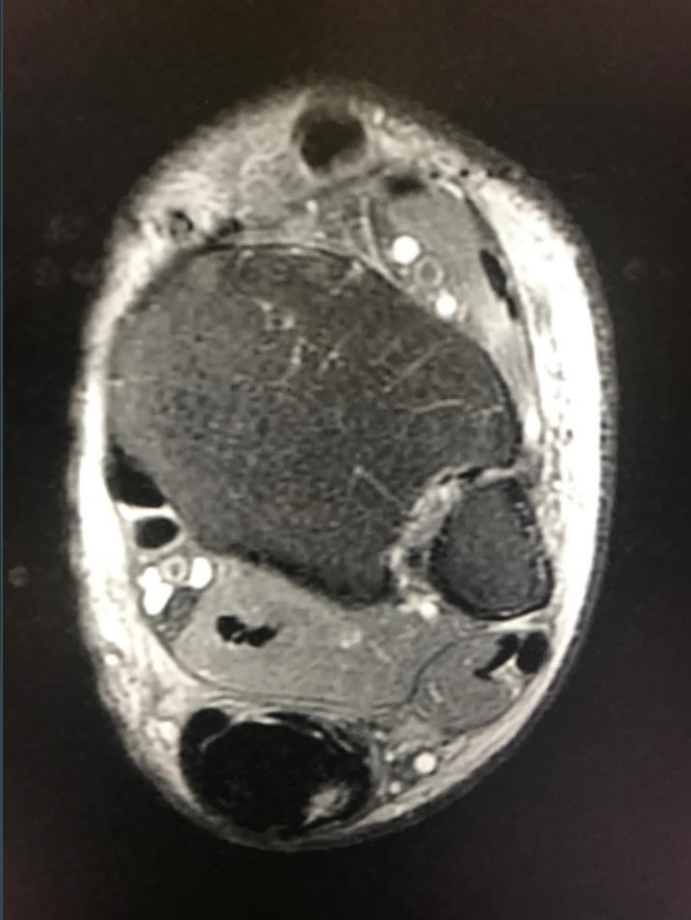
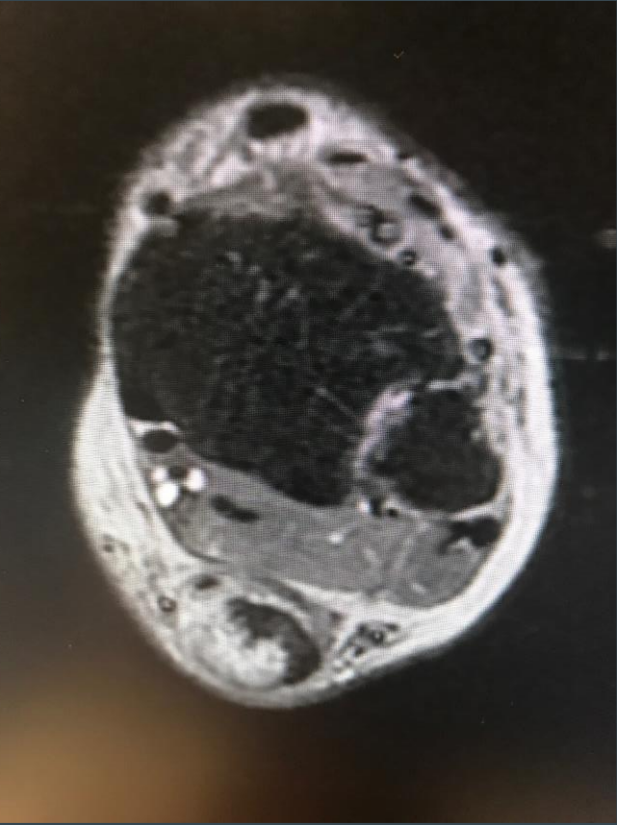
1633.34  
24.08  
1



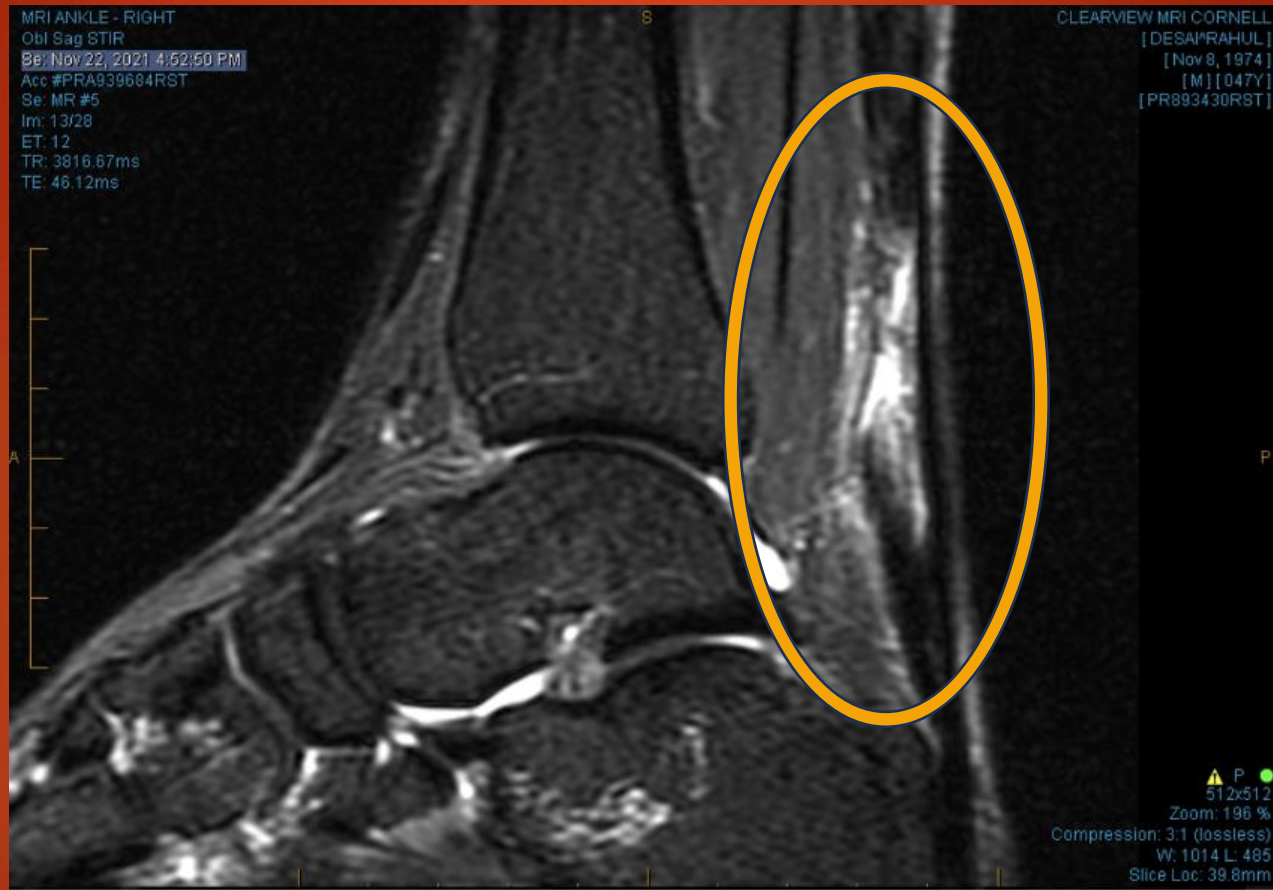
P



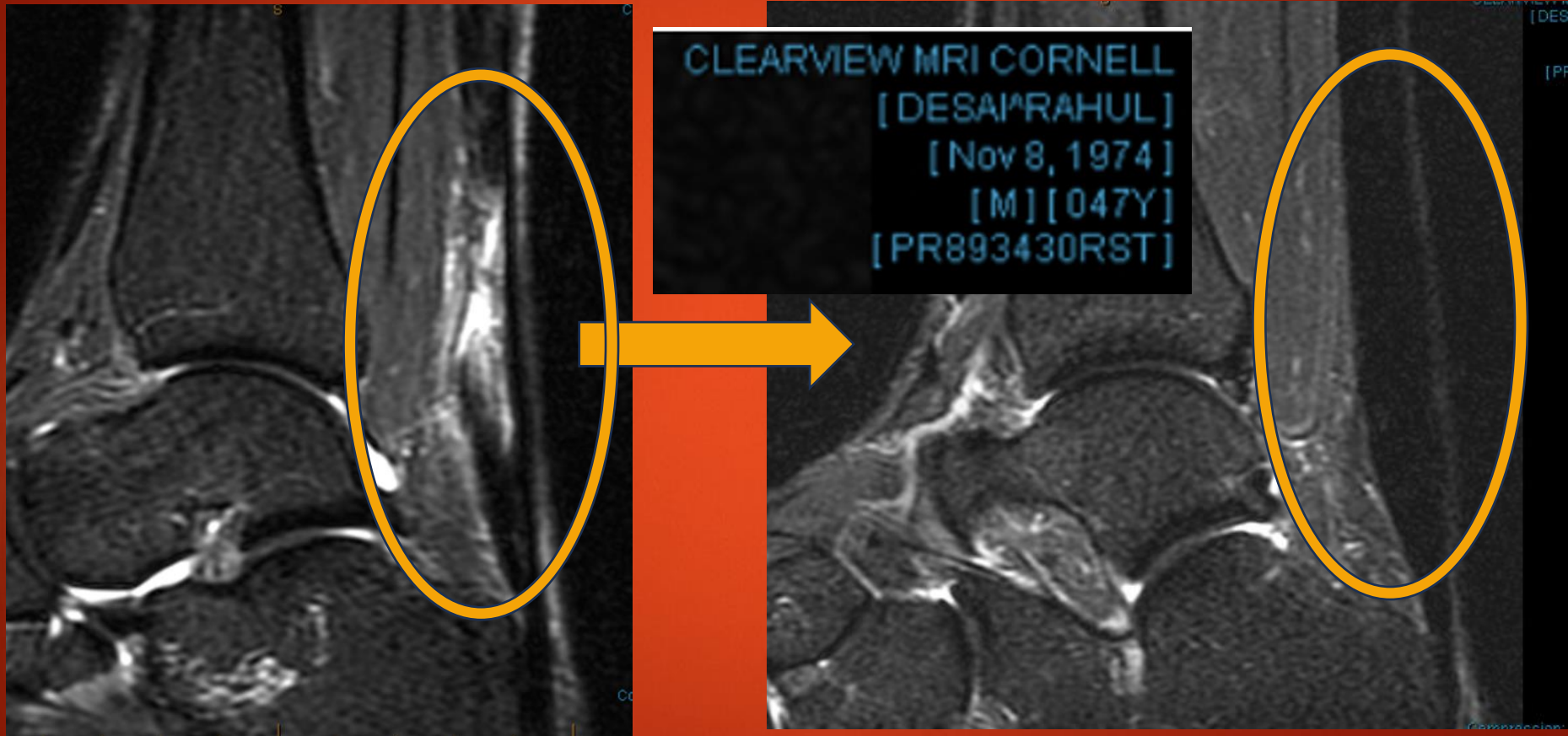
FFS  
Series no: 3  
FOV: 100



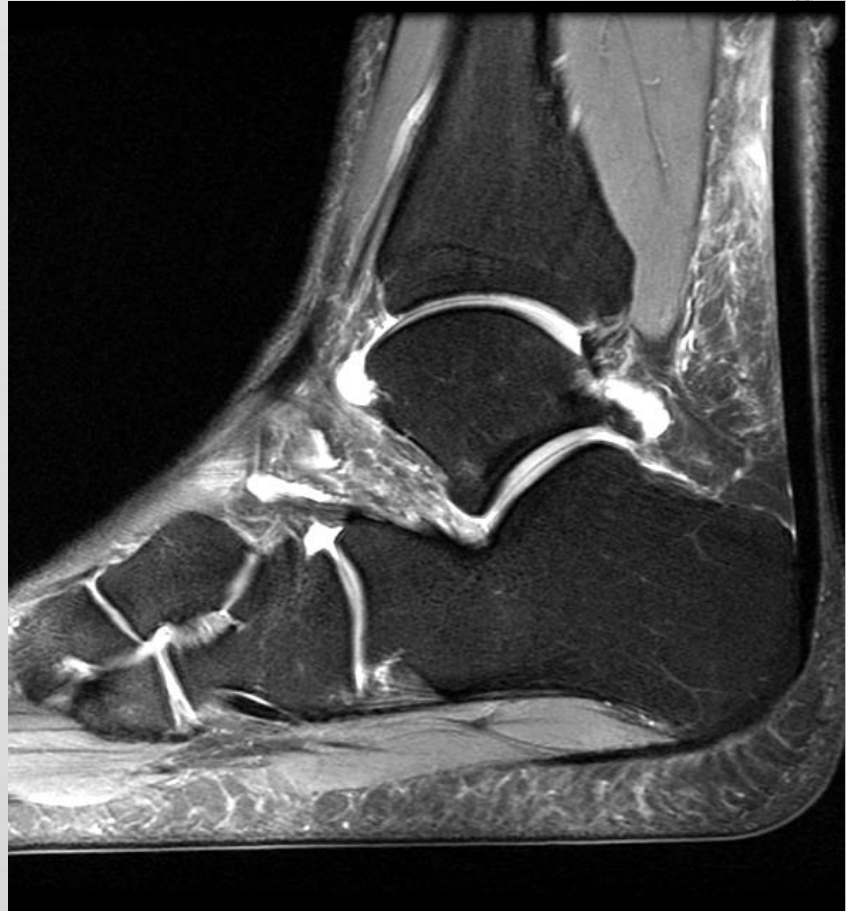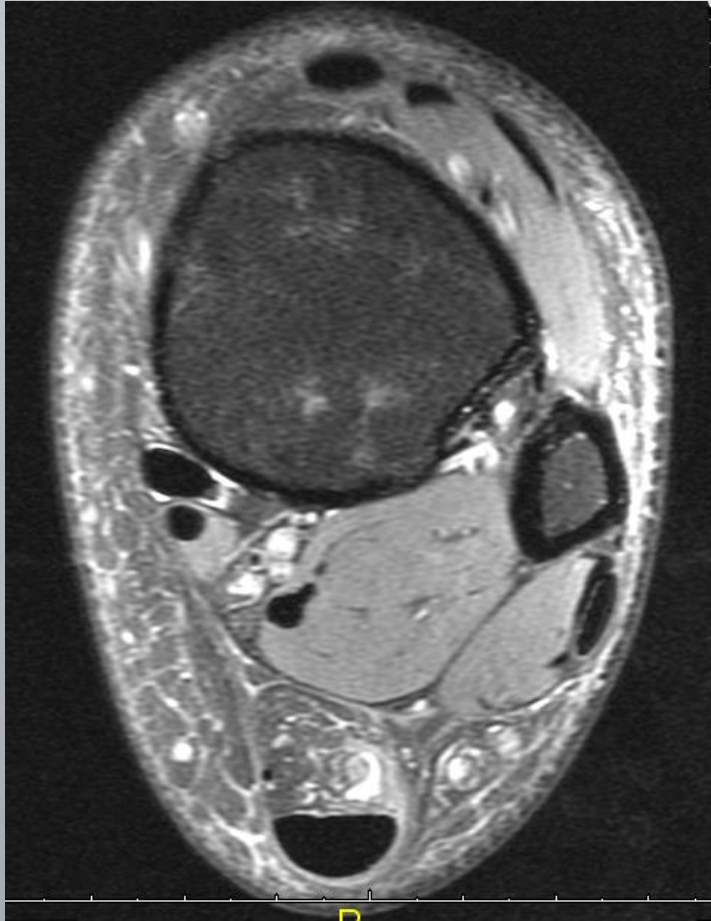
# 47 yo m achilles tendinopathy & tear

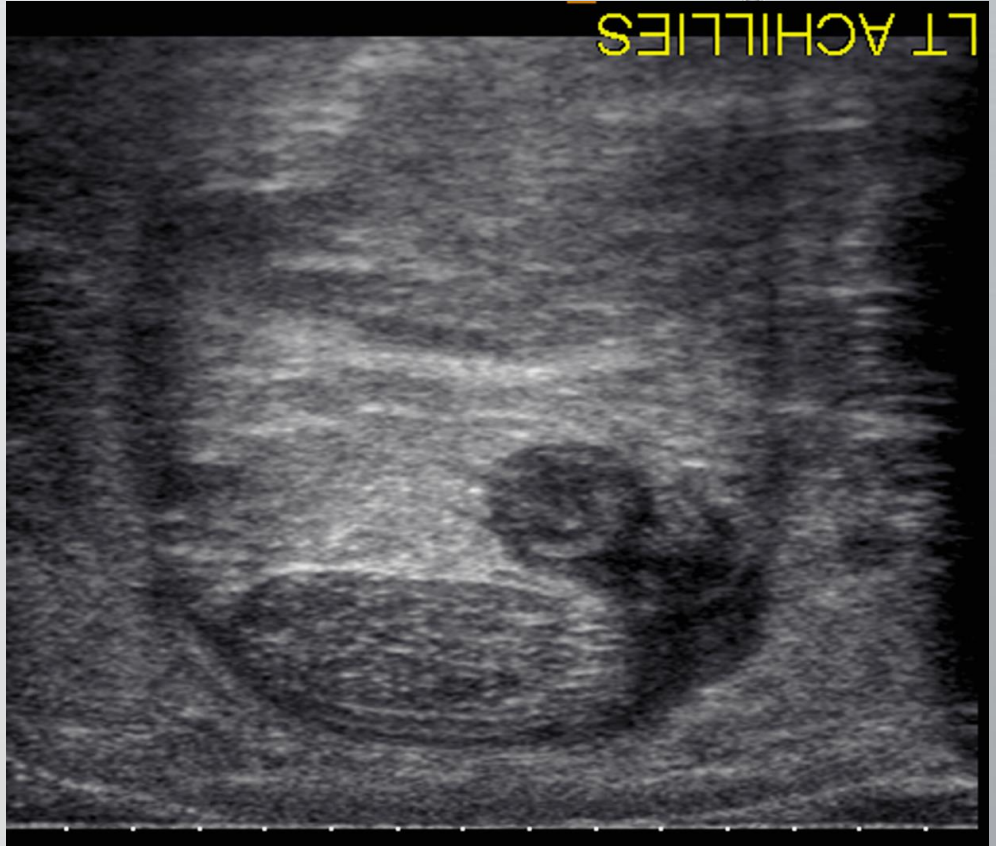
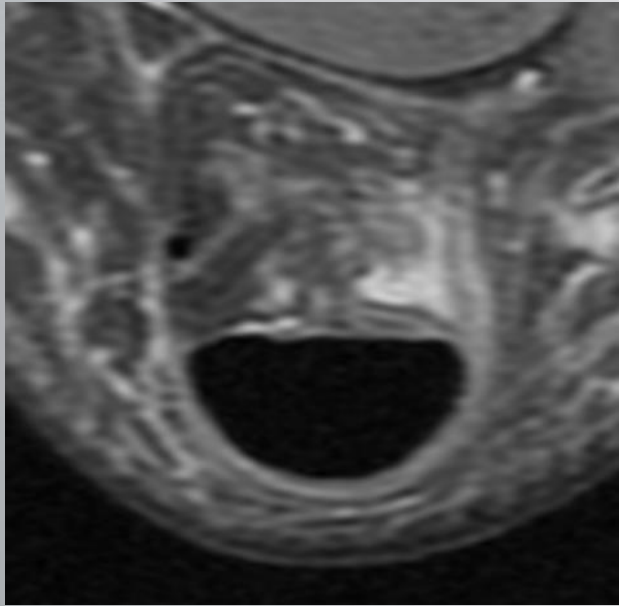
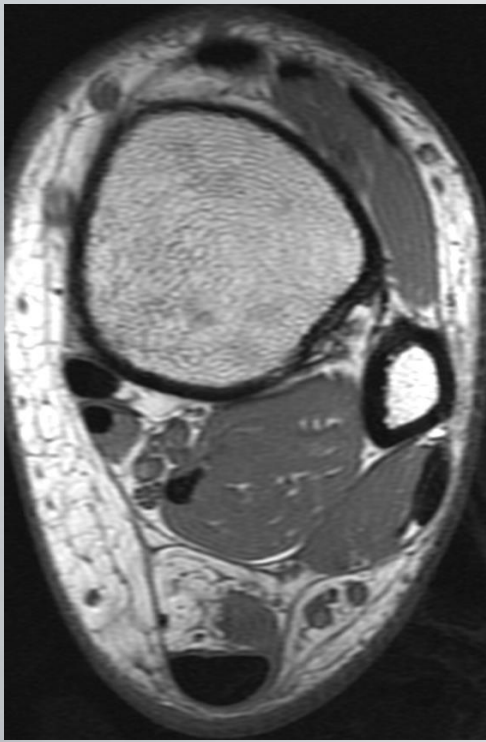


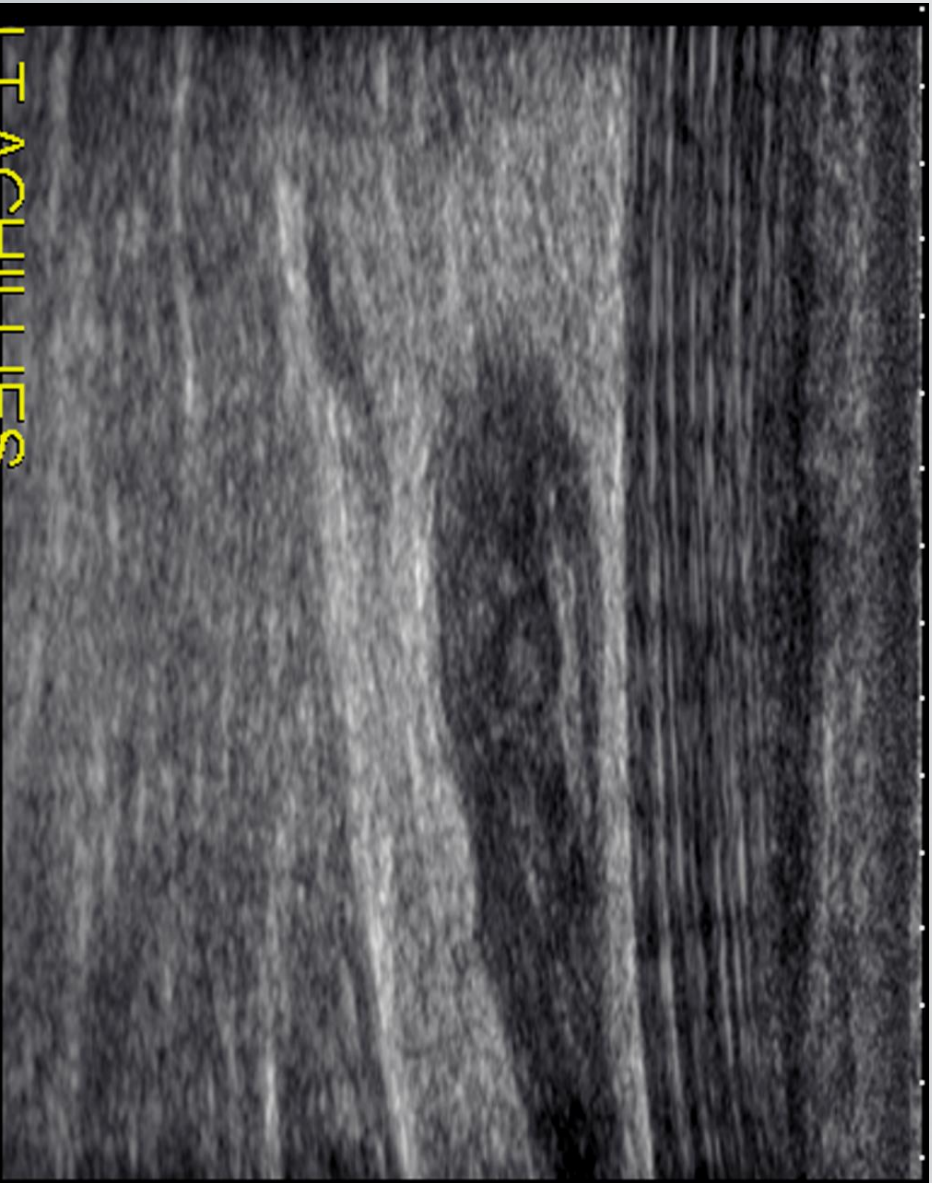
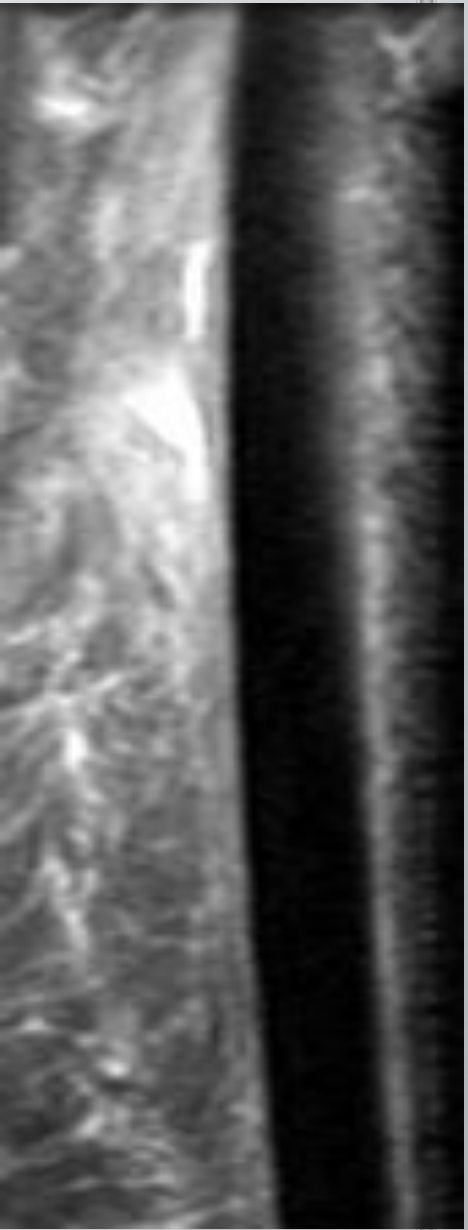
# Autologous Intra-lesional BLP



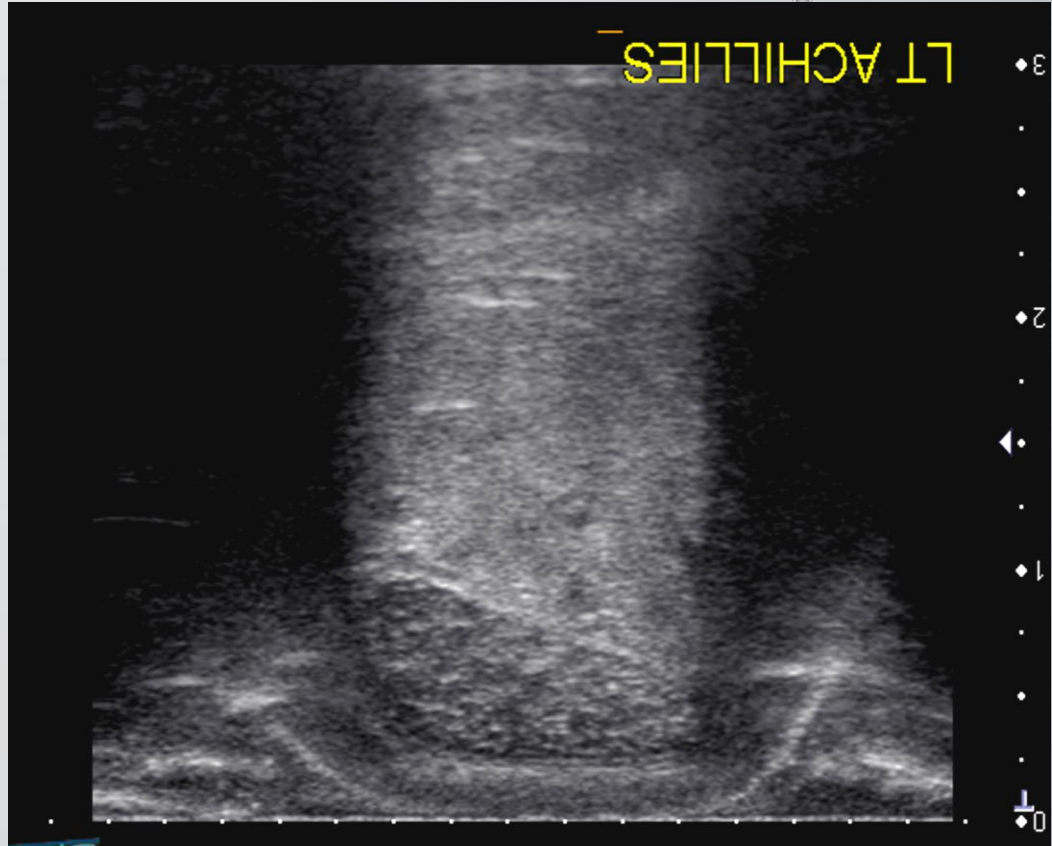
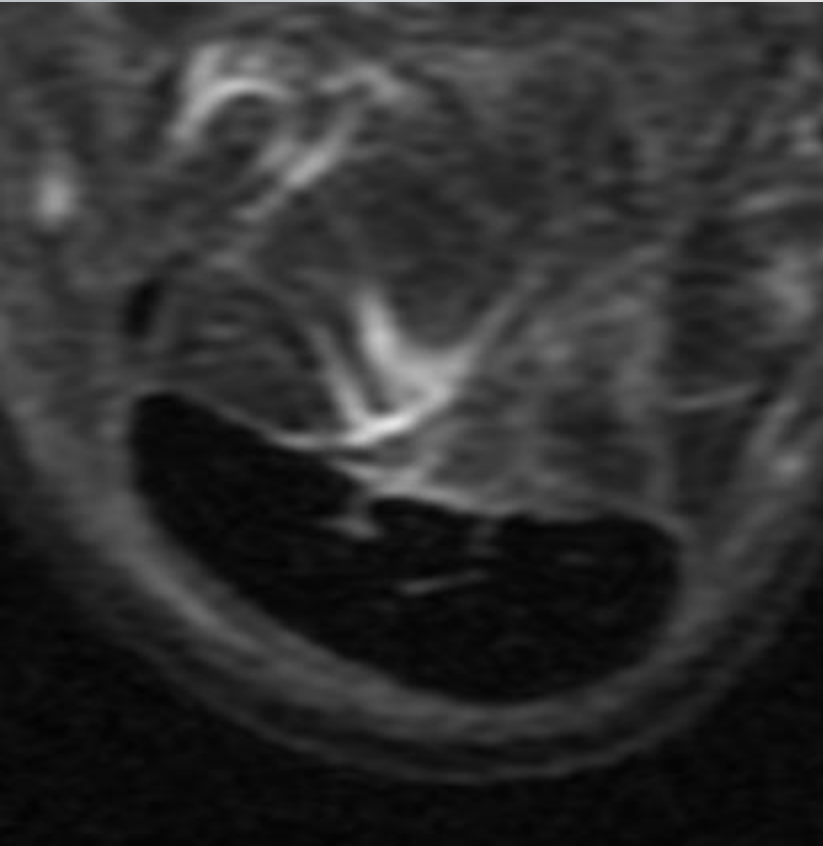
35 yo runner

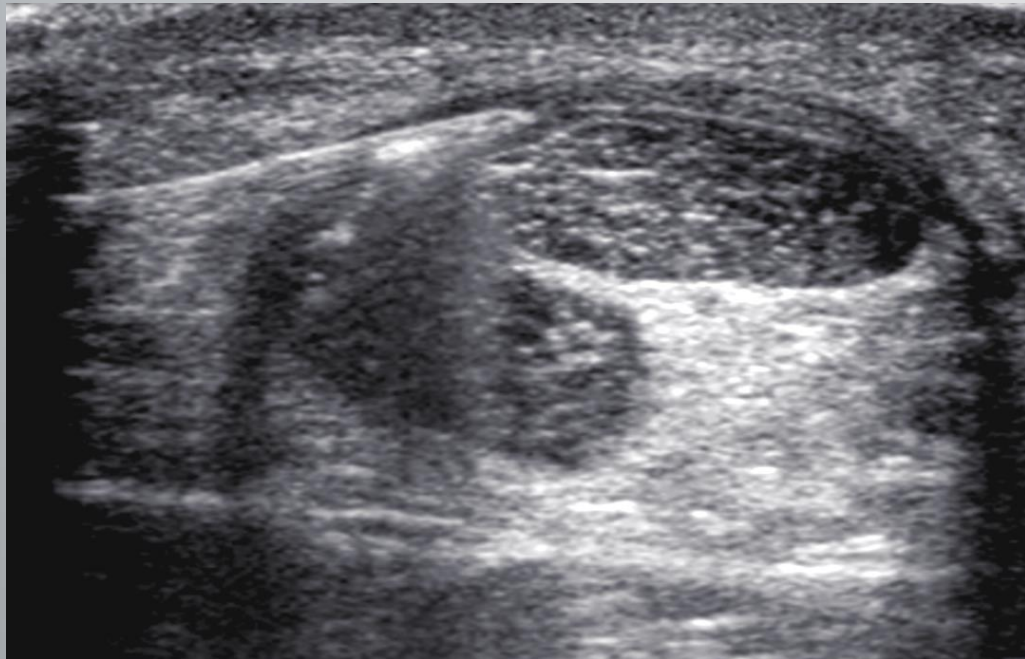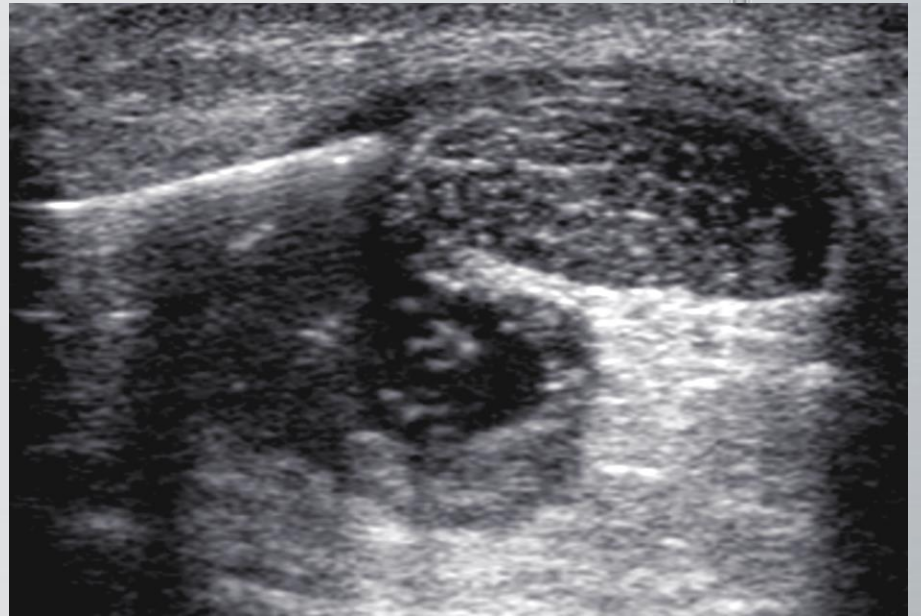
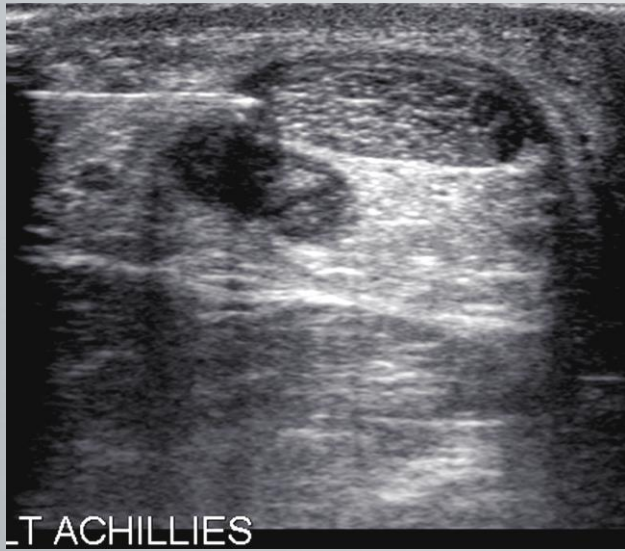



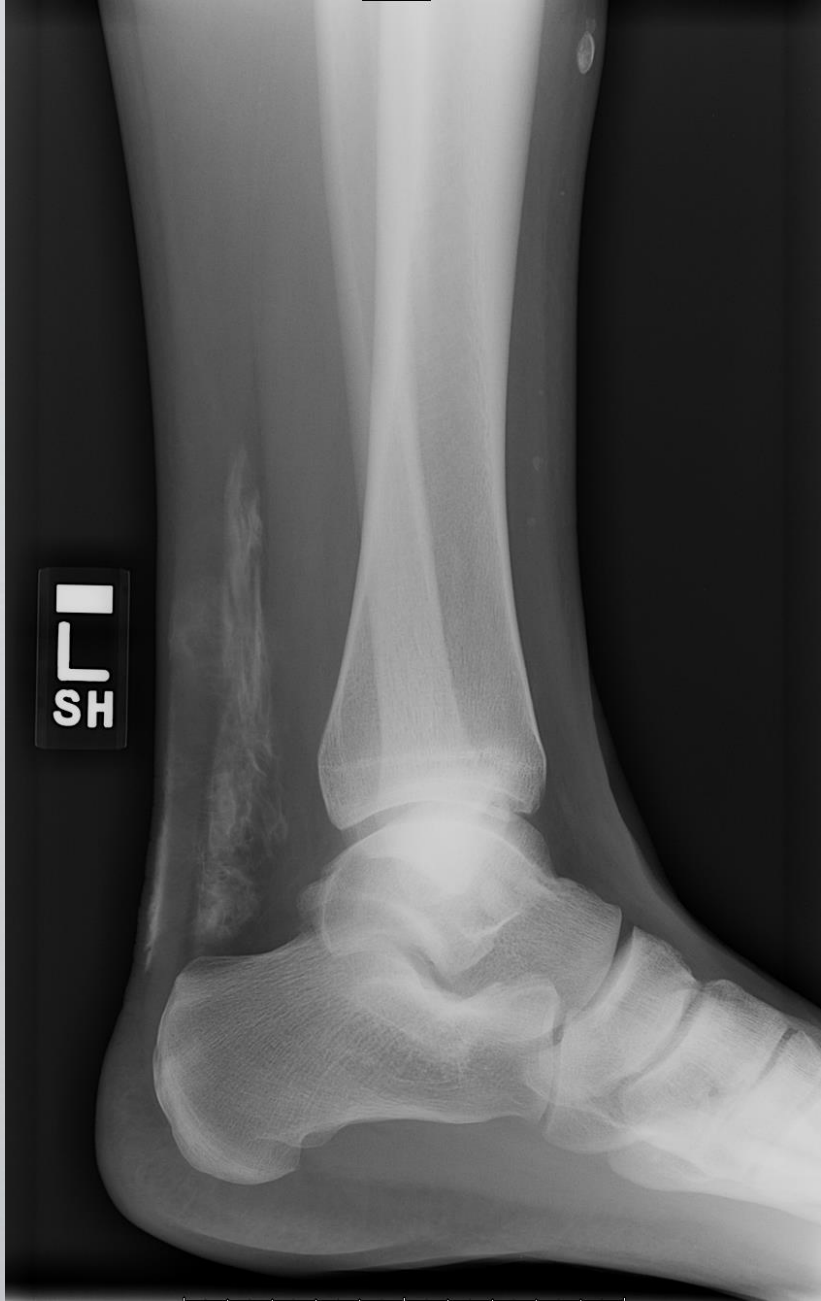


LT ACHILLIES



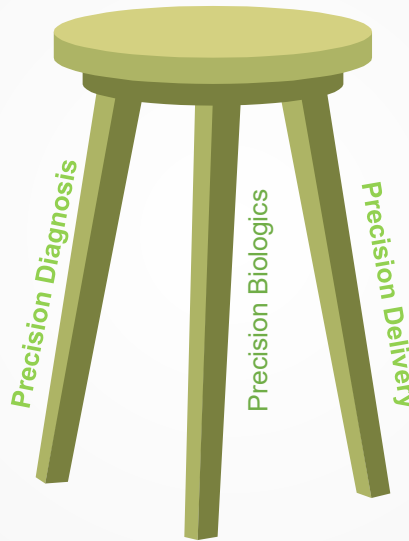



# Successful Regenerative Medicine Therapy

## Precision Diagnosis

History, Physical Exam,  
Diagnostic Imaging &  
Injections

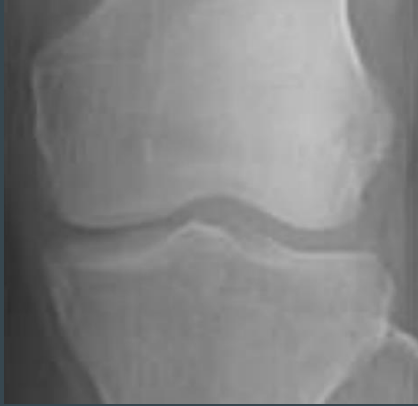

## Precision Delivery

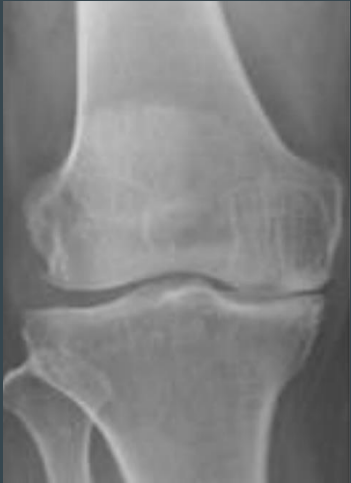Image guided placement of  
needle/therapy into injured  
tissues

## Precision Biologics

The best biologic for the  
injury or disease process



Growth Factors

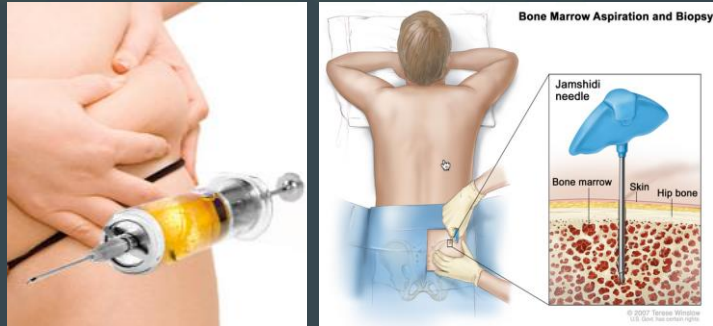


Cell Therapy

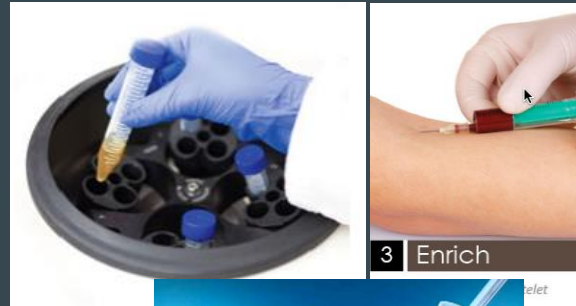

# CELLULAR THERAPY

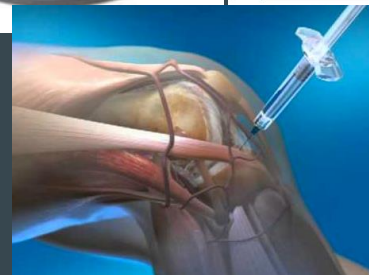1



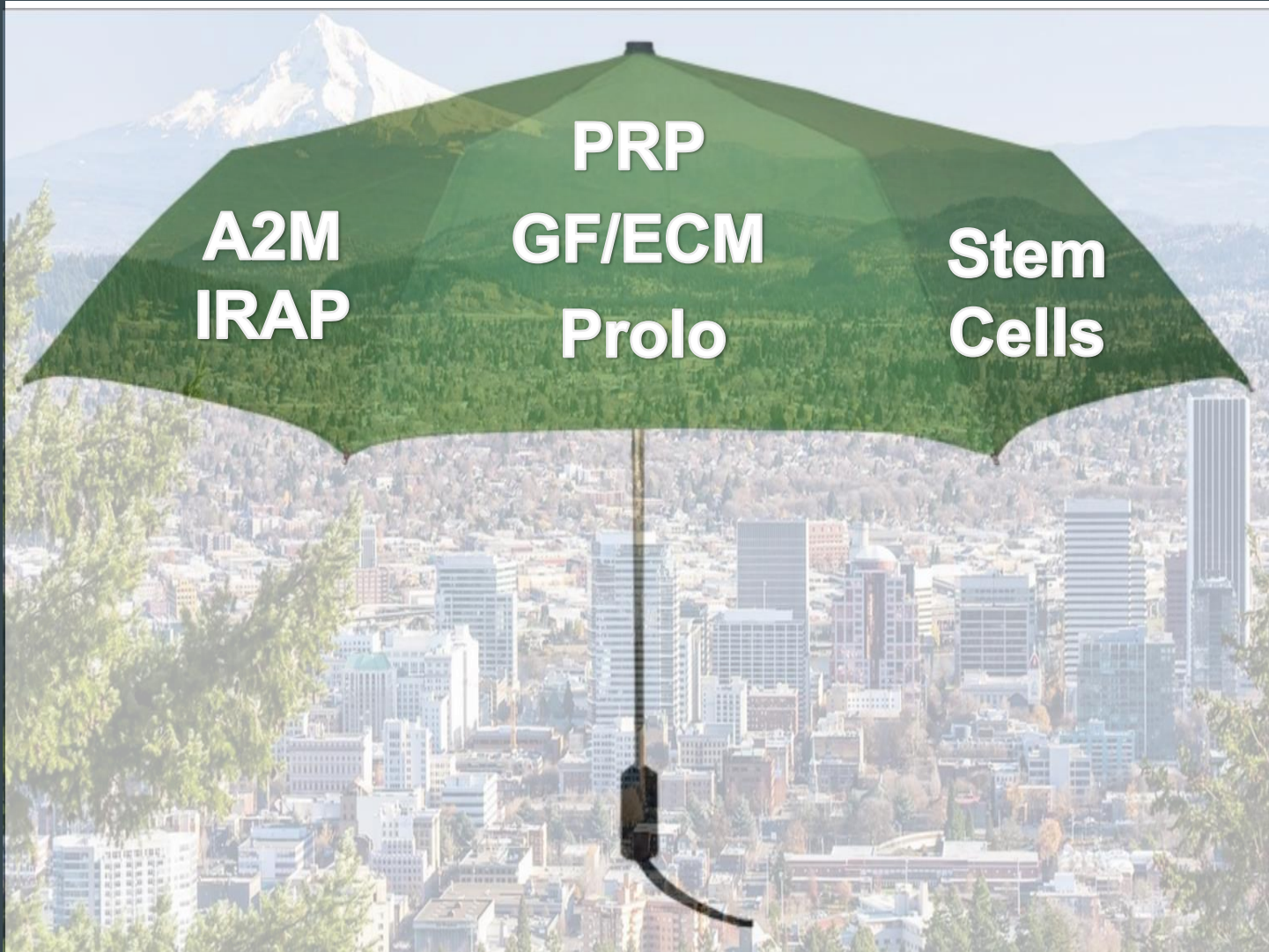
2



3







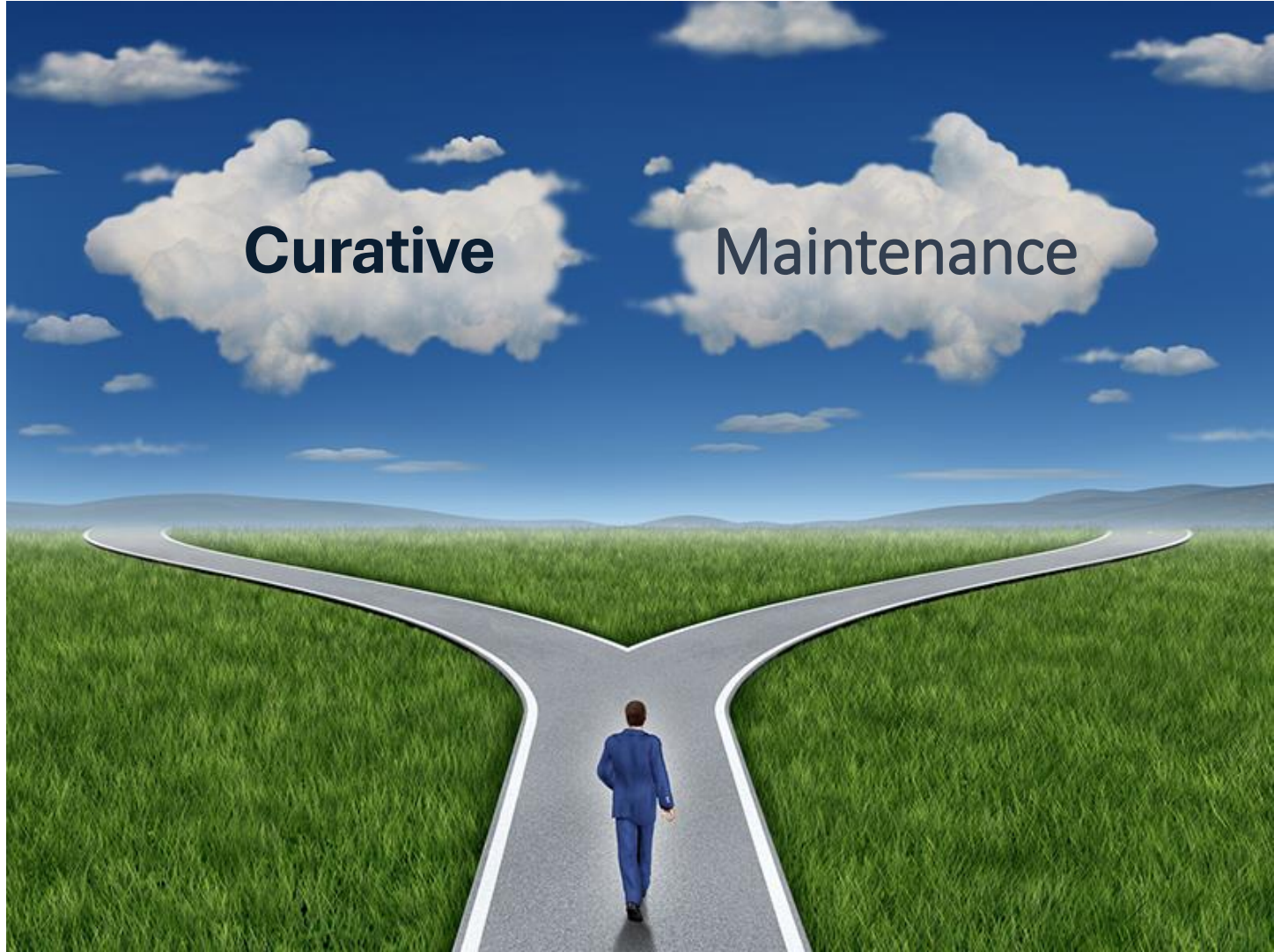**A2M**  
**IRAP**

**PRP**  
**GF/ECM**  
**Prolo**

**Stem**  
**Cells**

**Curative**

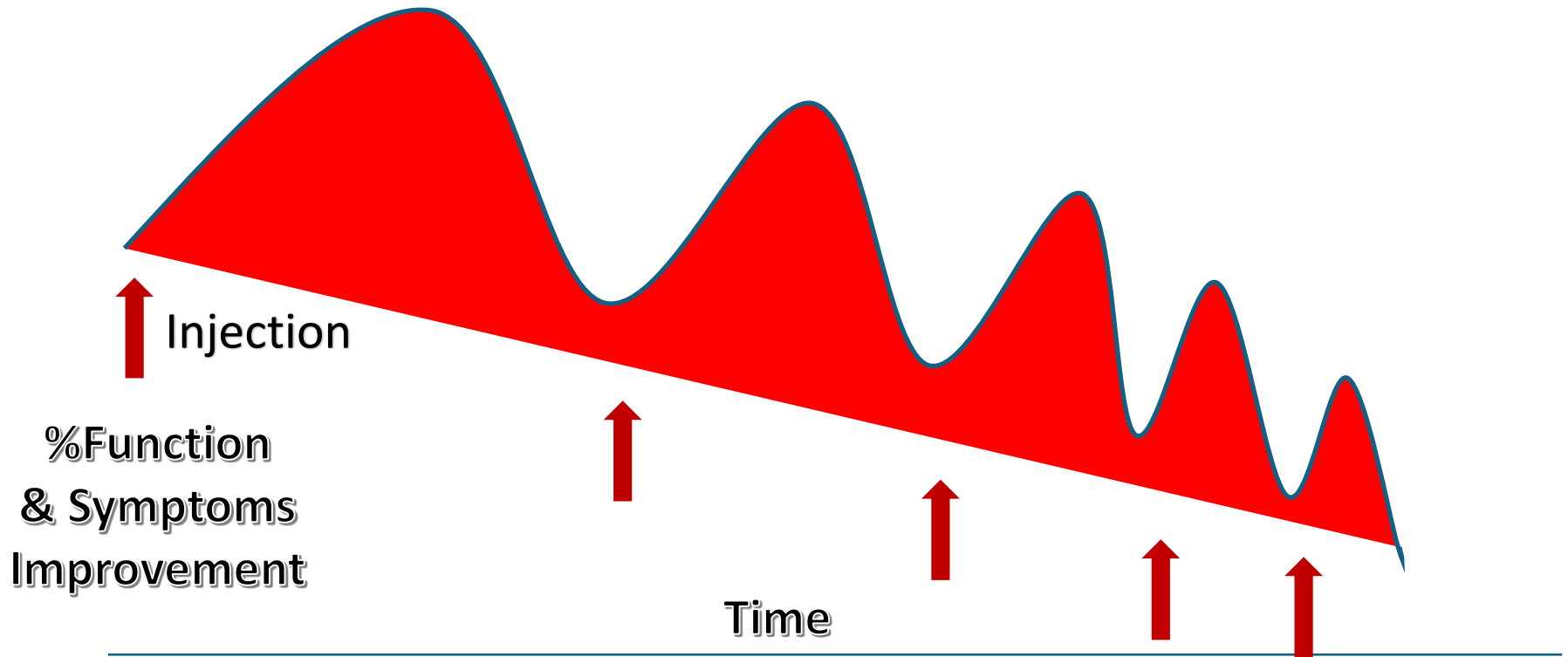
**Maintenance**



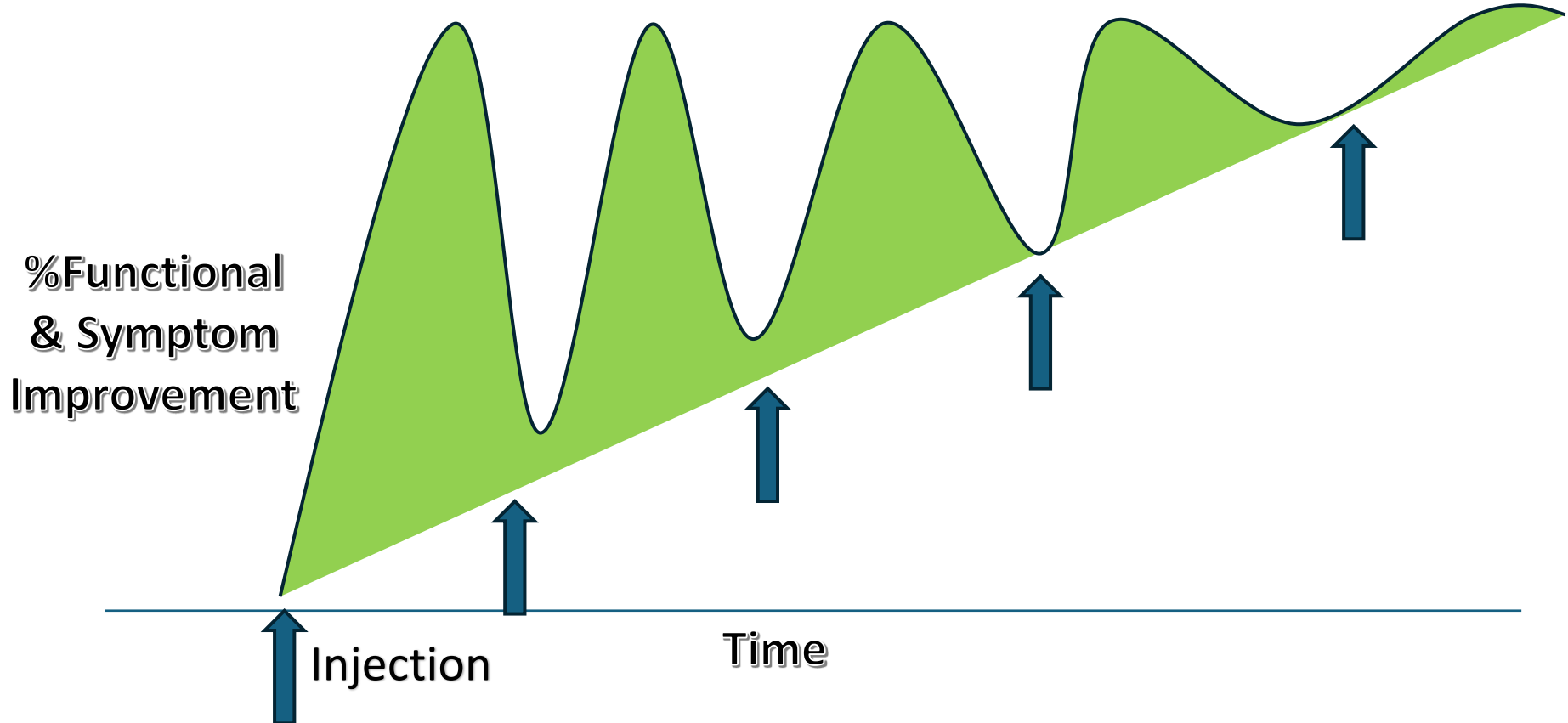


Close only  
Counts in  
Horseshoes,  
Hand-Grenades  
and.....  
**STEROIDS**

# Steroid Diminishing Returns

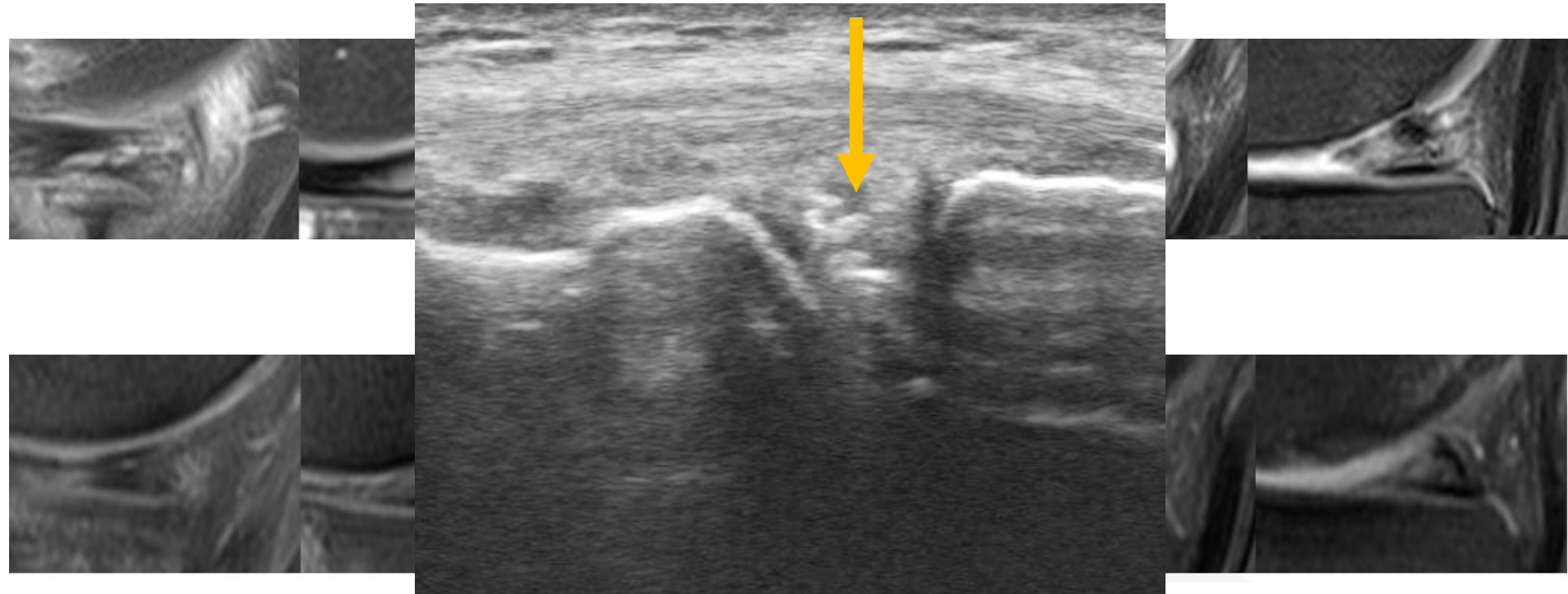


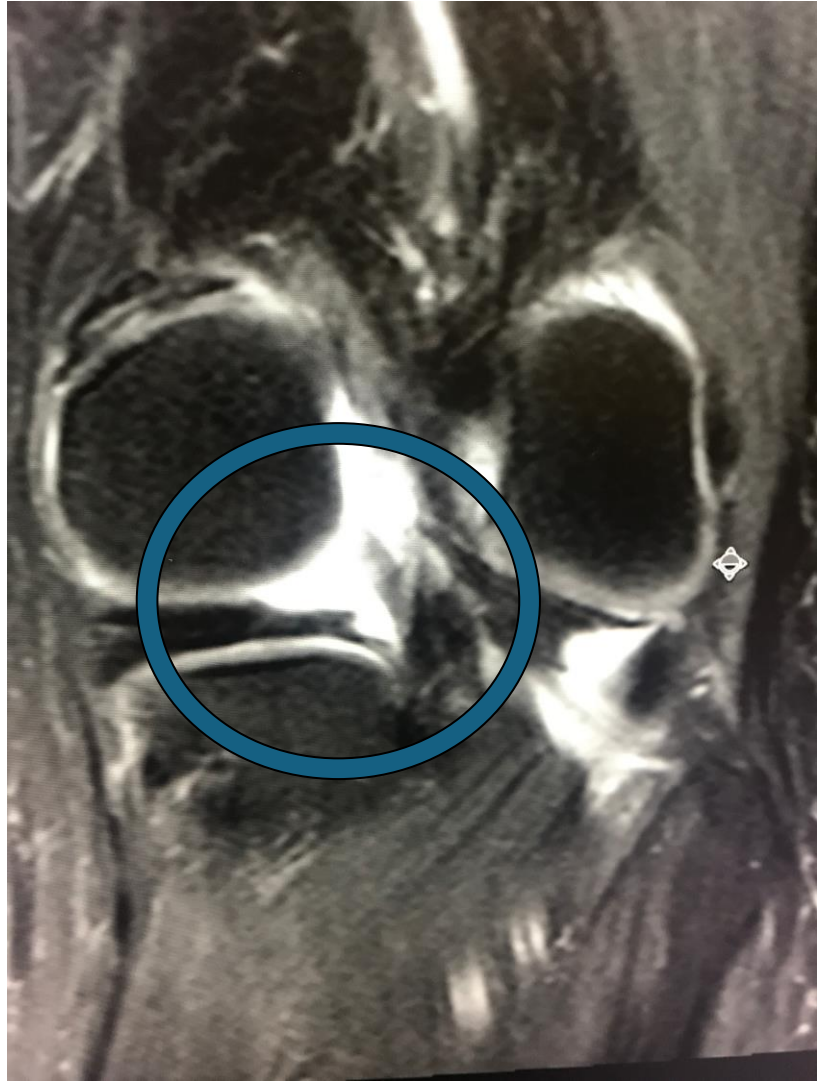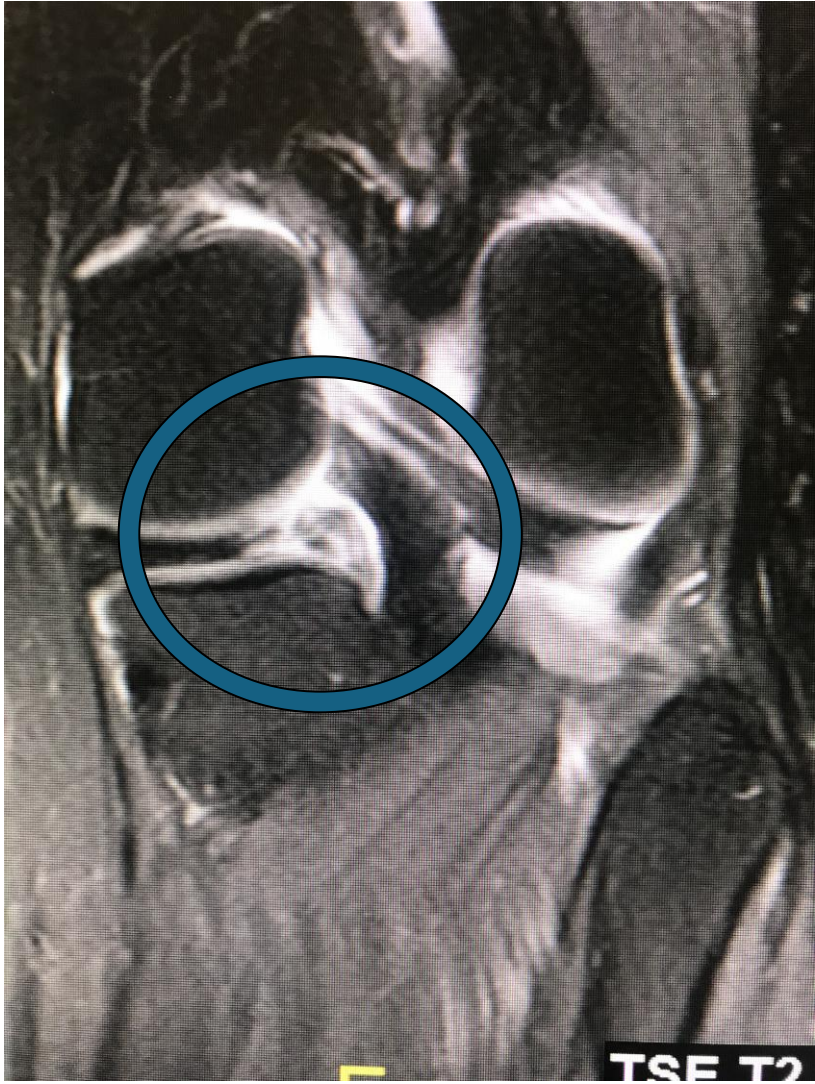
# Regen Cumulative Benefits

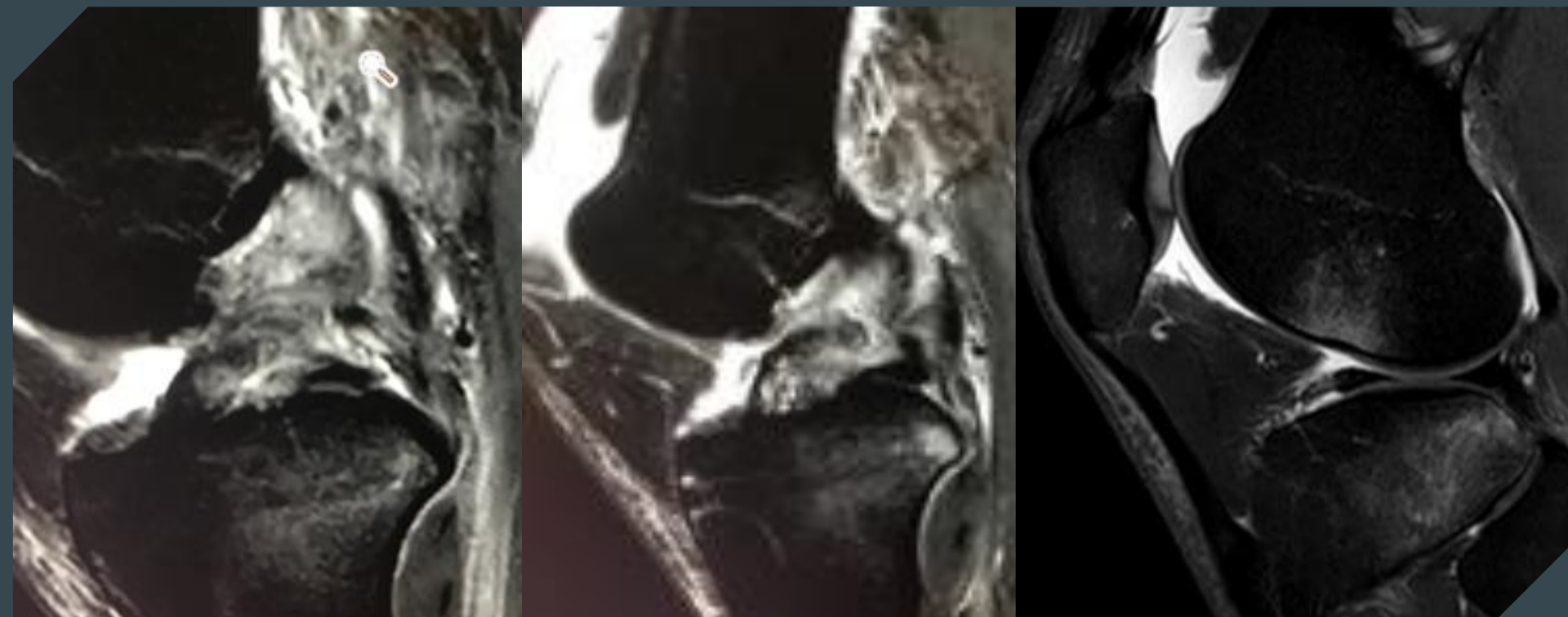


Our Talk is about  
the  
**POSSIBILITIES!**

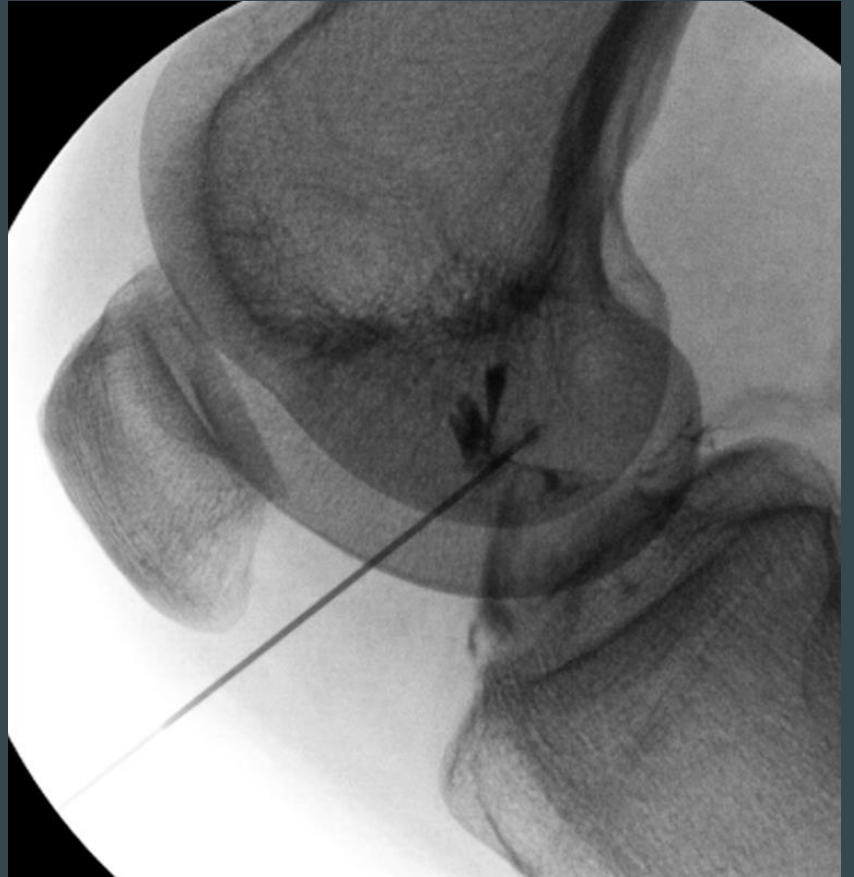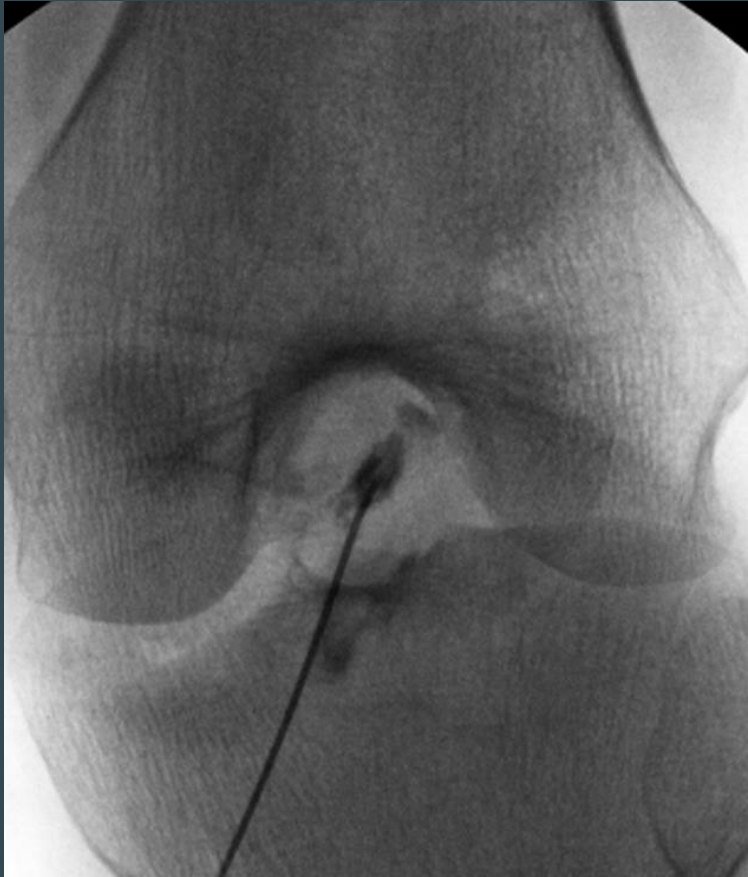# Intra-Mensical Therapy

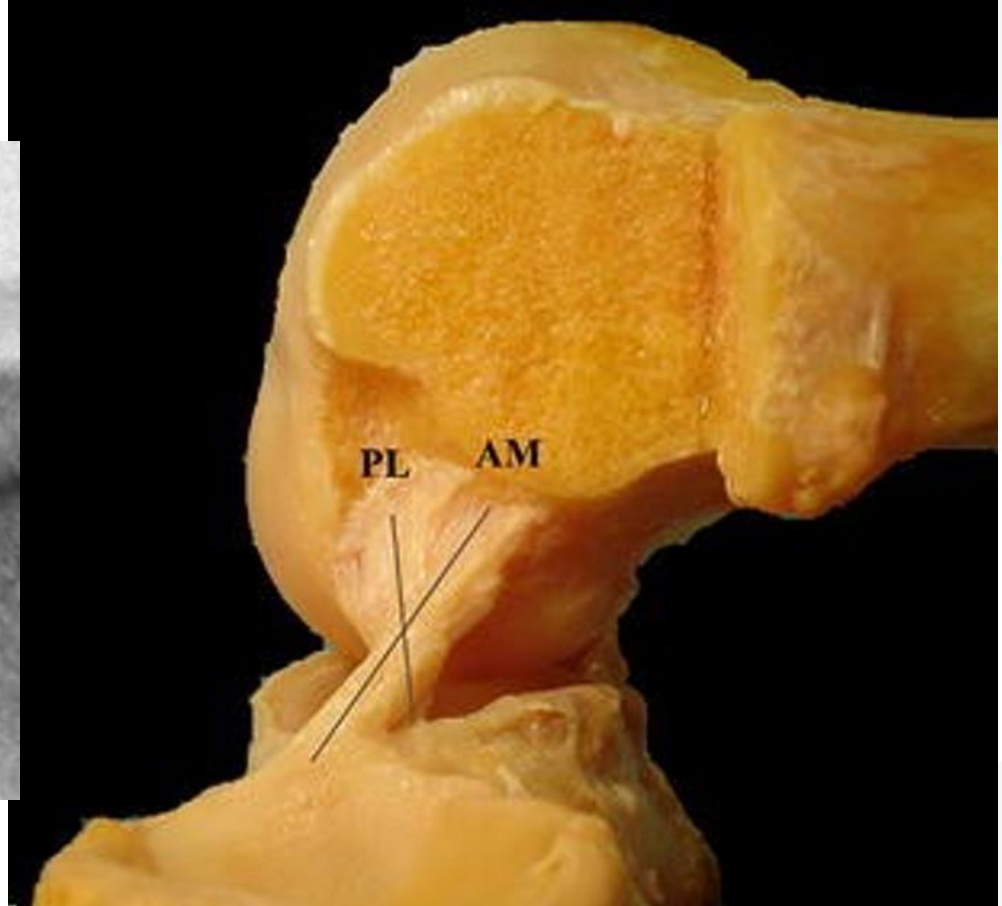
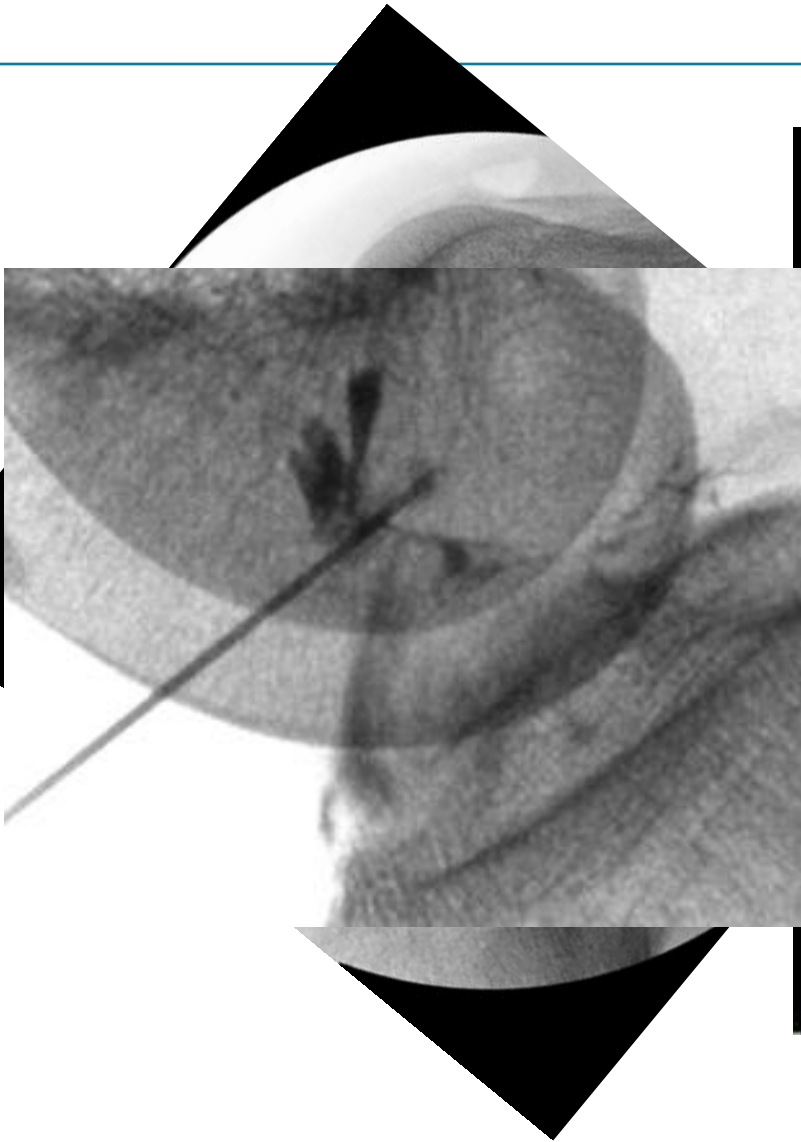



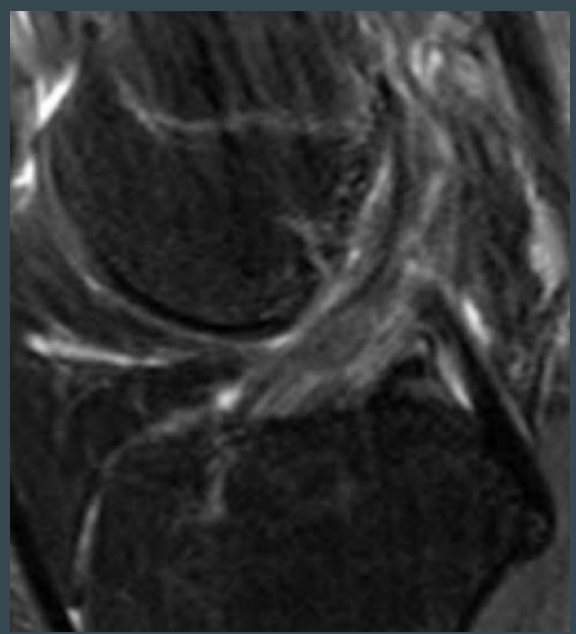
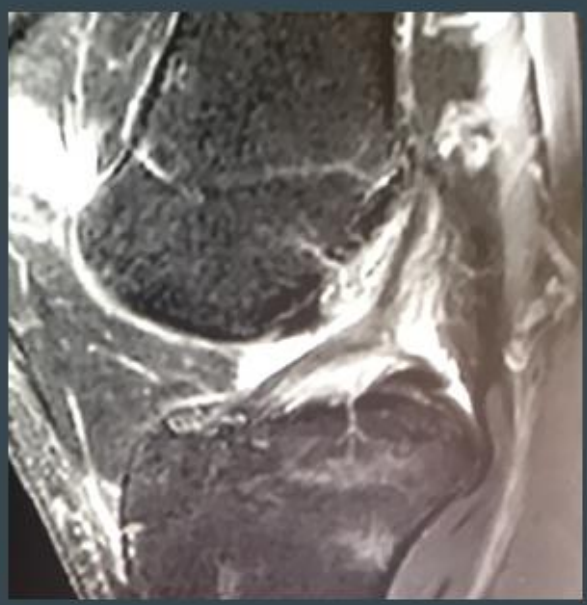
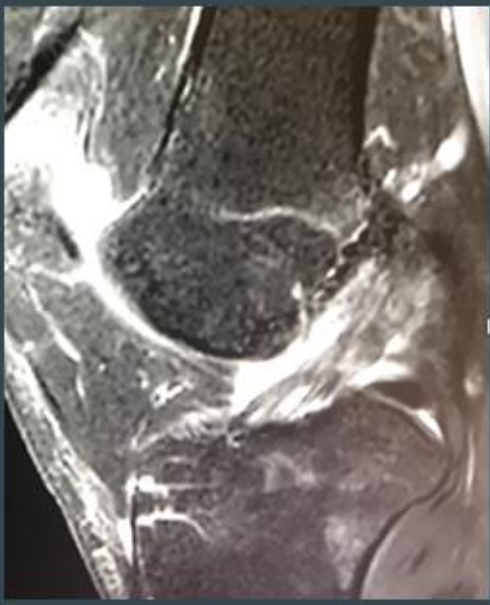
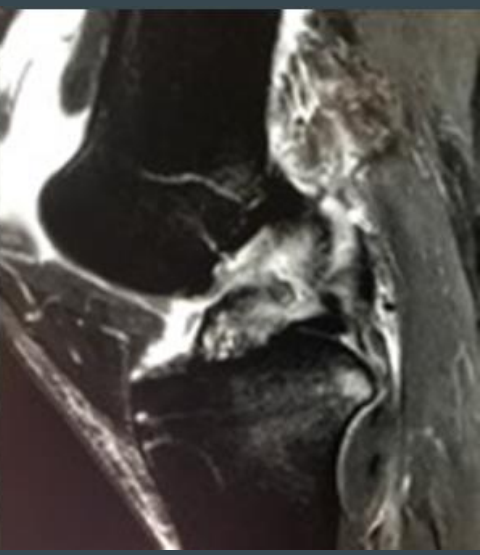
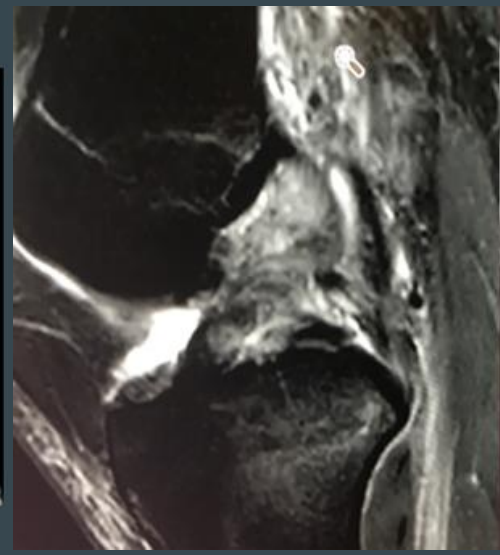
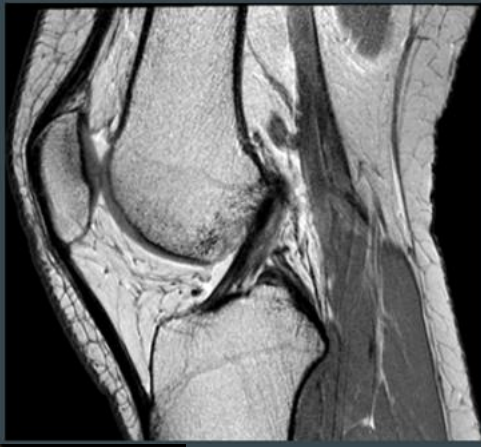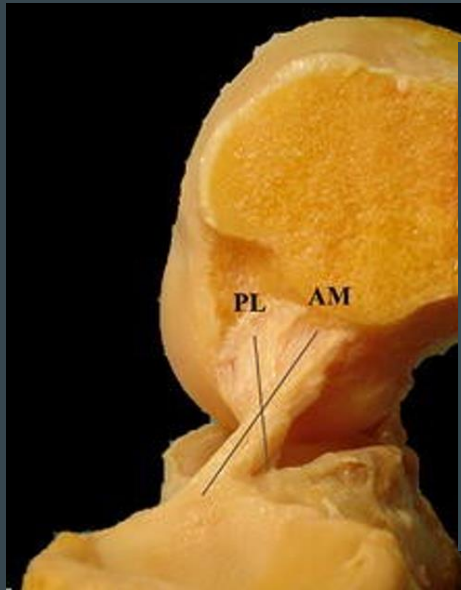


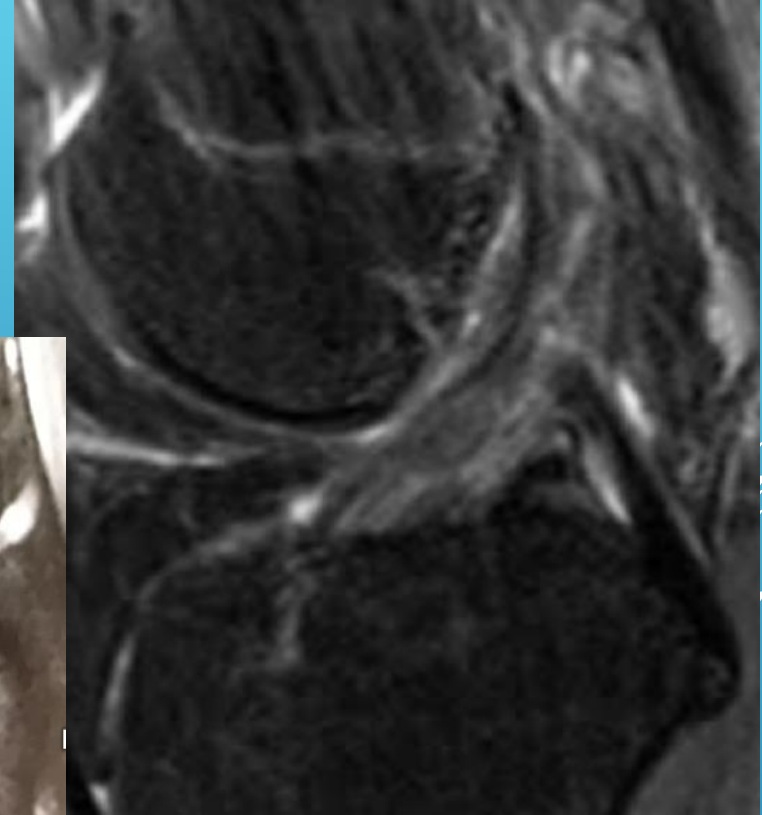
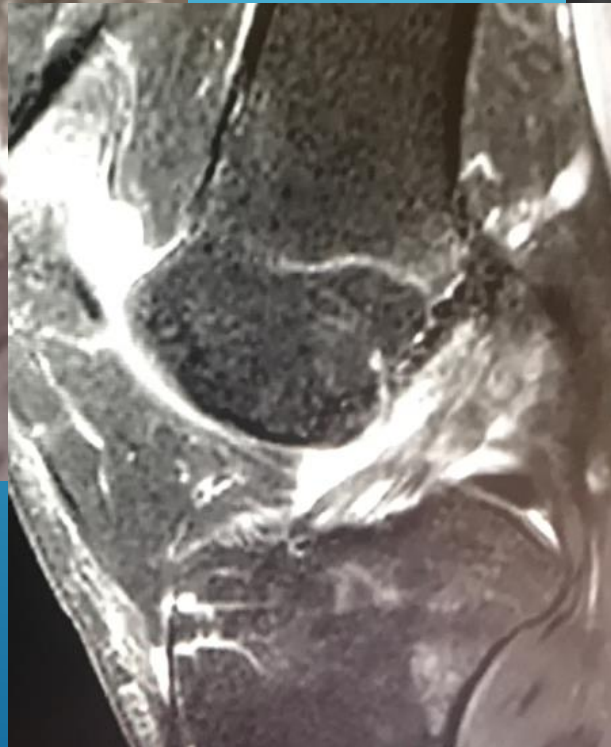
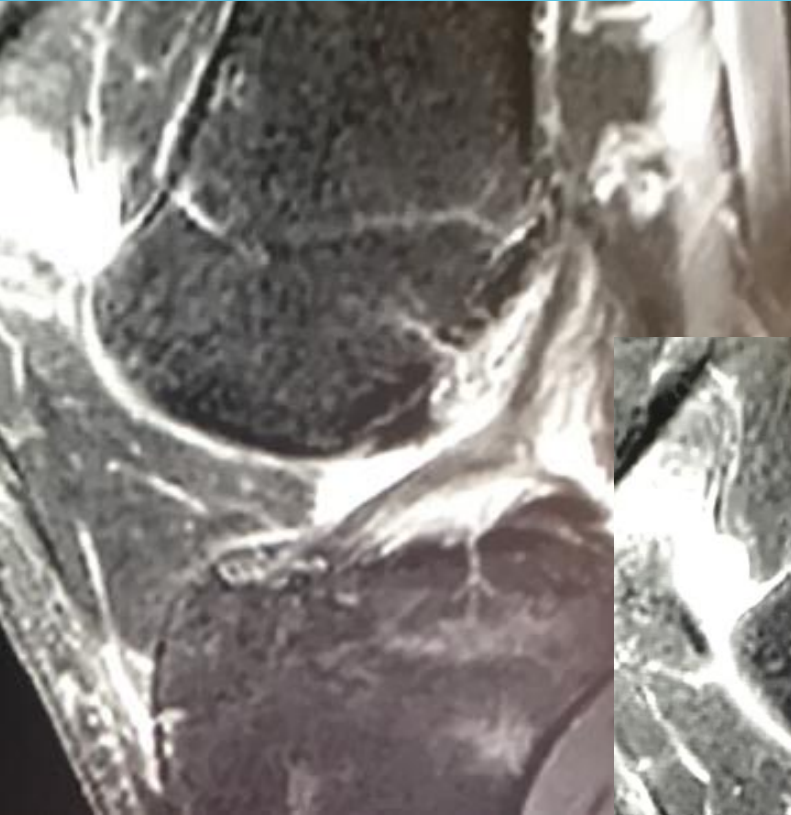
**Complete ACL tear?**






NORMAL ACL

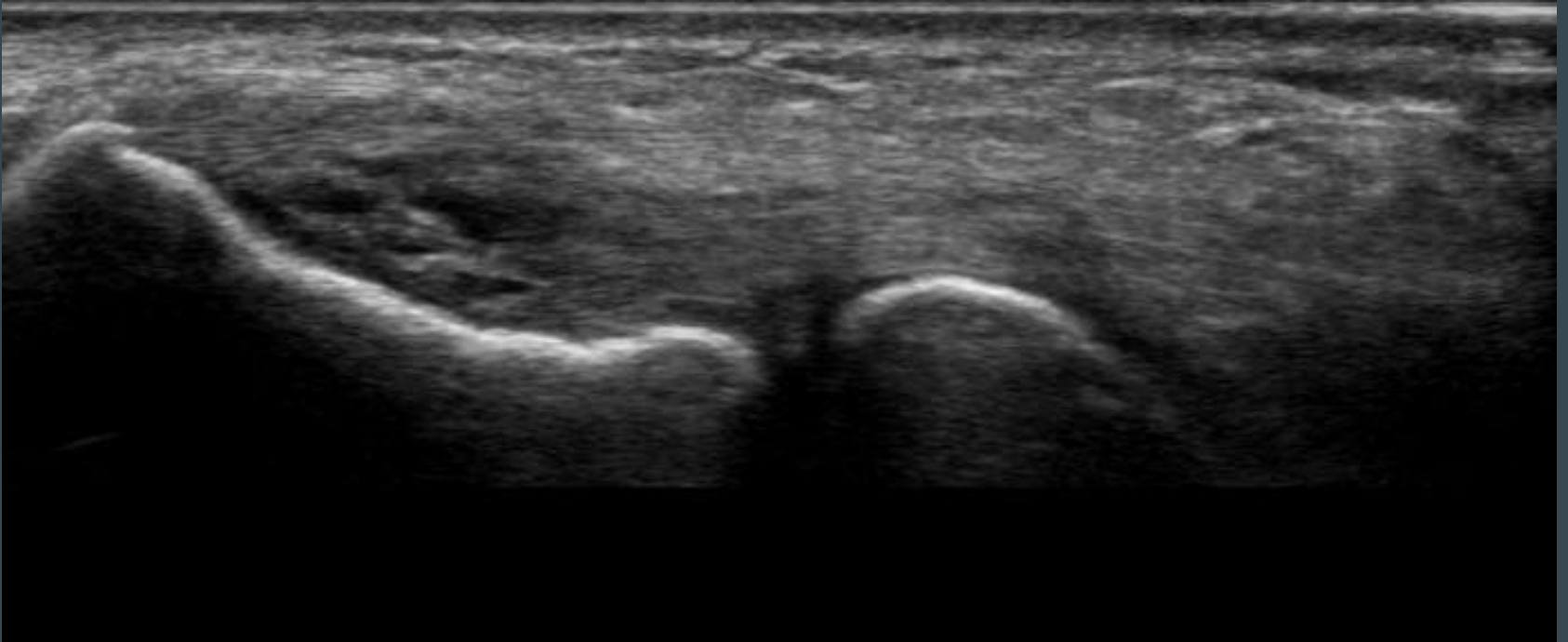




# Ligament Healing Biologically Active Scaffold

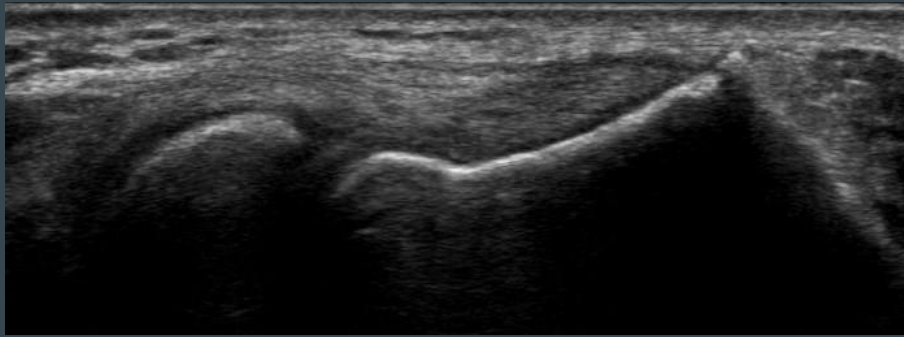

# Combo Therapy –

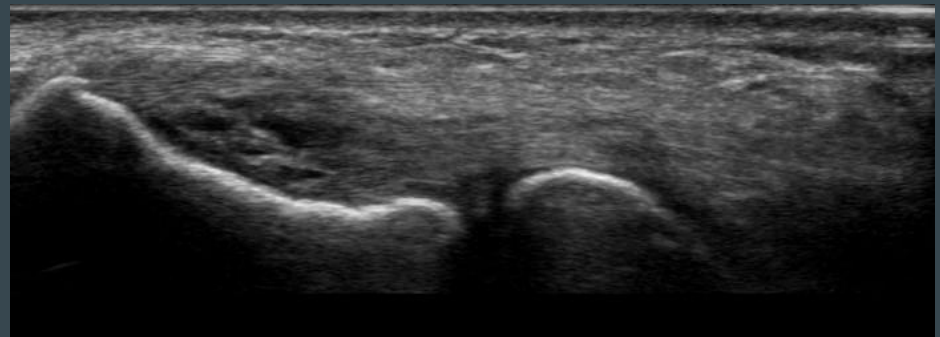


# Diagnostic Ultrasound

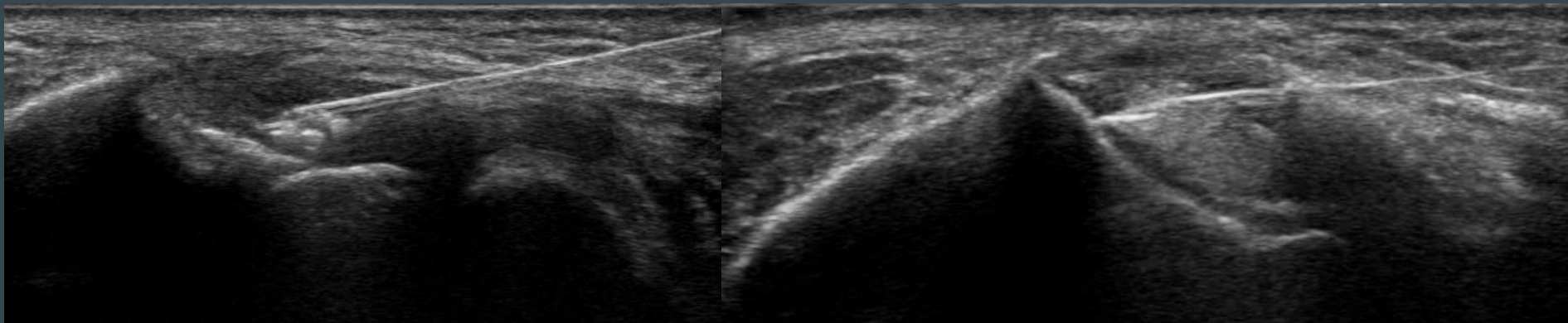
Left Side: Asymptomatic



Right Side: Symptomatic

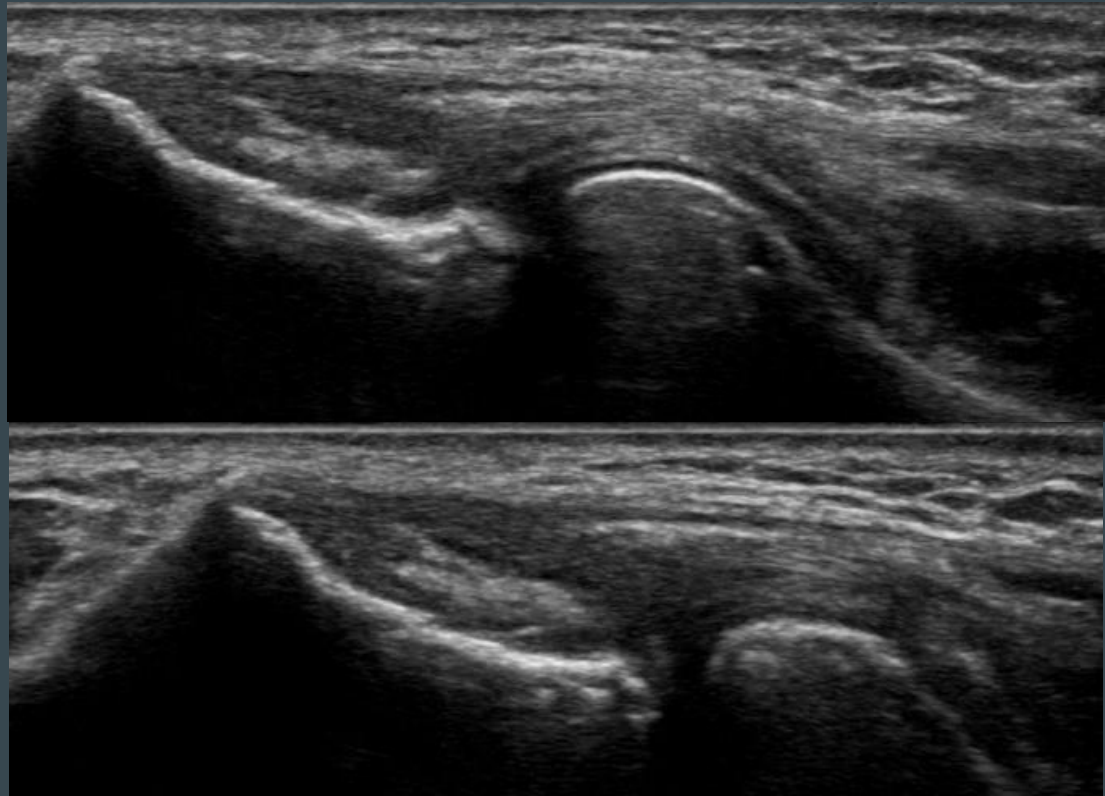


# Intervention



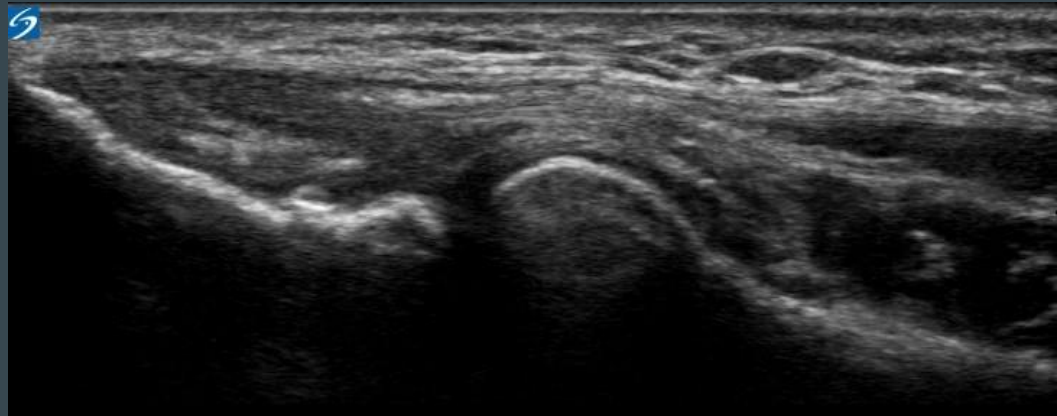
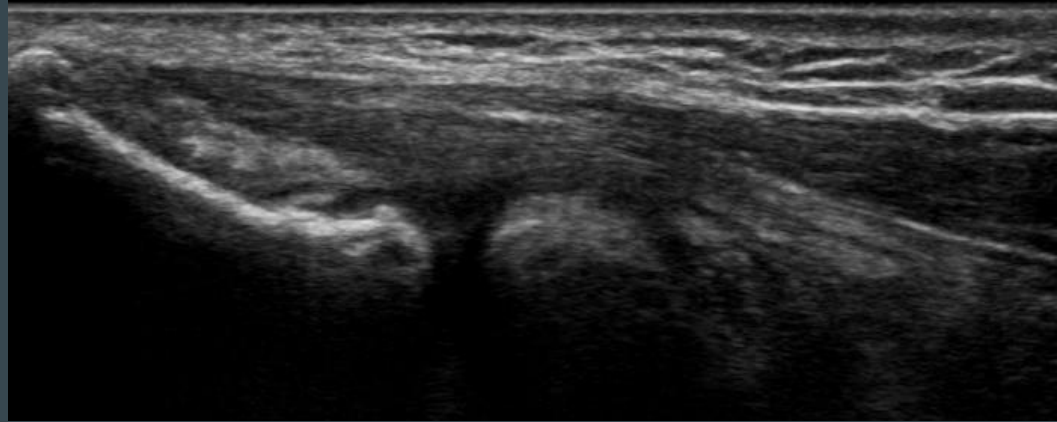
## Follow up- 3 months post

- 0/10 pain score at visit
- At worse 3/10 pain with repetitive motions, overall less severe and less frequent
- 80% improvement
- Increased function
- Continuing PT and meeting all milestones, ready for discharge



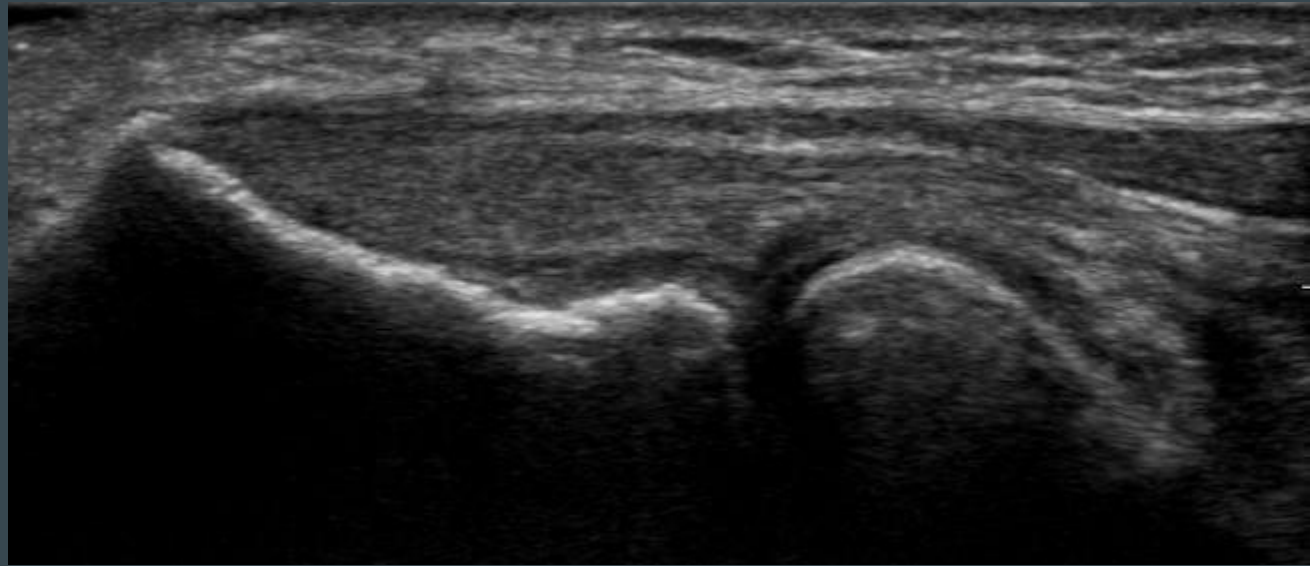
## Follow up-4.5 months post

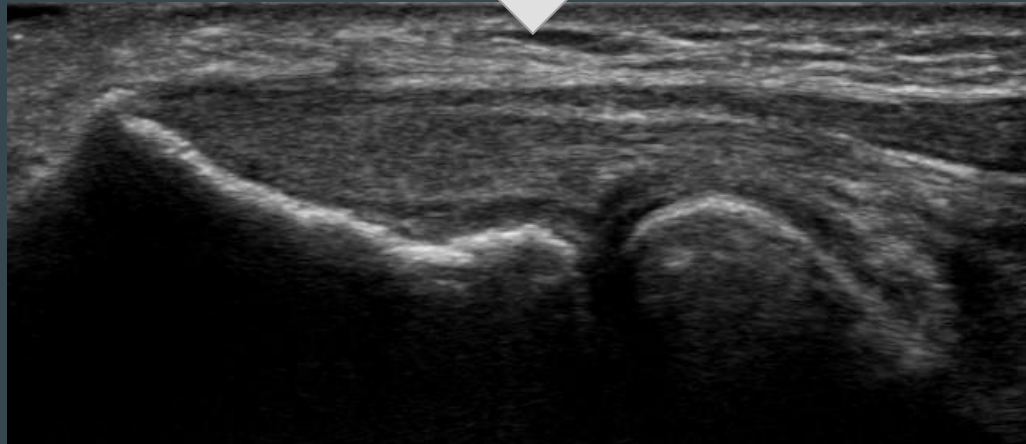
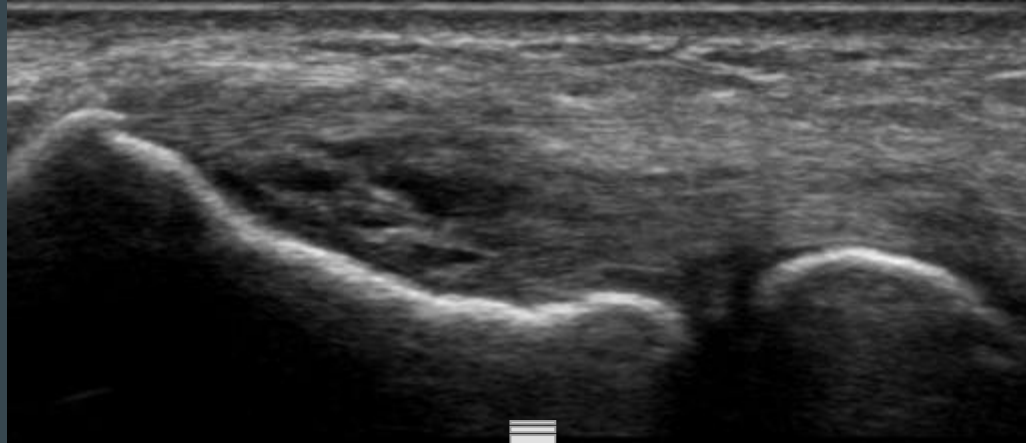
- Continued improvement
- 0/10 pain daily
- Very occasional pain with repetitive wrist extension movements



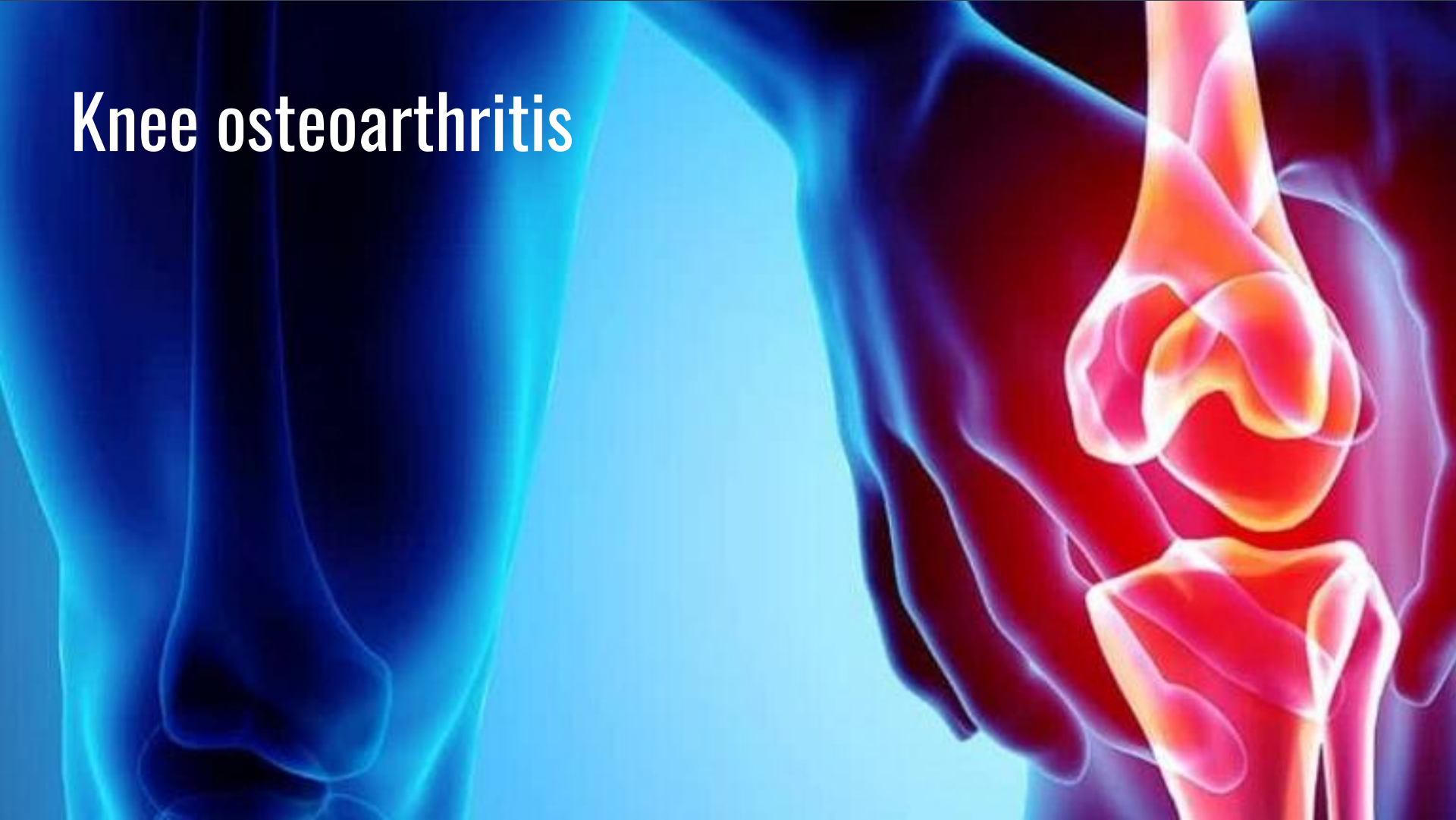# Follow up-9 months post

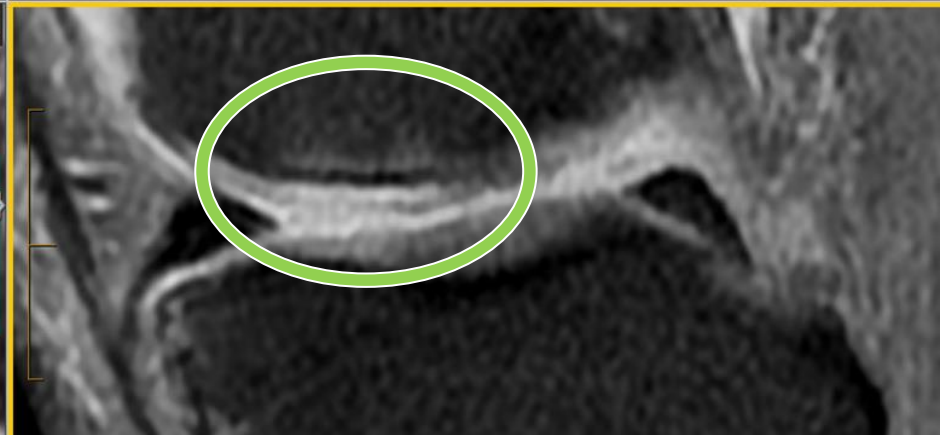
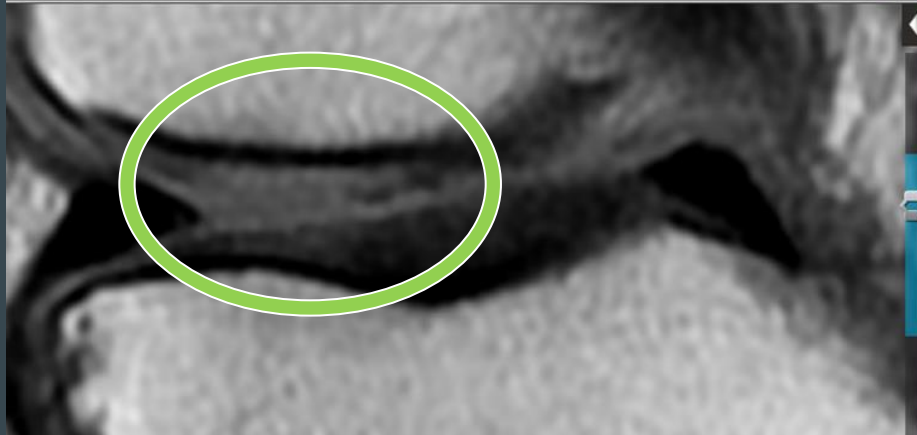
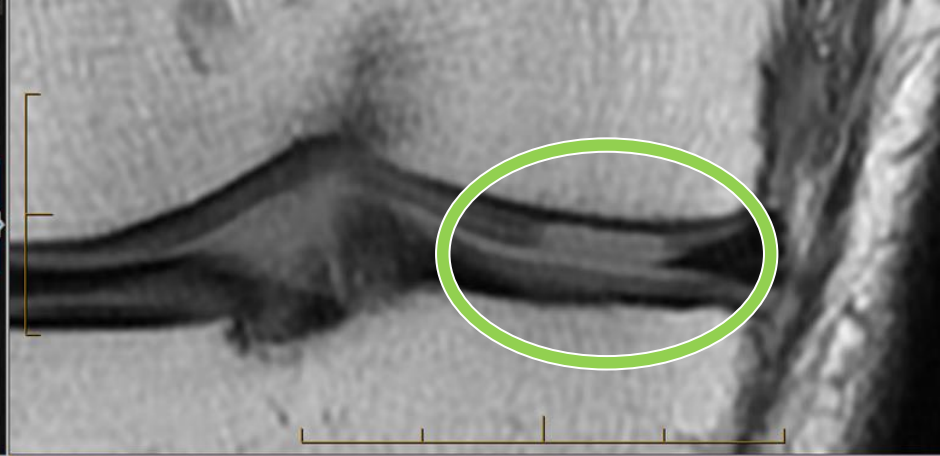
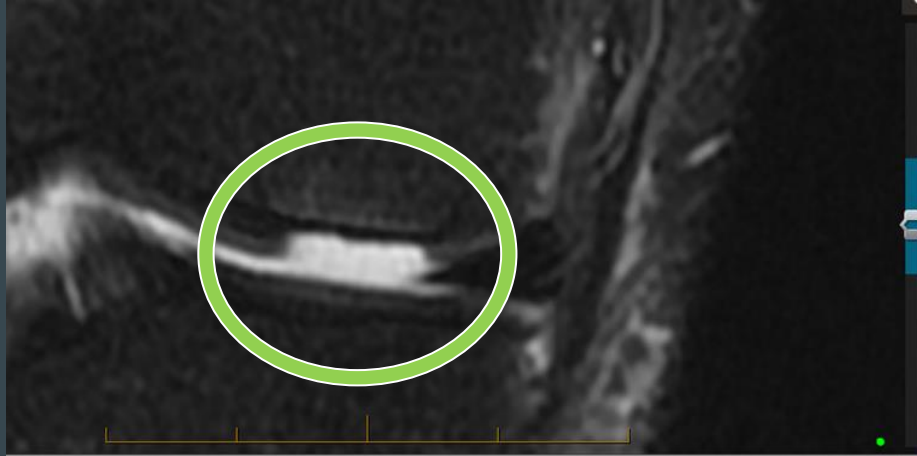
- 95% improvement
- Continuing to improve
- No pain and no pain with activities

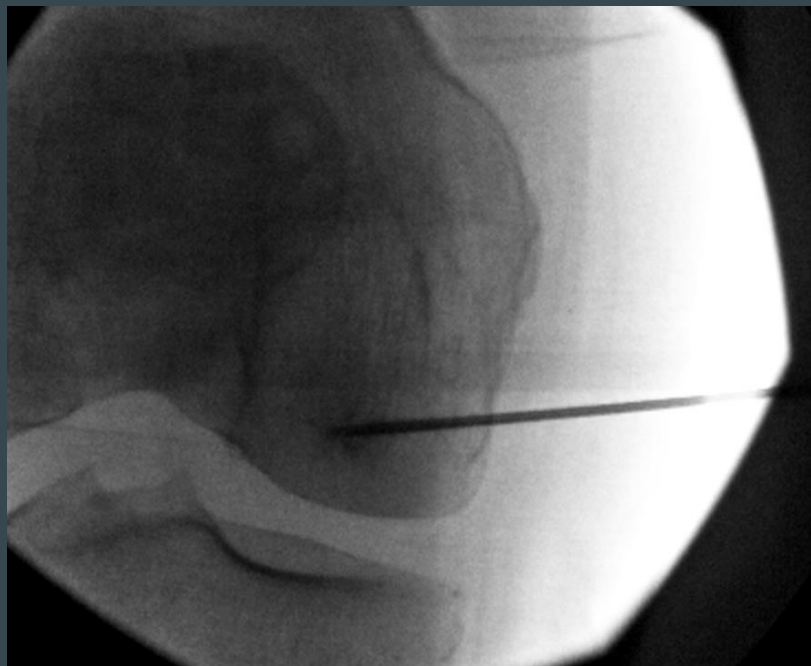
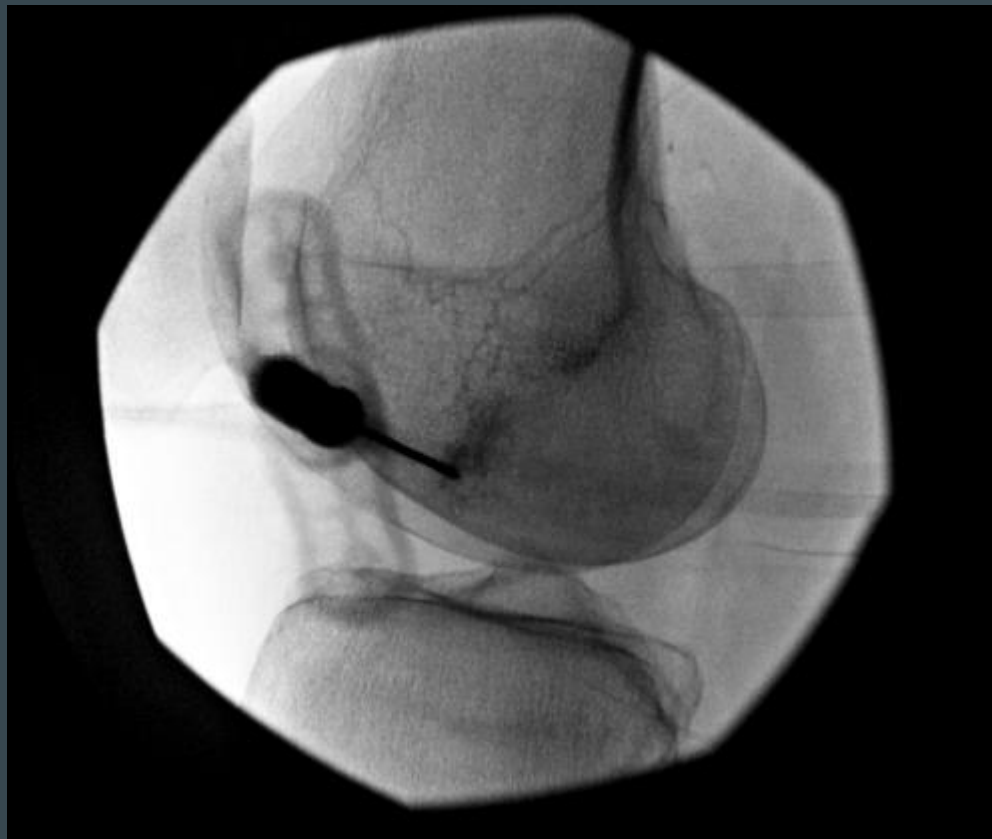
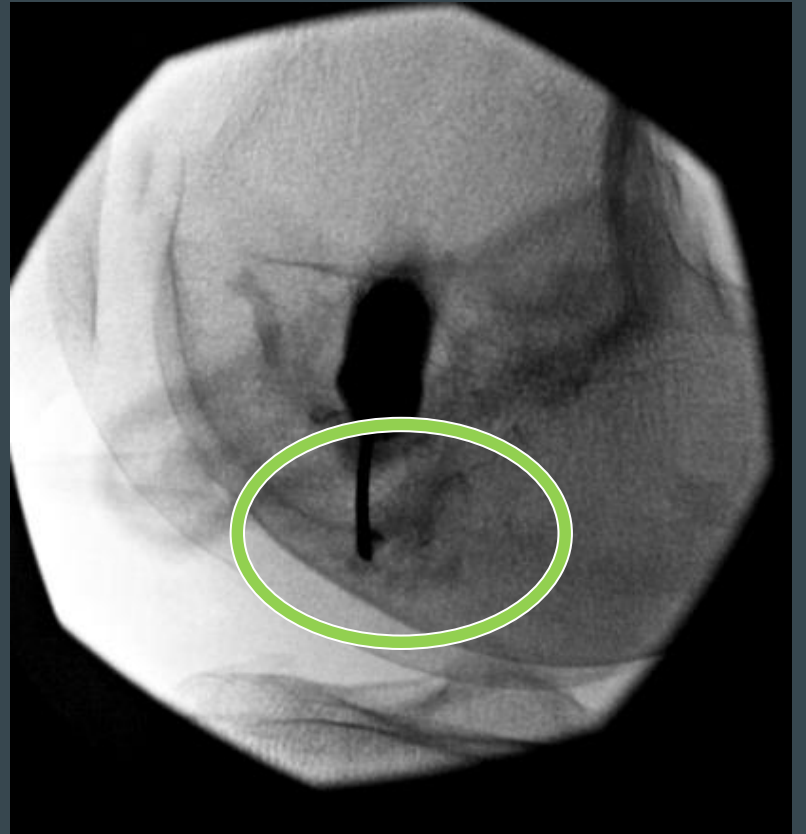


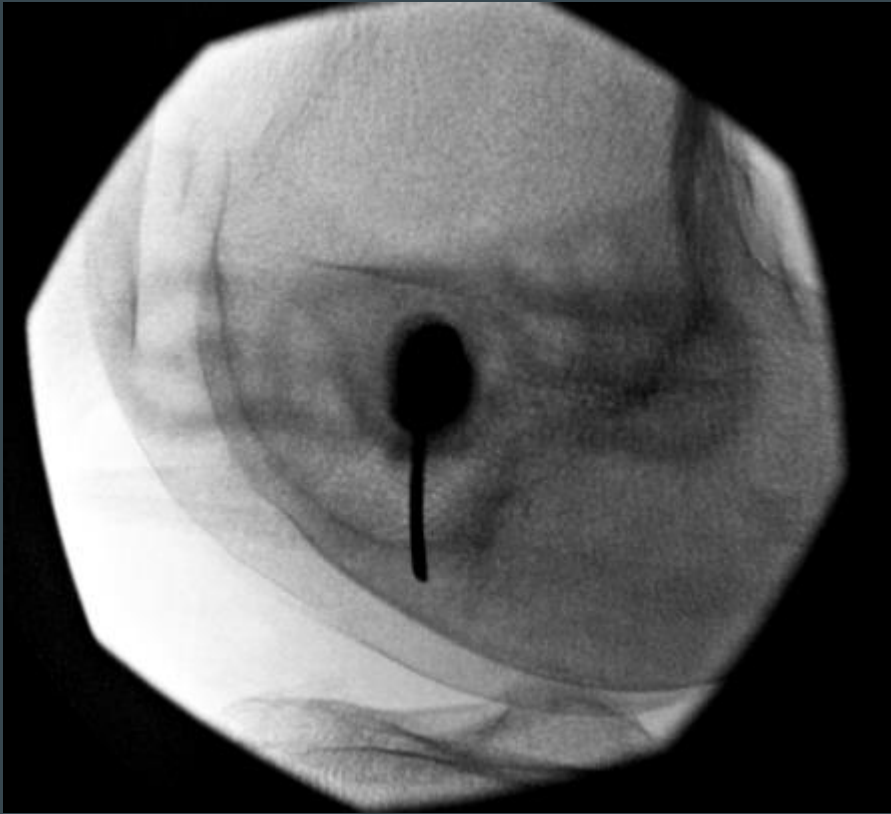# Knee osteoarthritis

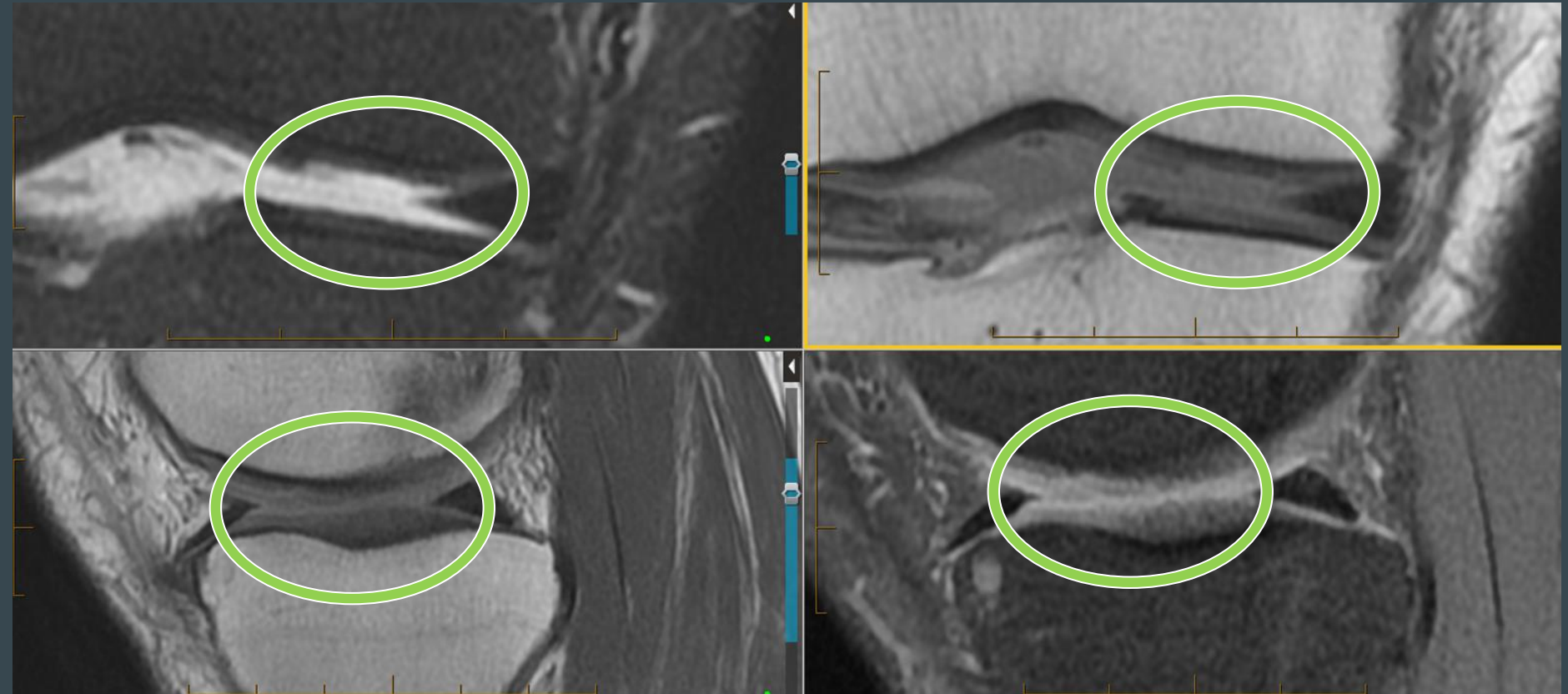


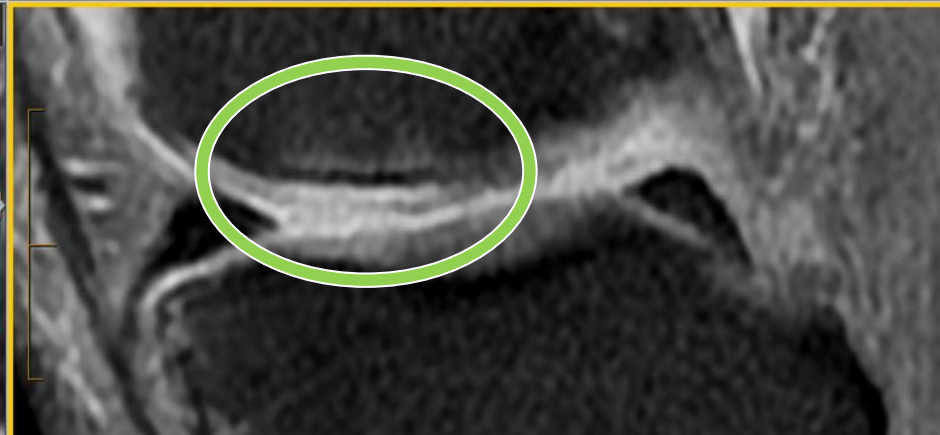
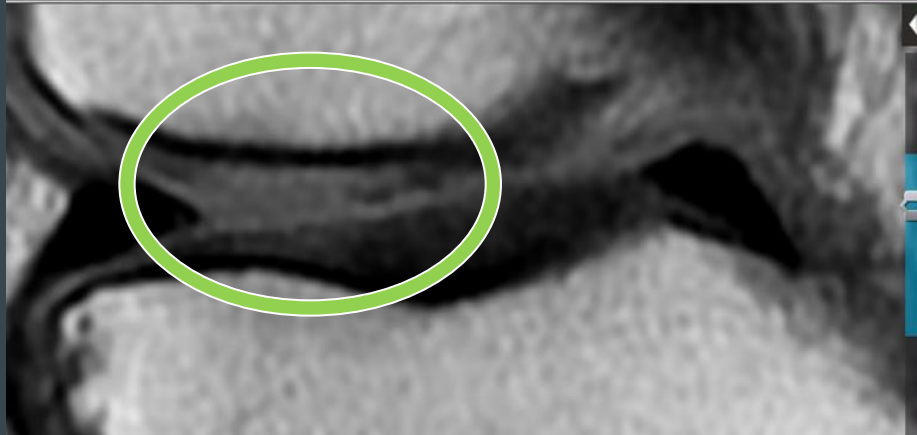
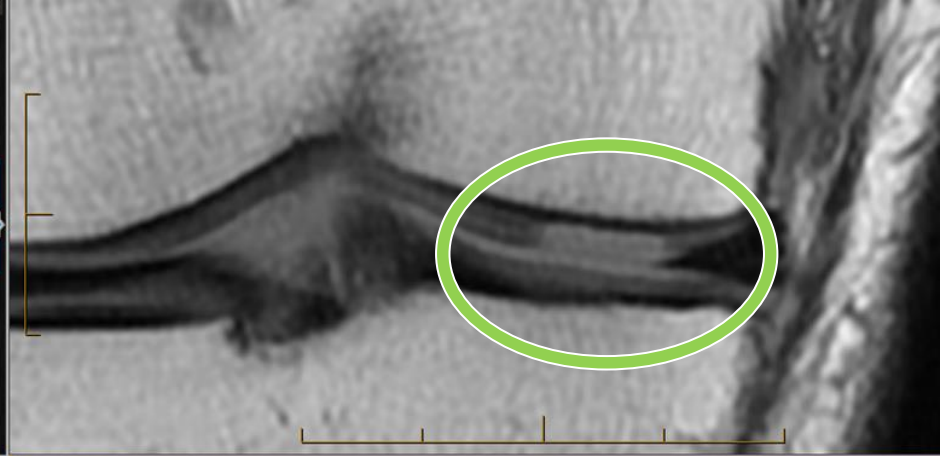
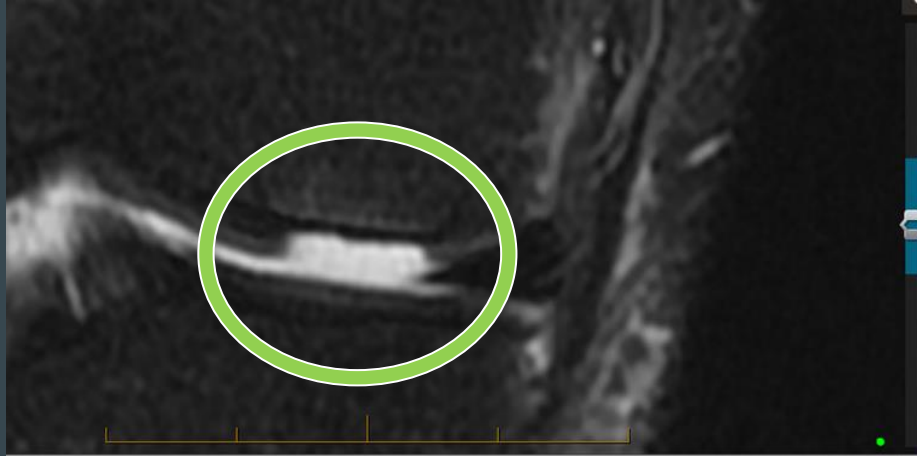


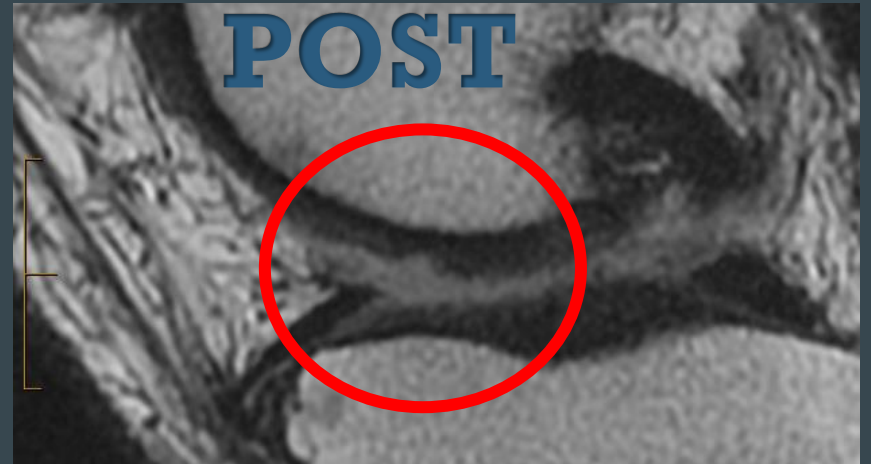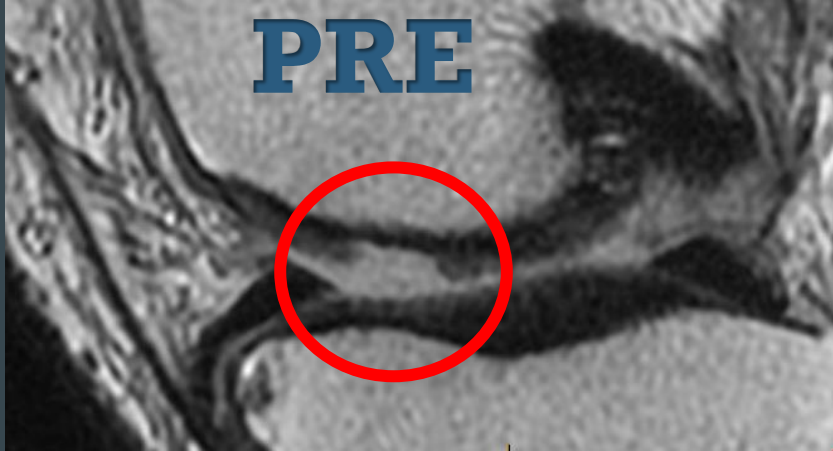


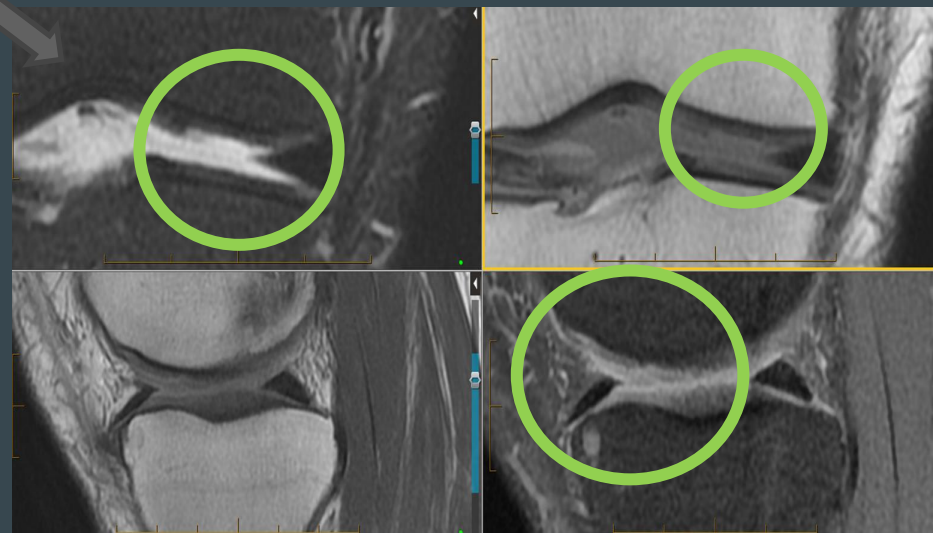
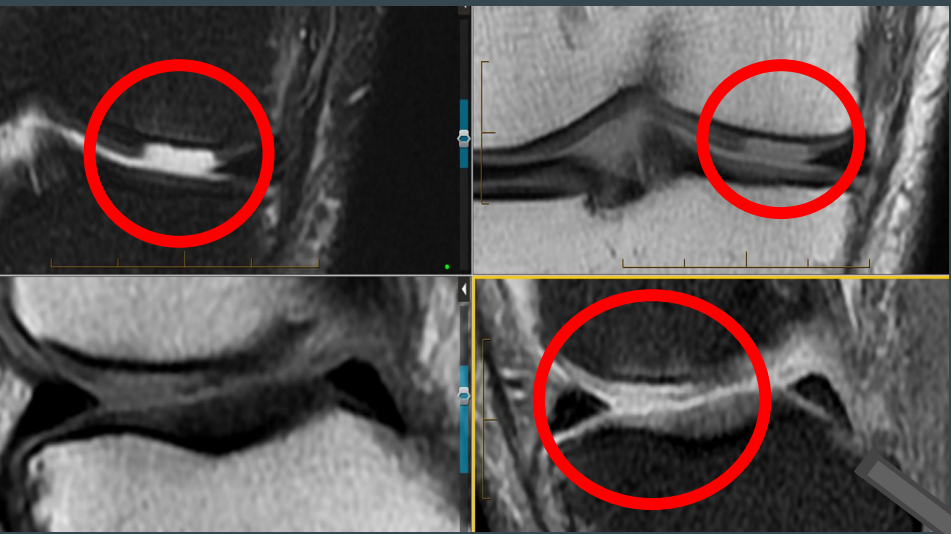


# POST





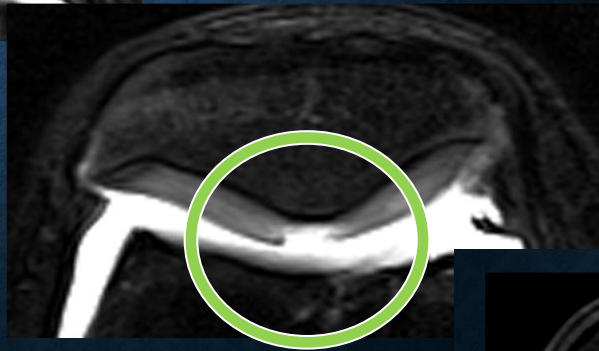
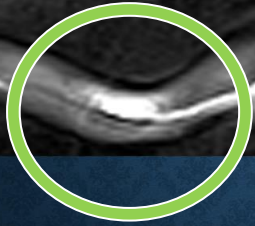




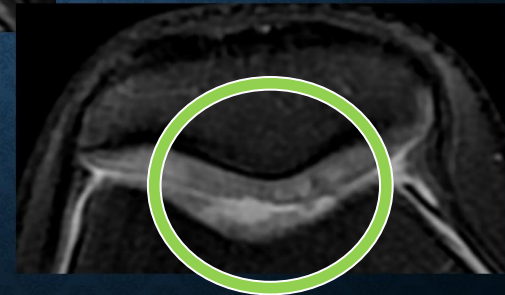
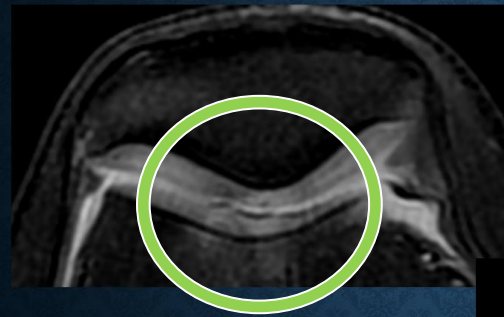
# Knee osteoarthritis

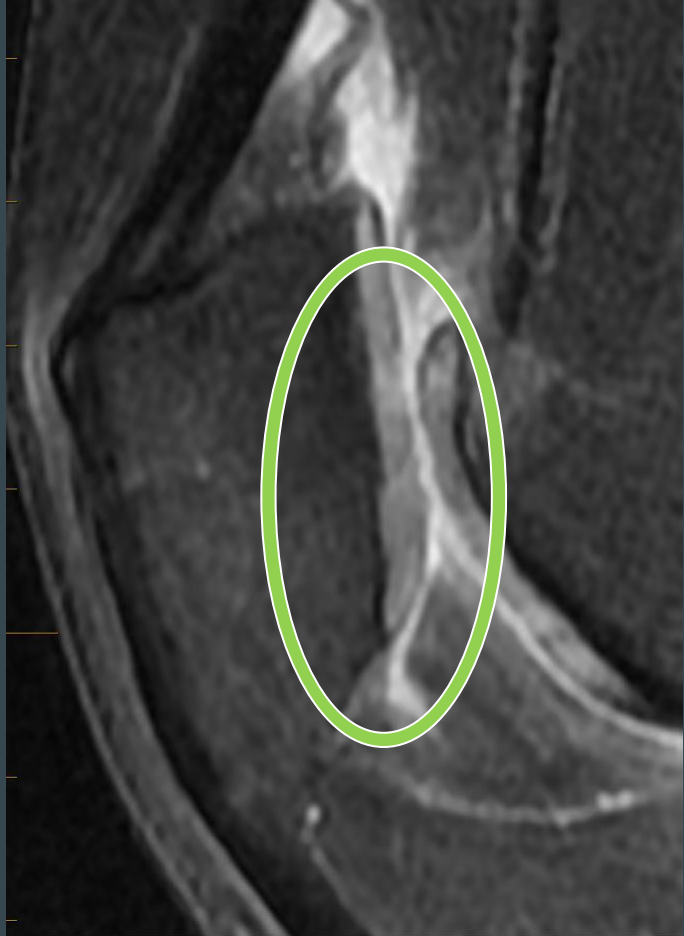
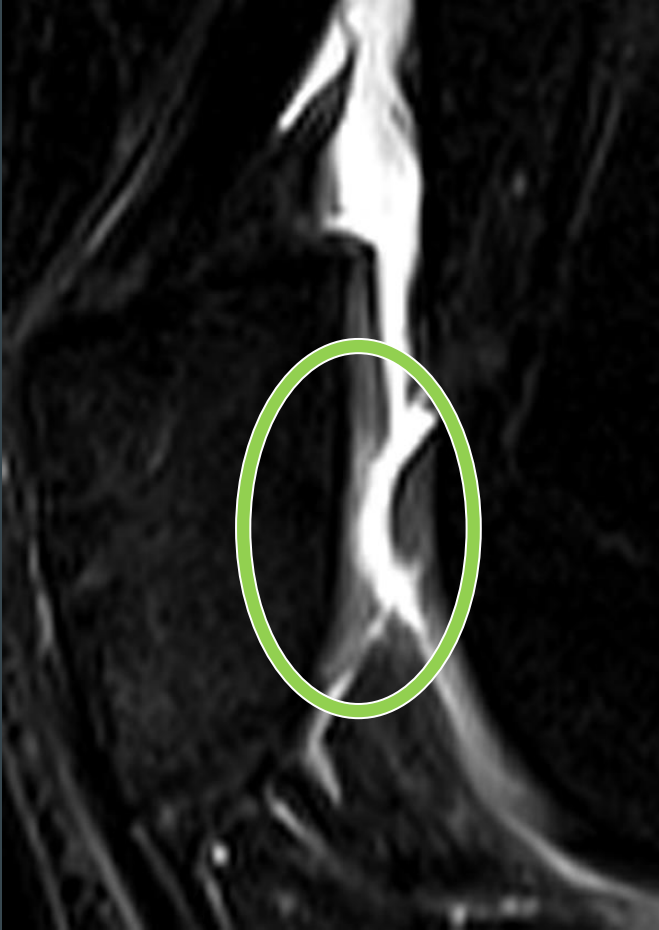


**35 YO F  
PFC  
MAY 2018**


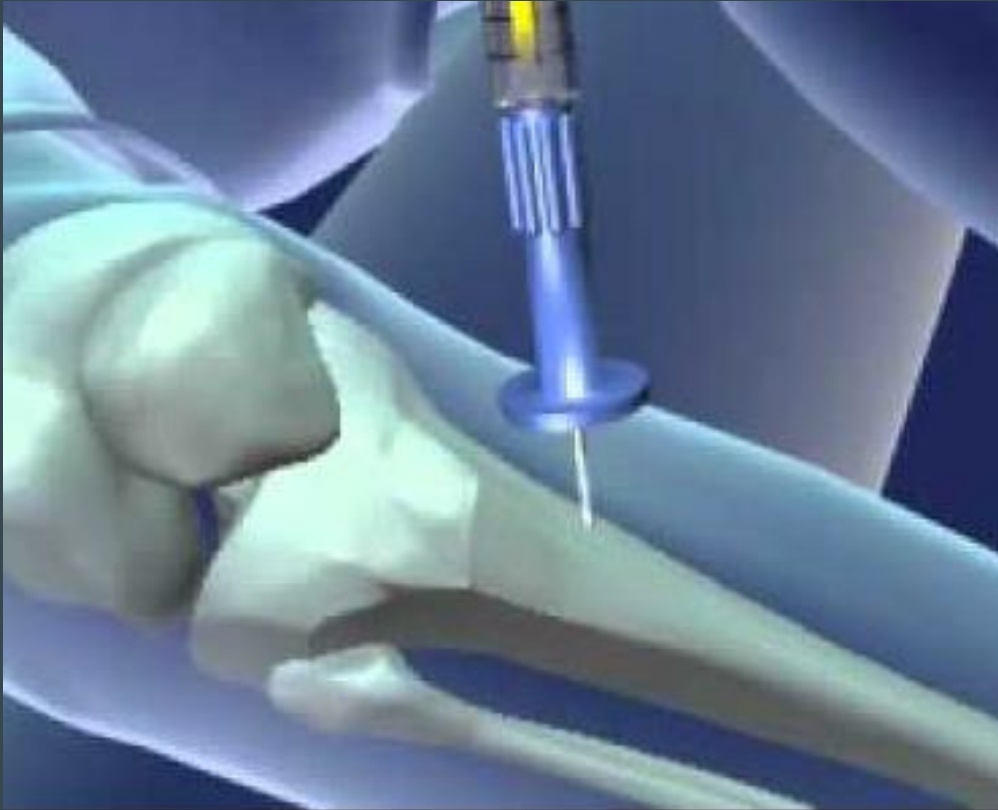


**APR 2022  
4 YEARS POST BLP  
CELL THERAPY  
INJECTION**

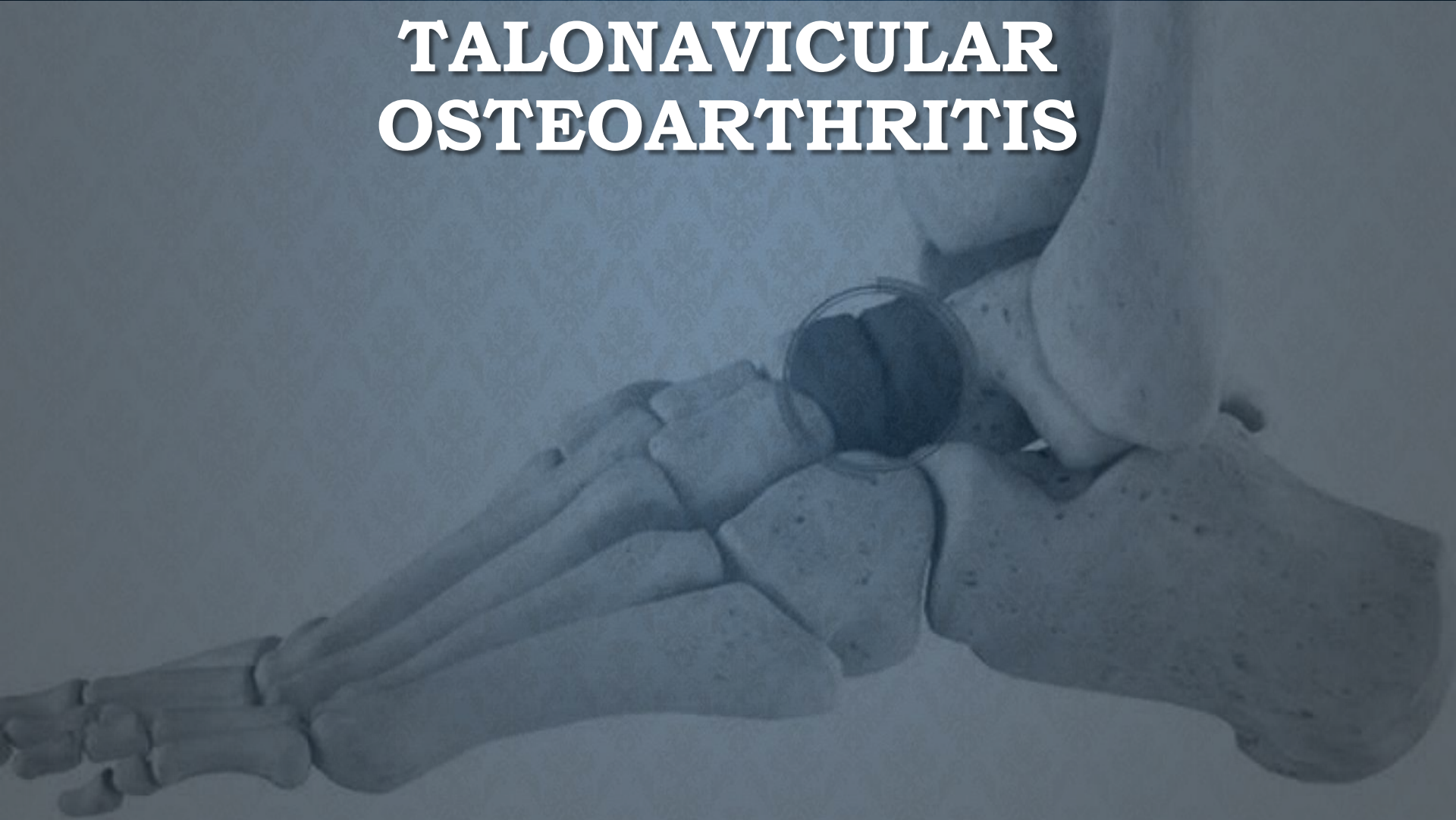


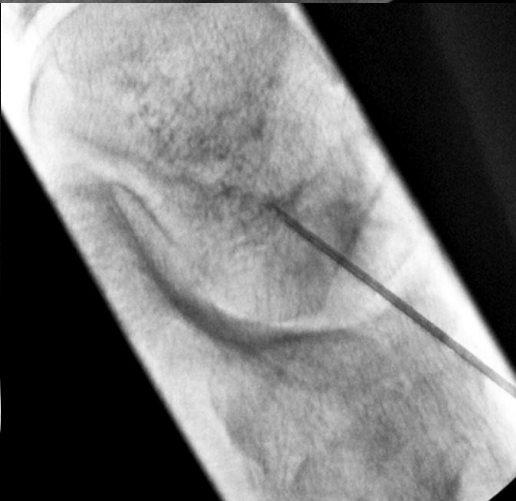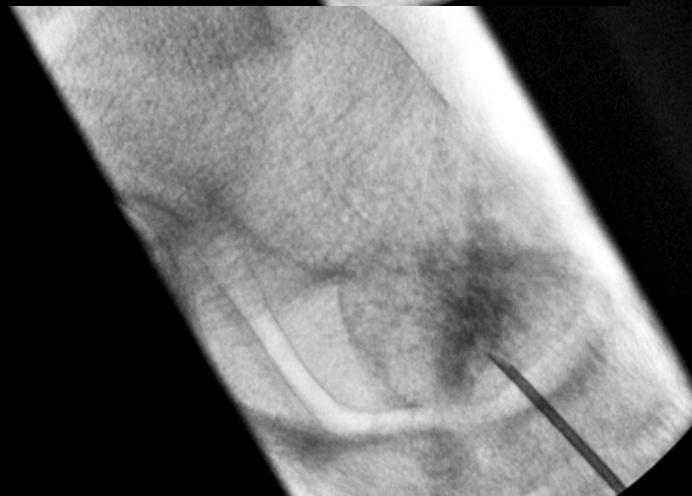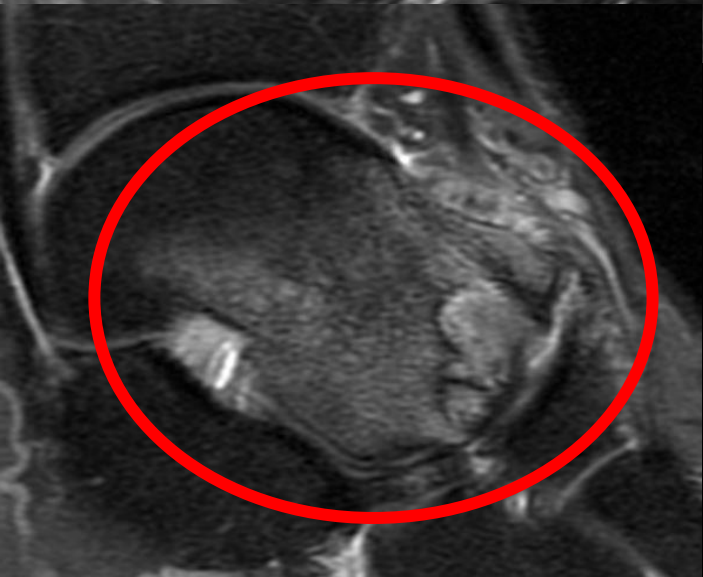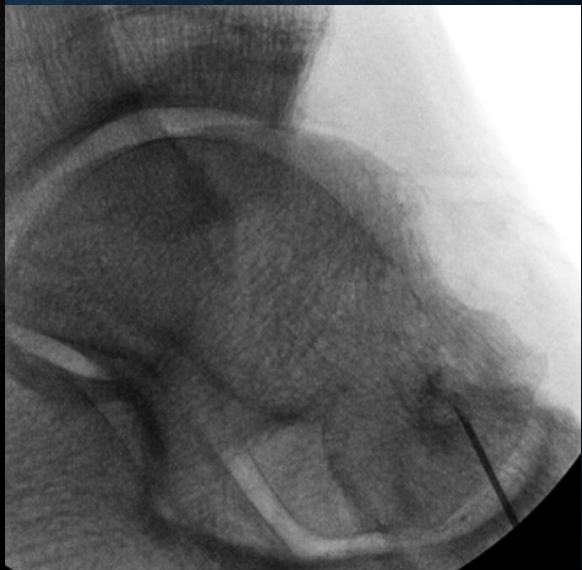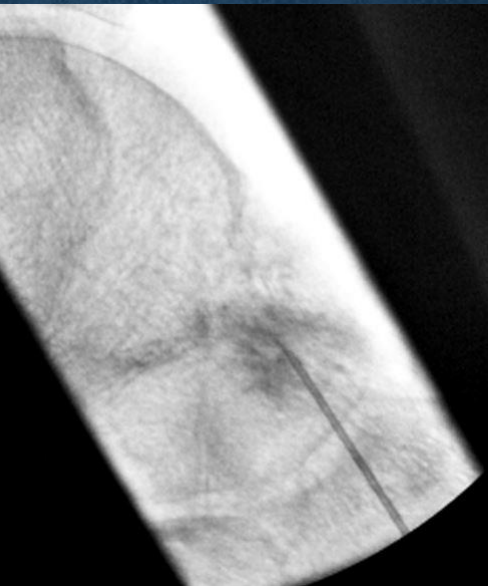
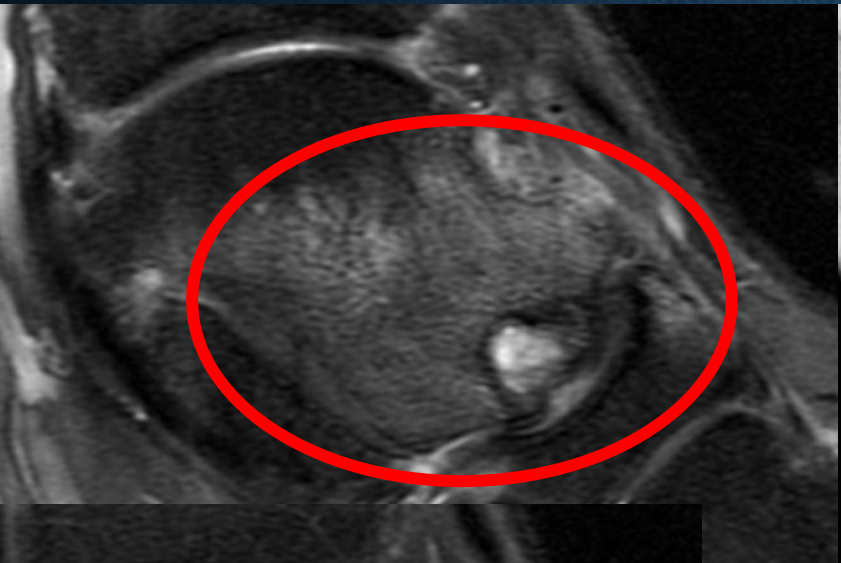


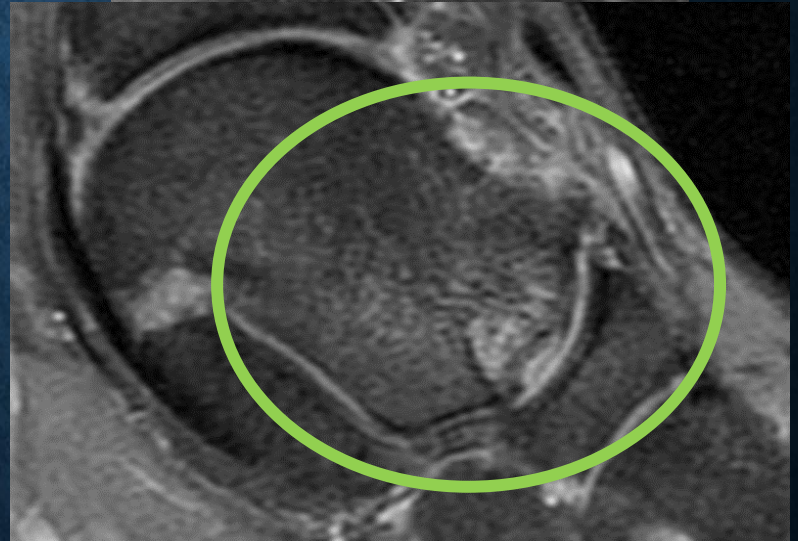
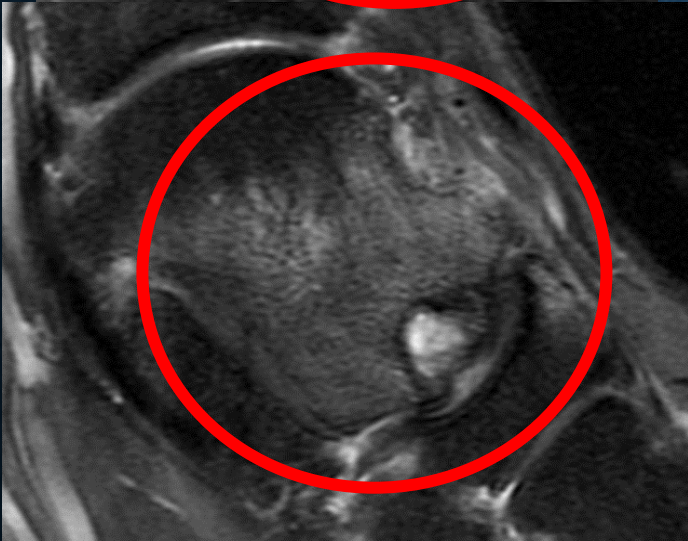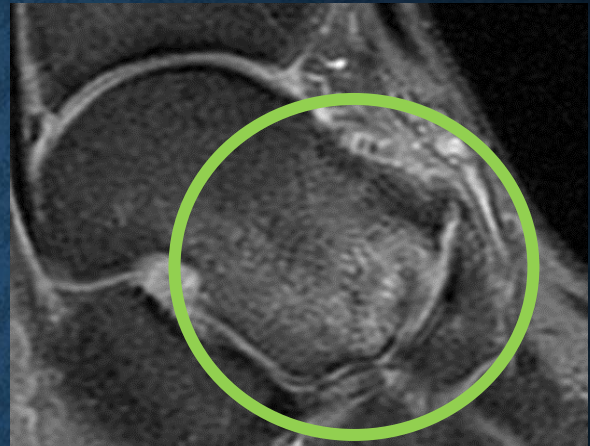
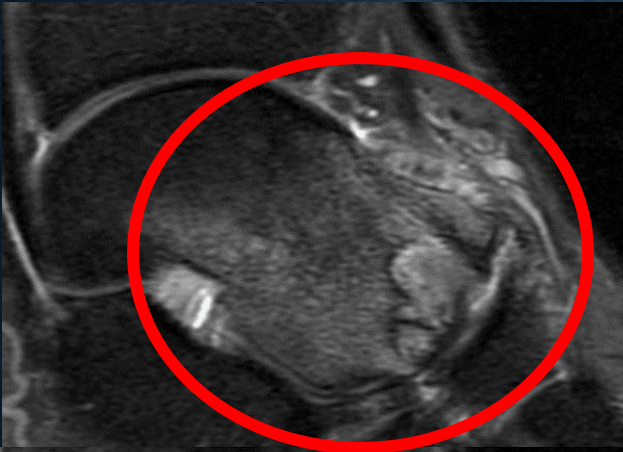# Intra-Osseous Injections



# TALONAVICULAR OSTEOARTHRITIS

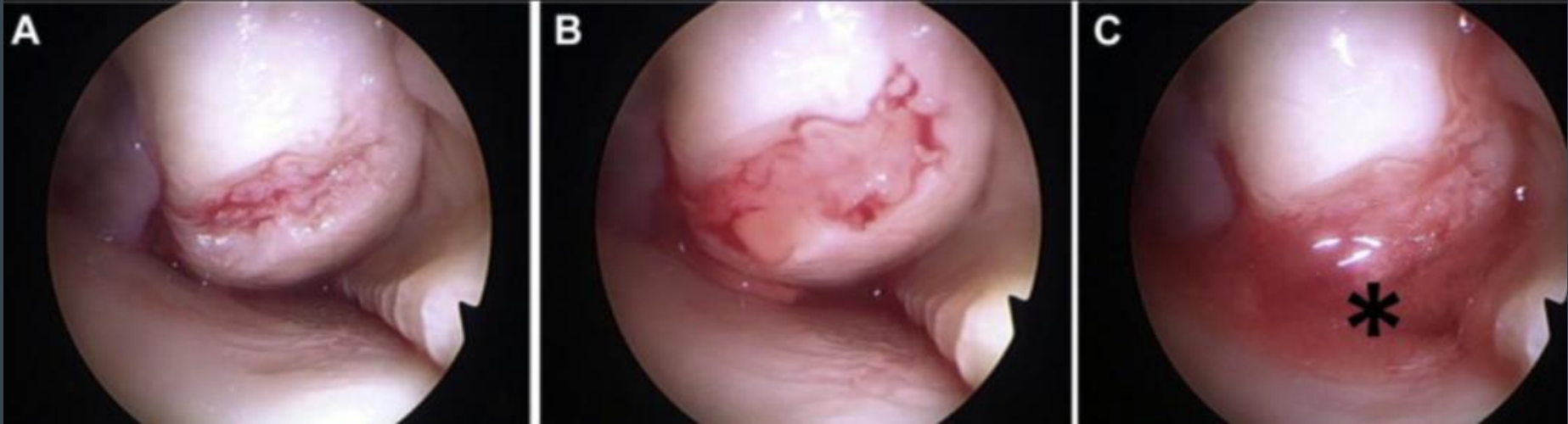





An anatomical illustration of a human knee joint. The femur (thigh bone) is at the top, and the tibia (shin bone) is at the bottom. The patella (kneecap) is visible in the center. The joint space is highlighted in a bright yellow-orange color, indicating the site of osteoarthritis. The surrounding muscles and ligaments are shown in shades of blue and purple. The text "KNEE OSTEOARTHRITIS" is overlaid in the center of the image.

# **KNEE OSTEOARTHRITIS**



> *Arthrosc Tech*. 2014 Dec 15;3(6):e713-7. doi: 10.1016/j.eats.2014.09.006. eCollection 2014 Dec.

### Intraosseous infiltration of platelet-rich plasma for severe knee osteoarthritis

Mikel Sánchez <sup>1</sup>, Nicolás Fiz <sup>2</sup>, Jorge Guadilla <sup>3</sup>, Sabino Padilla <sup>3</sup>, Eduardo Anitua <sup>3</sup>, Pello Sánchez <sup>4</sup>, Diego Delgado <sup>4</sup>

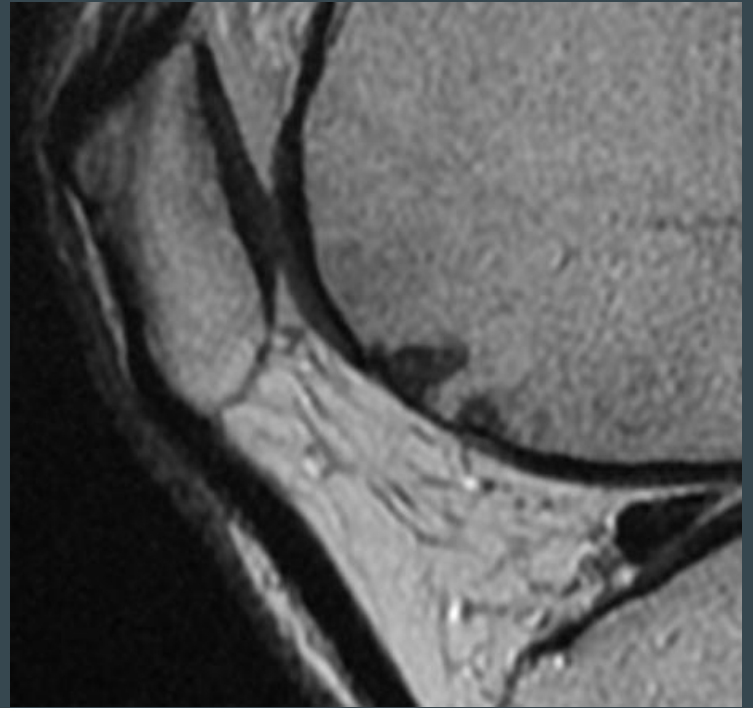
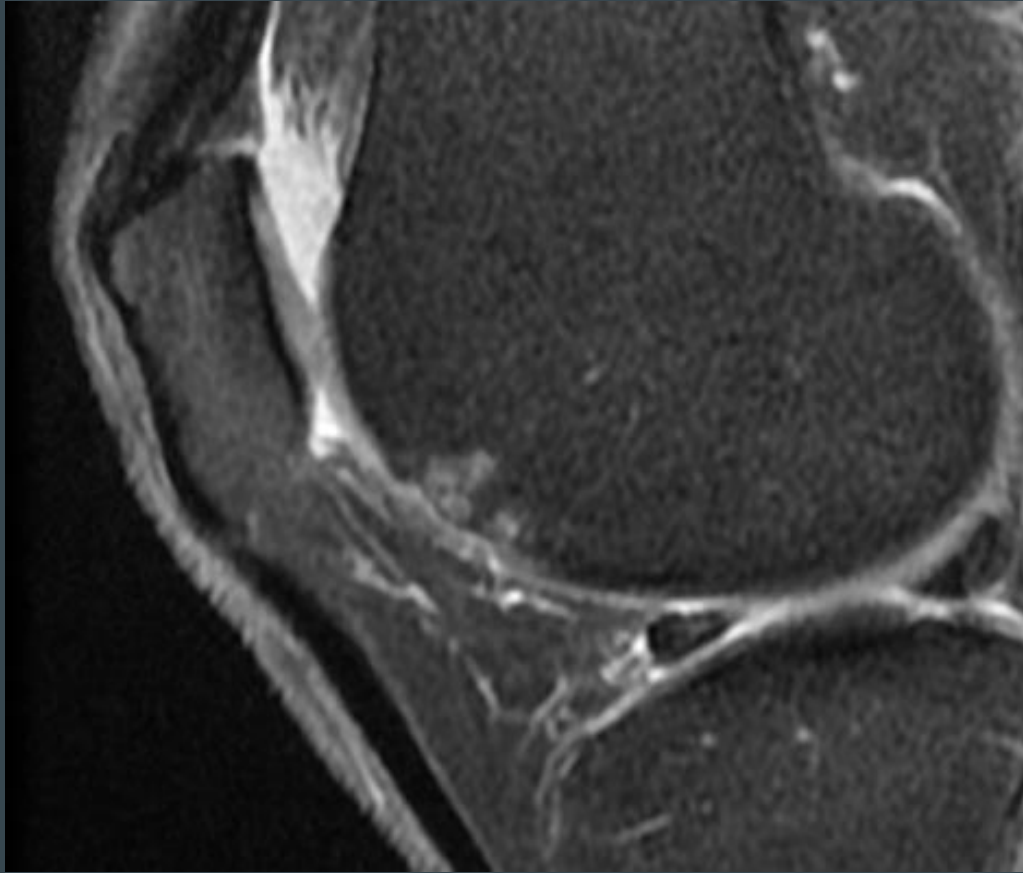
Affiliations + expand

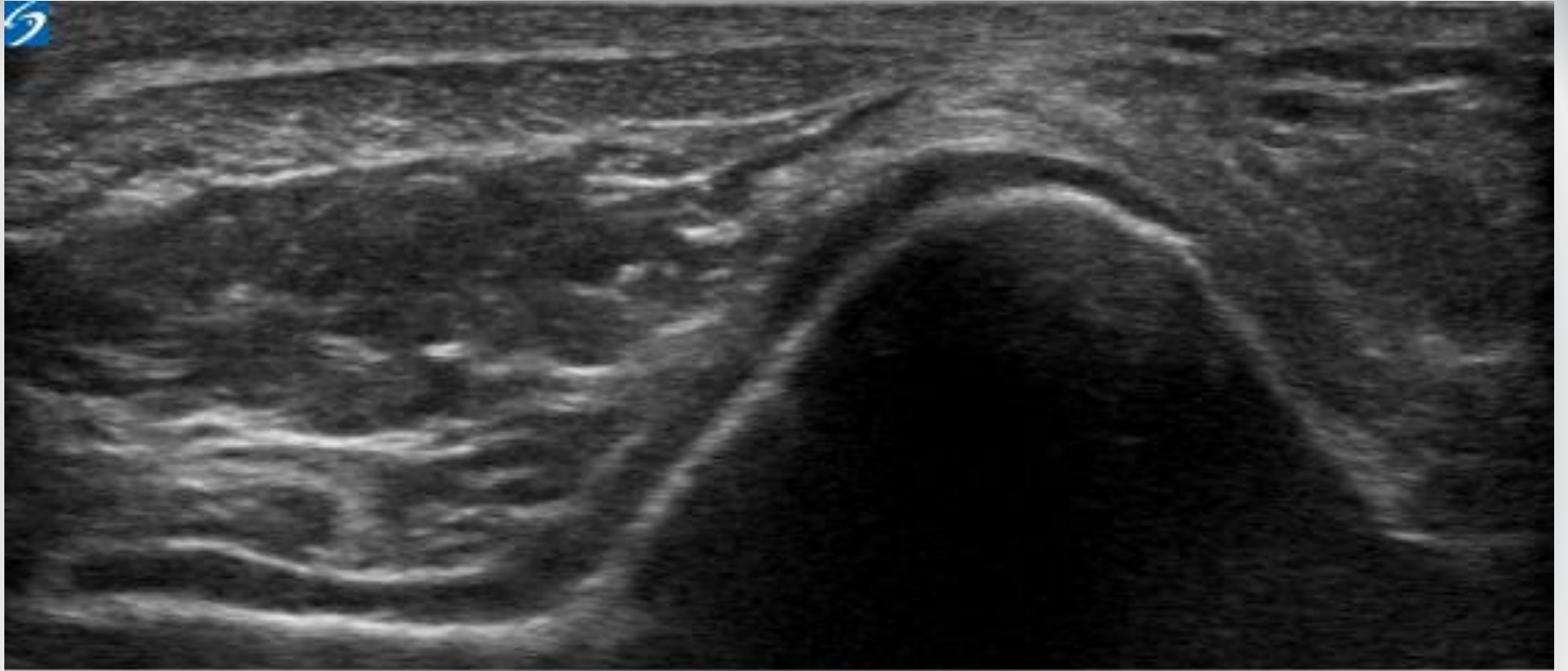
PMID: 25685680 PMCID: PMC4314556 DOI: 10.1016/j.eats.2014.09.006

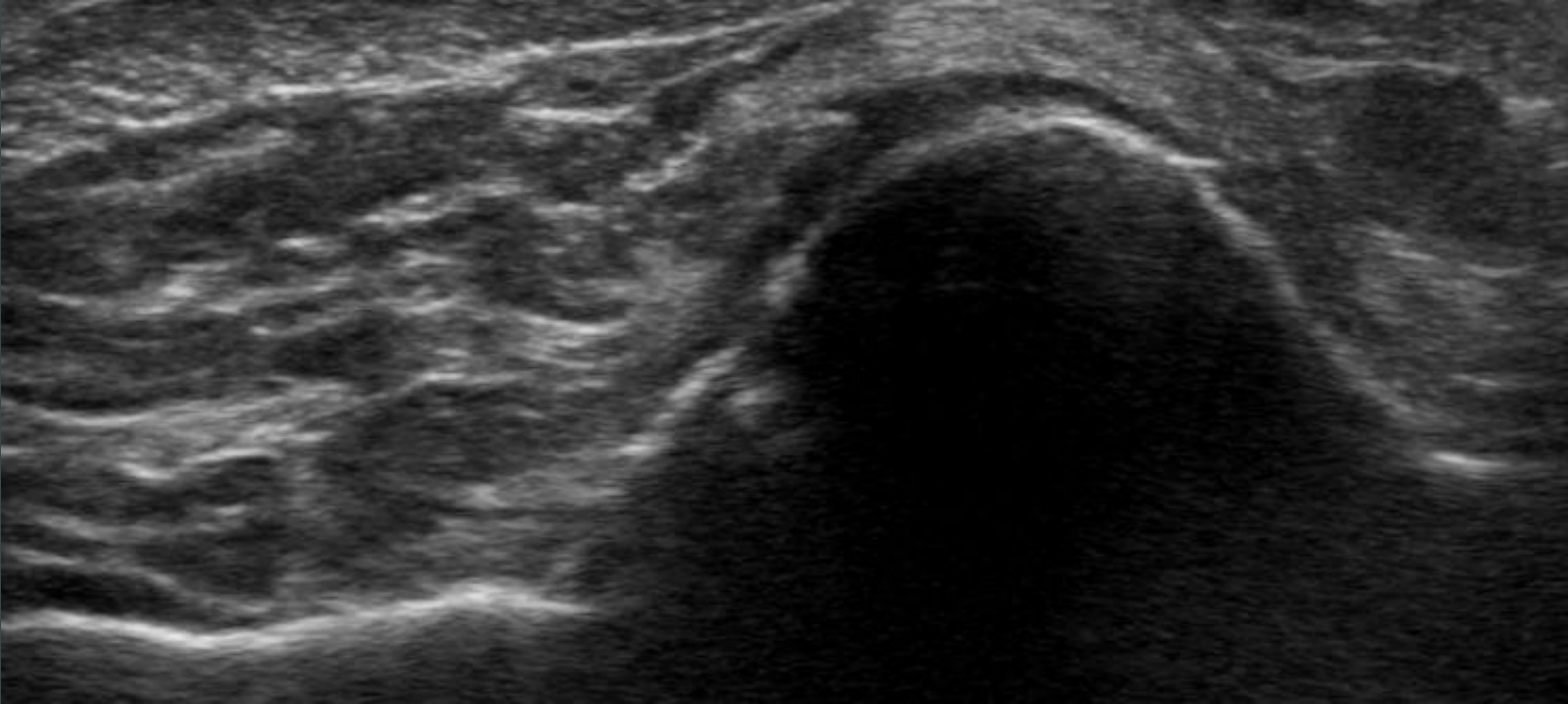
#### Abstract

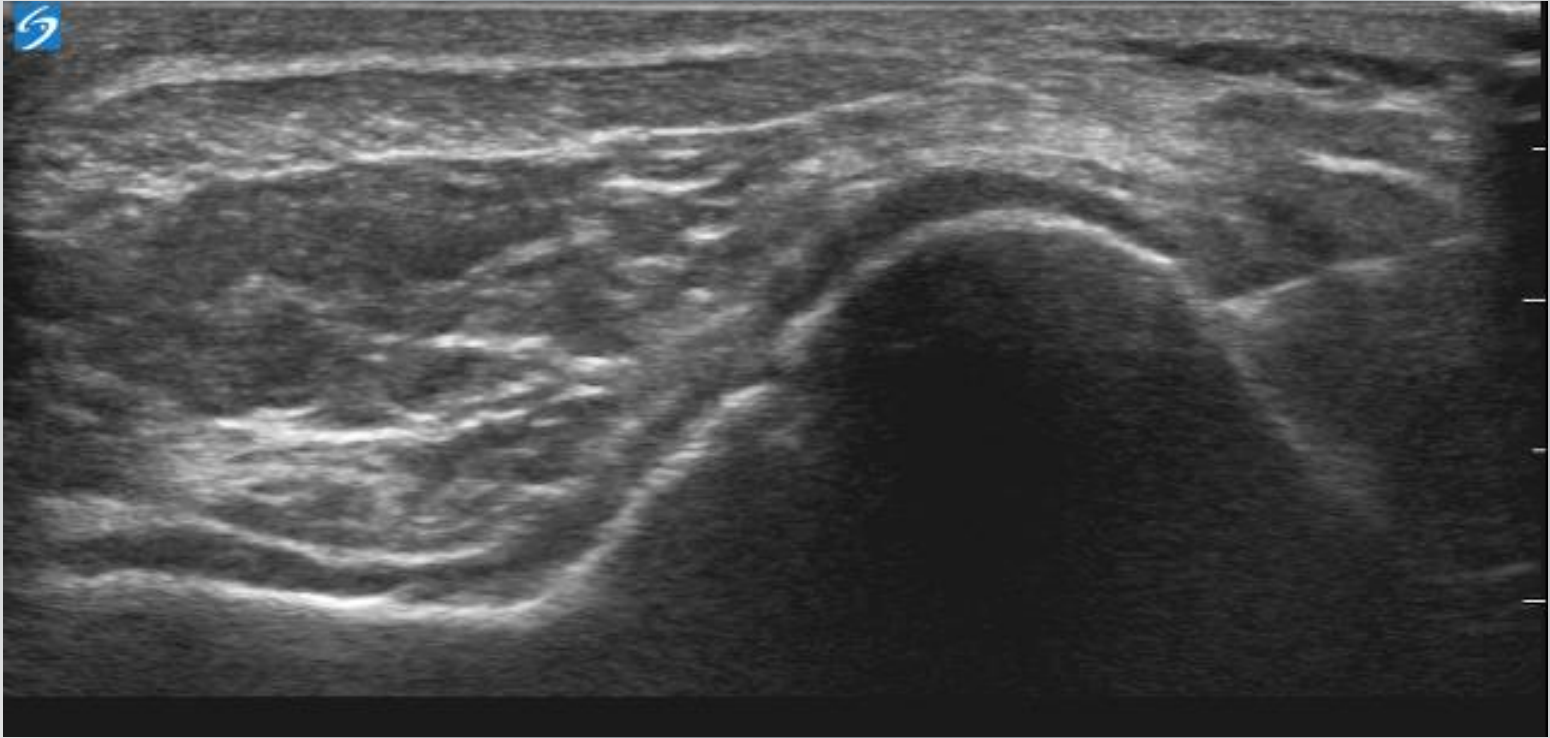
We describe a new technique of platelet-rich plasma (PRP) infiltration for the treatment of severe knee osteoarthritis. PRP intra-articular infiltration is a promising treatment for knee osteoarthritis, but it still has some limitations in high-degree osteoarthritis. Diagnosis of osteoarthritis is based on clinical and radiographic findings, and patients with grade III or IV knee tibiofemoral osteoarthritis based on the Ahlbäck scale are considered candidates for this technique. The technique consists of performing intraosseous infiltration of PRP into the subchondral bone, which acts on this tissue and consequently on cartilage-bone communication. Although the intraosseous injection hinders the conventional knee intra-articular infiltration, it allows an extension of the range of action of the PRP, which acts directly on the subchondral bone, which is involved in the progression of osteoarthritis. Thus this technique involves a new administration of PRP that can delay knee arthroplasty; moreover, it can be applied for not only severe osteoarthritis but also other pathologies in which the subchondral bone is critical in the etiology, such as necrosis and osteochondral lesions.

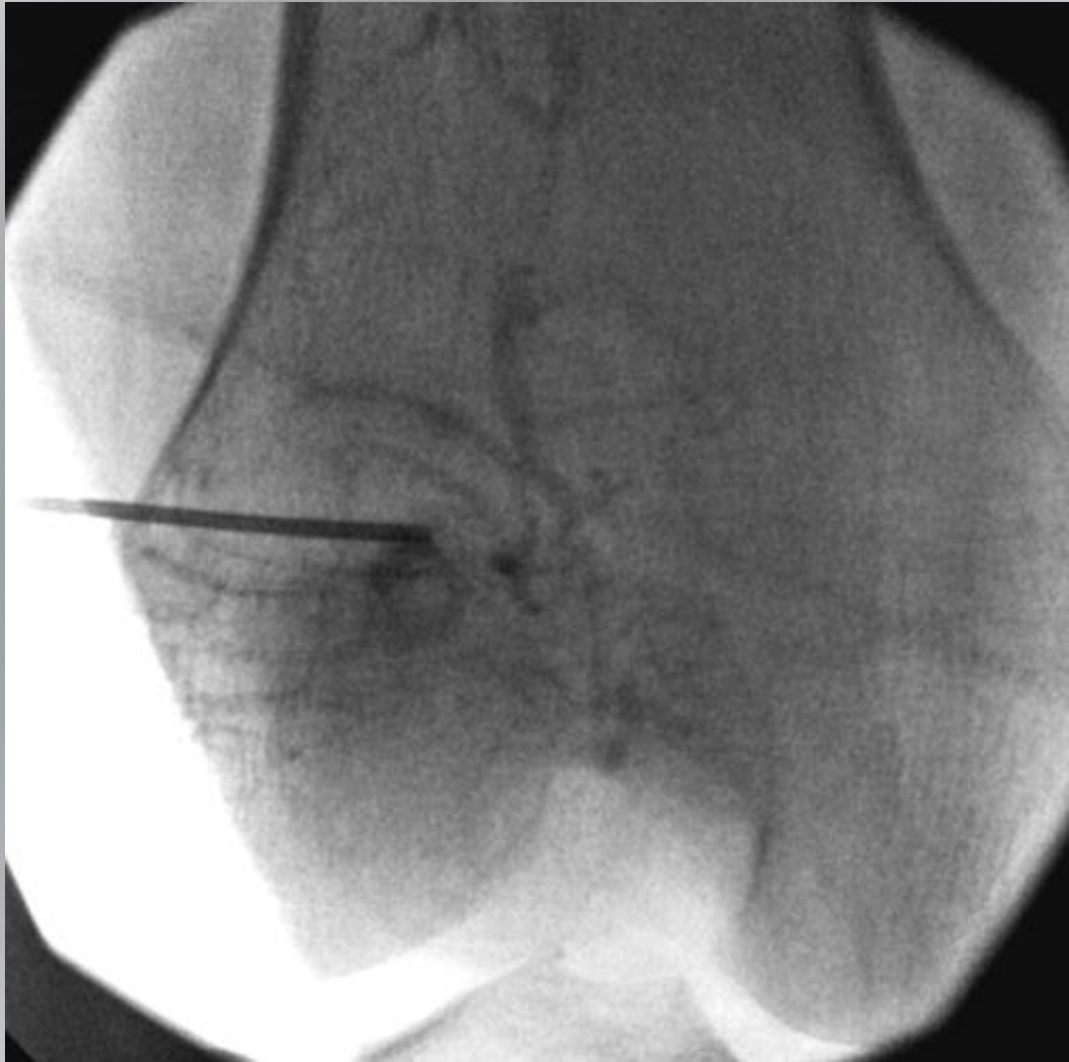PubMed Disclaimer

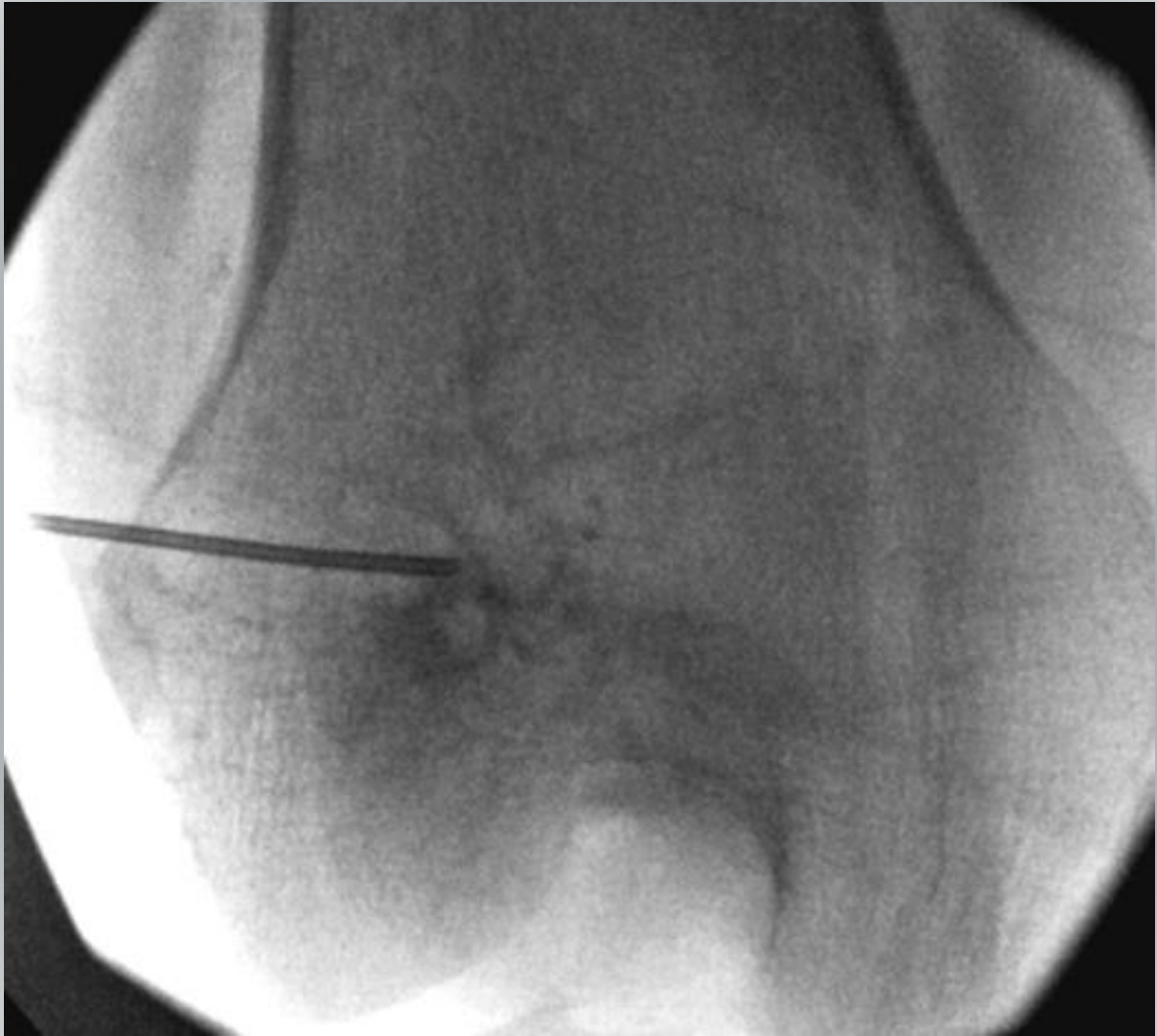

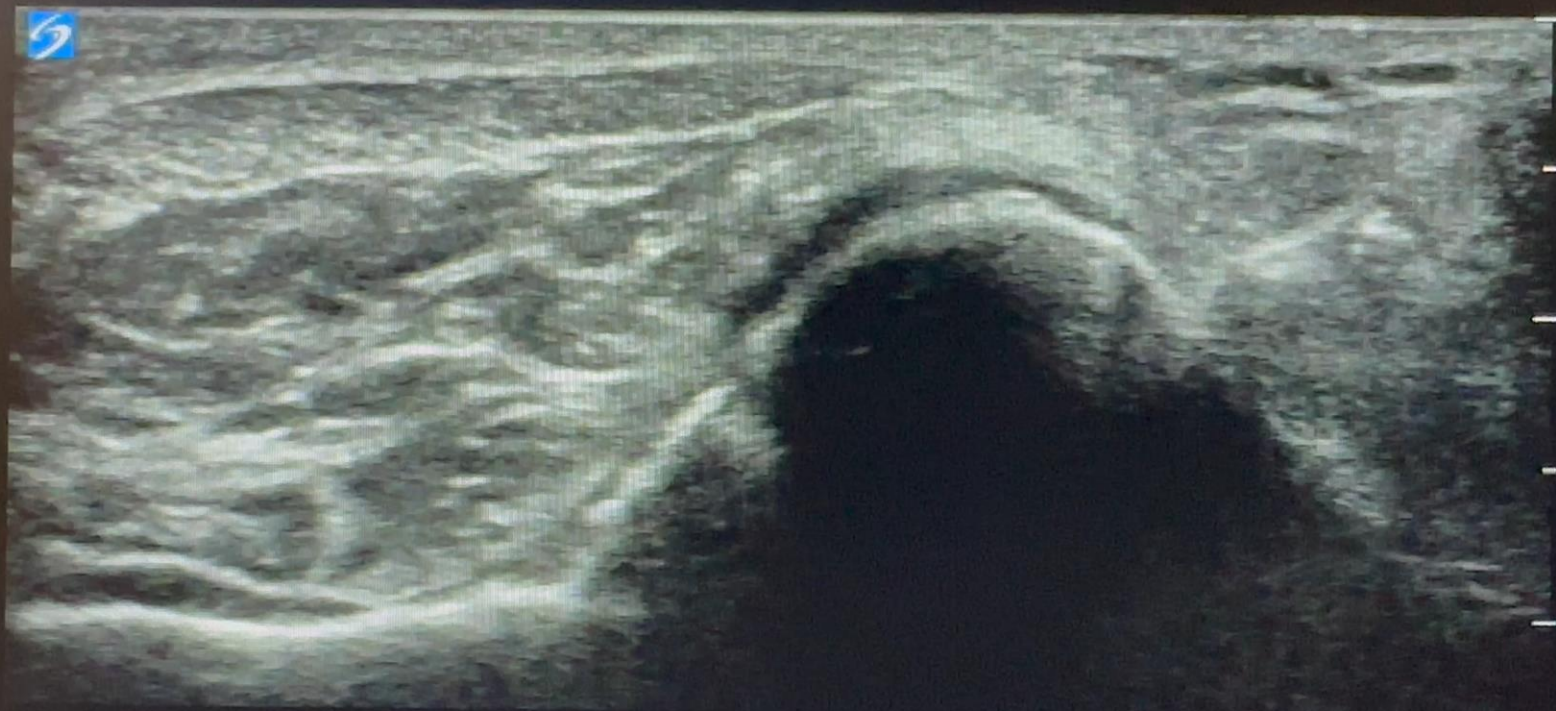












KNEE

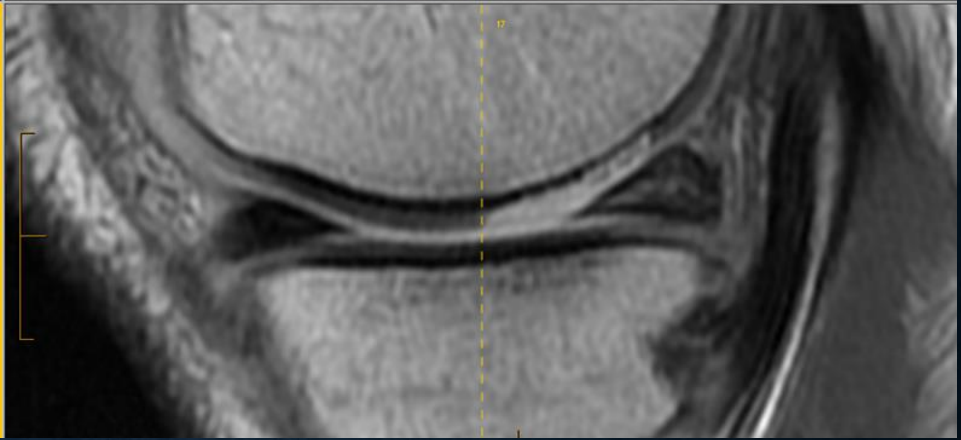
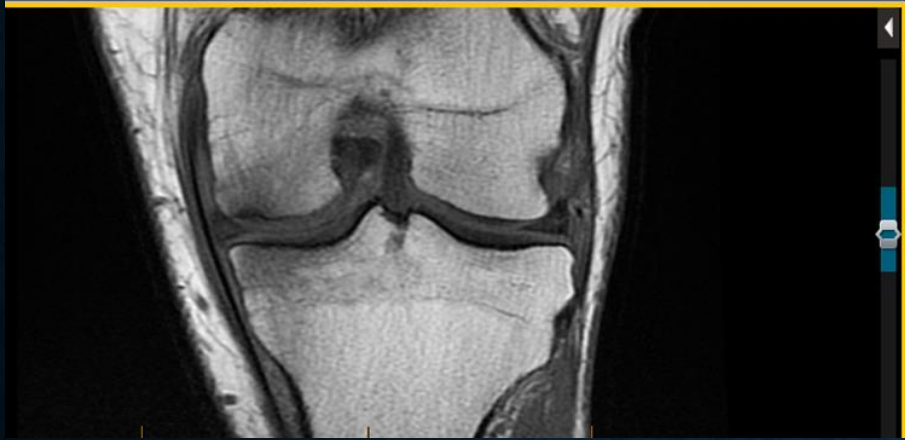
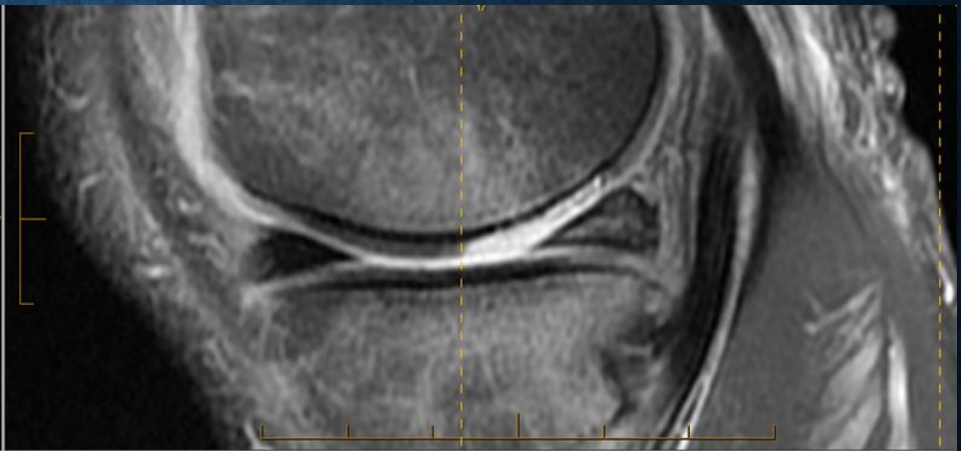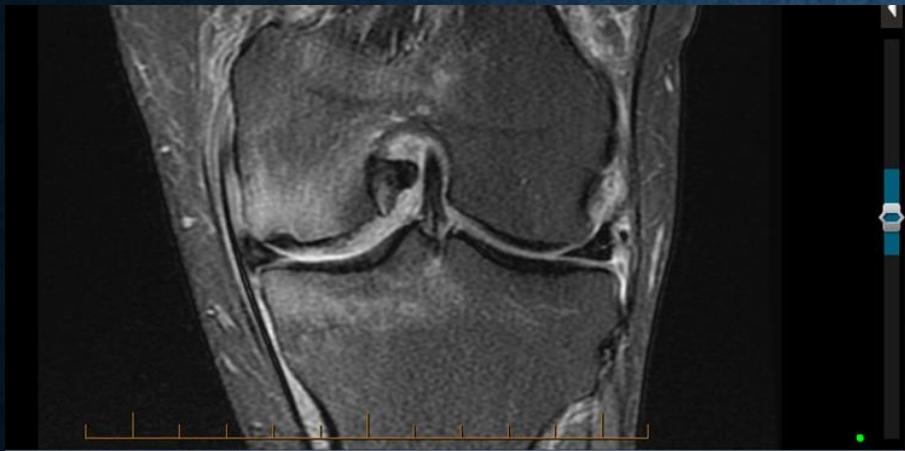Right  
SonoSite

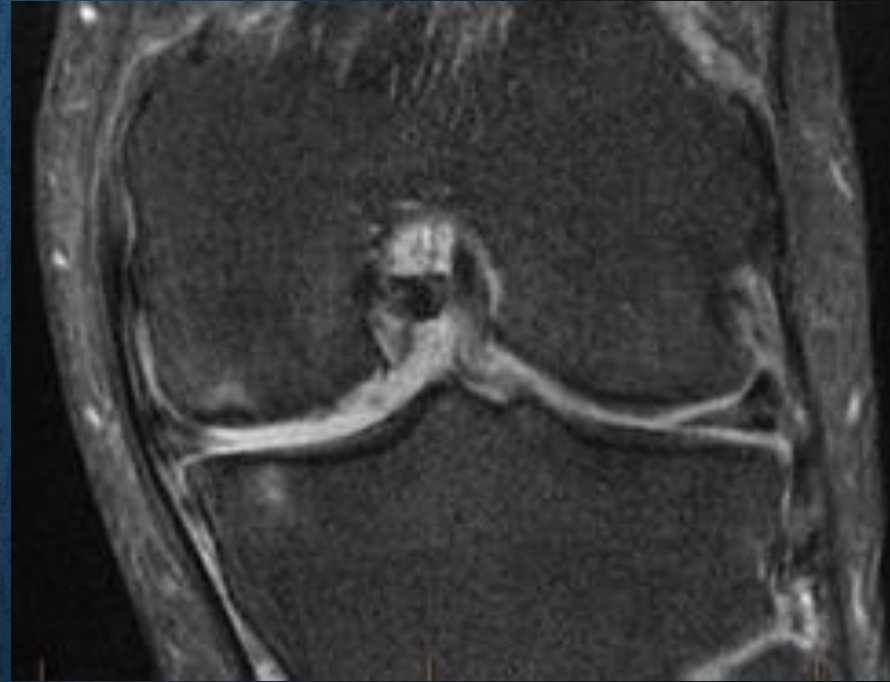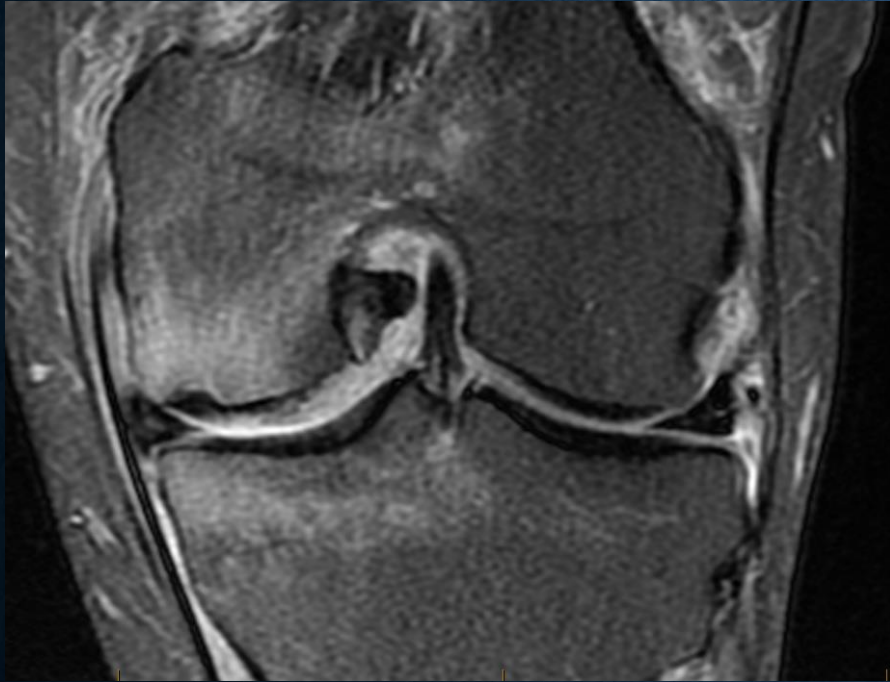2.3 cm

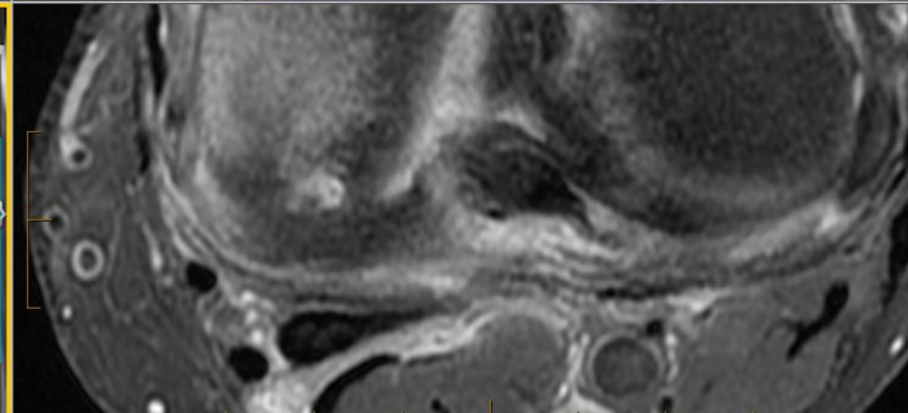
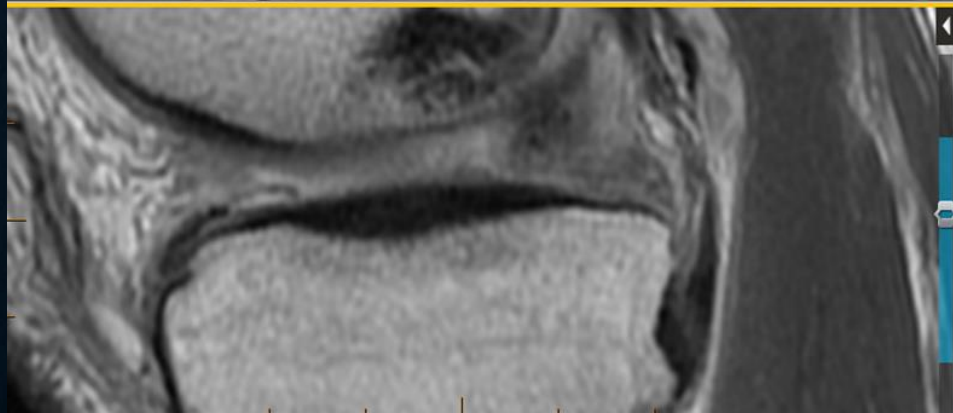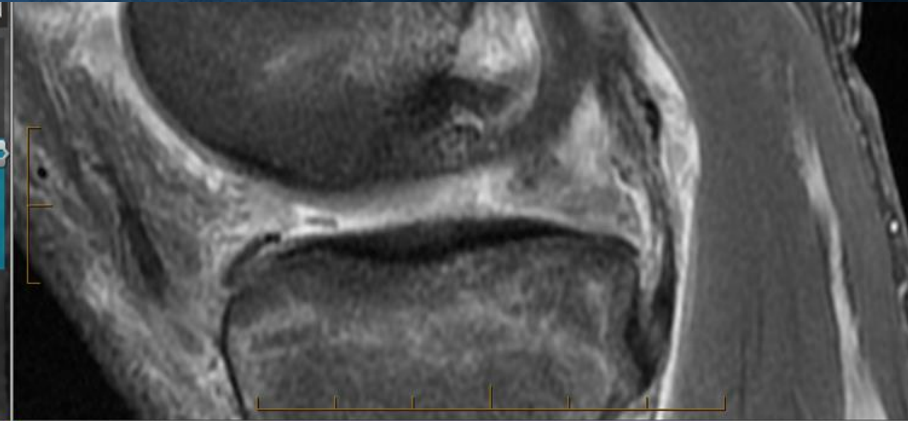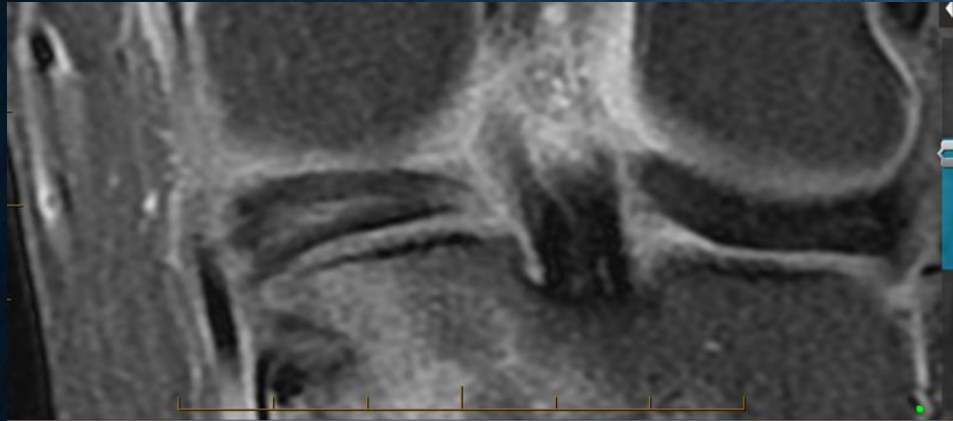2D: G: 50

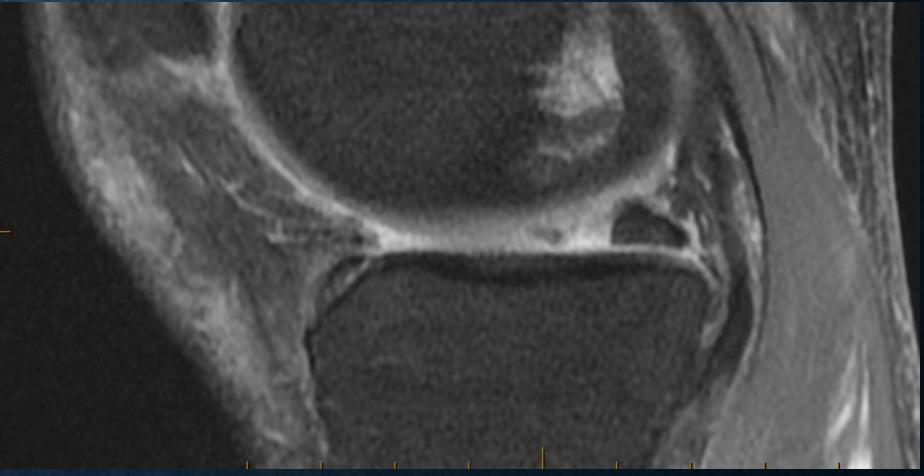
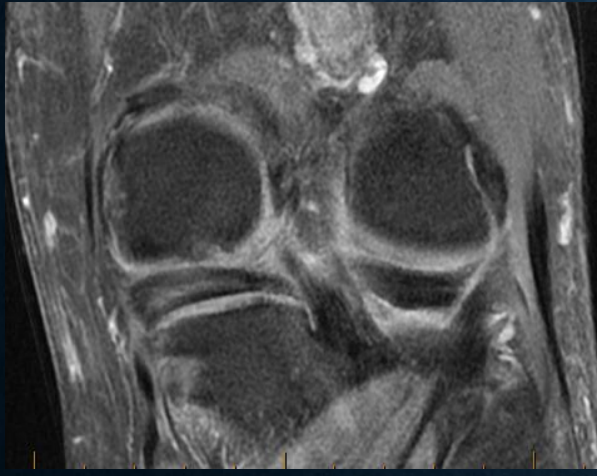
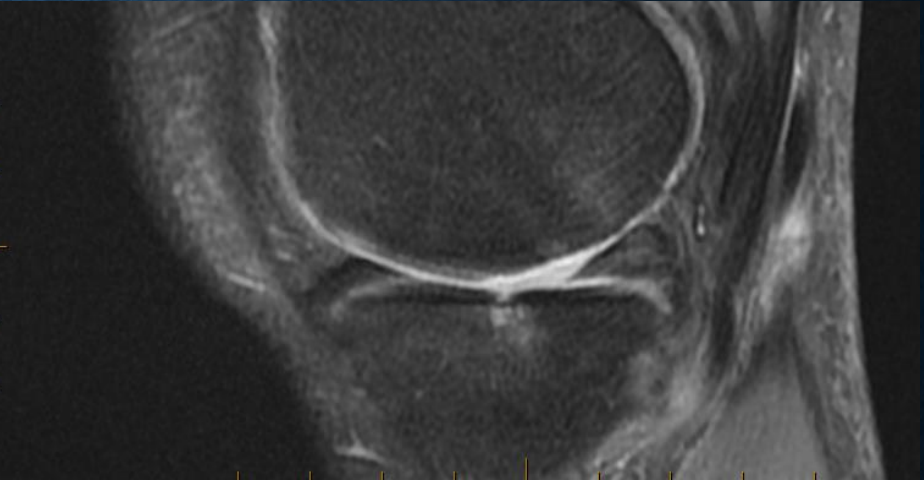
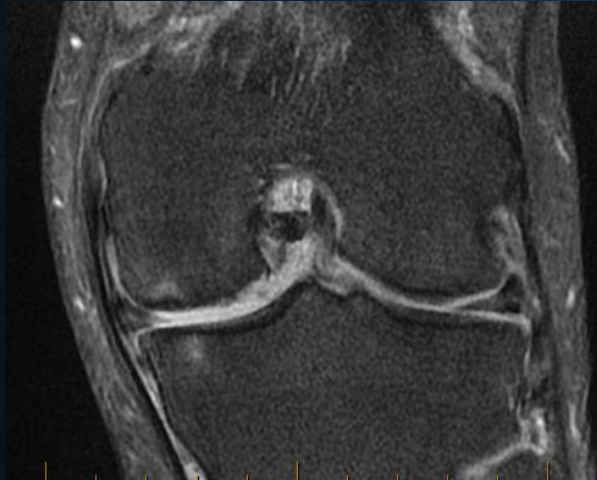An anatomical illustration of a human knee joint. The left side of the image shows a normal knee joint in a blue, semi-transparent style. The right side shows a knee joint with a red and yellow glow, indicating inflammation and osteoarthritis. The text "KNEE OSTEOARTHRITIS" is overlaid in the center in a bold, white, serif font.

# **KNEE OSTEOARTHRITIS**

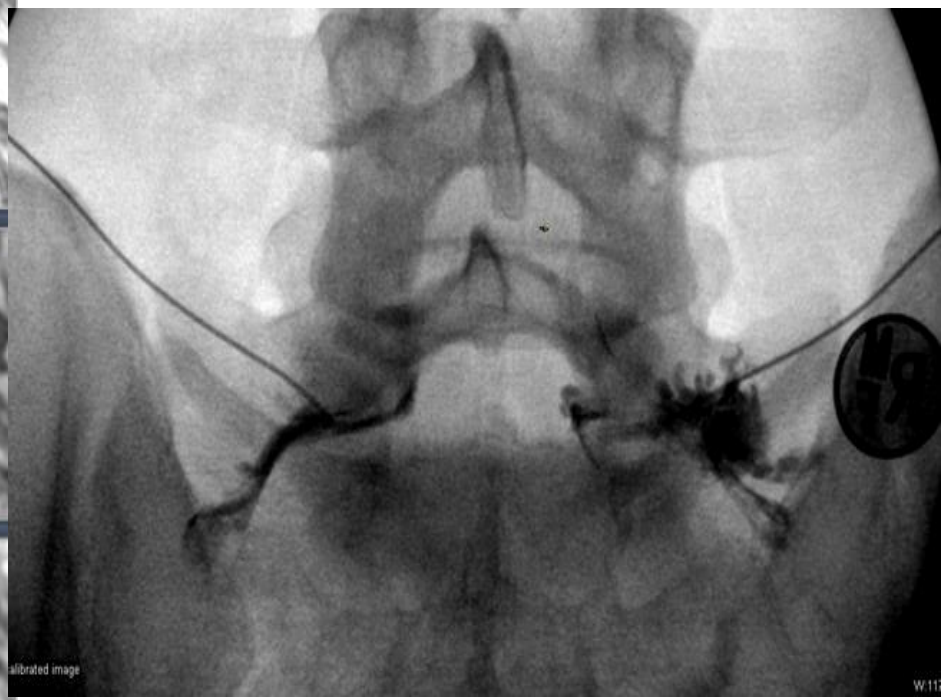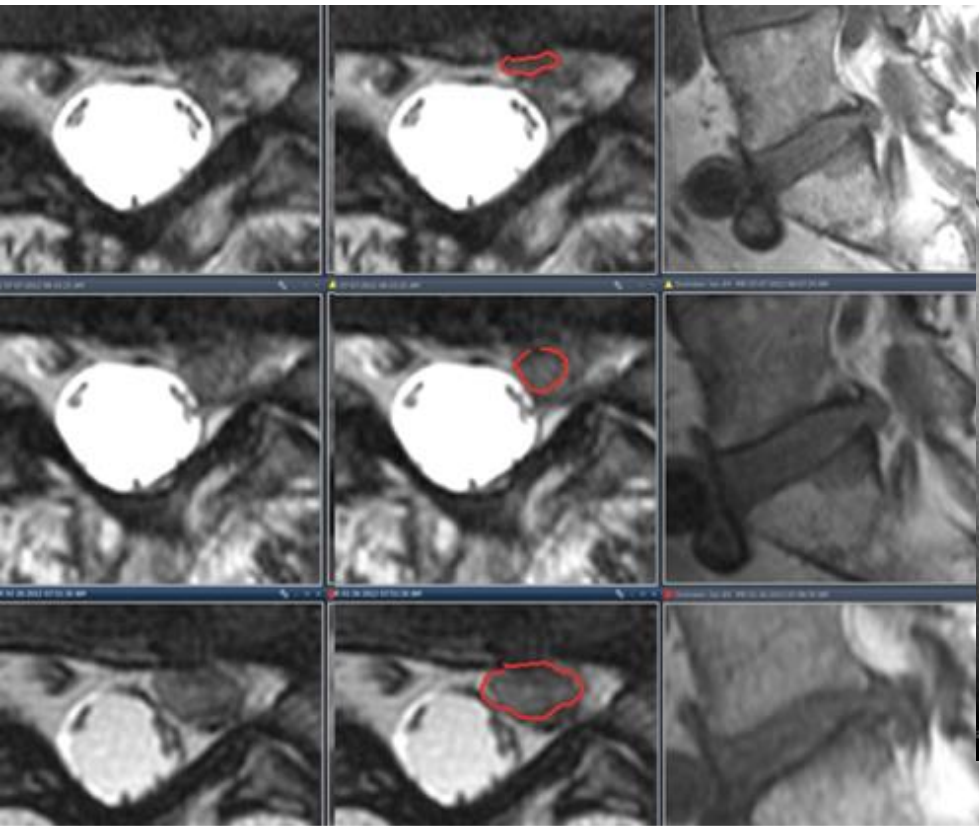






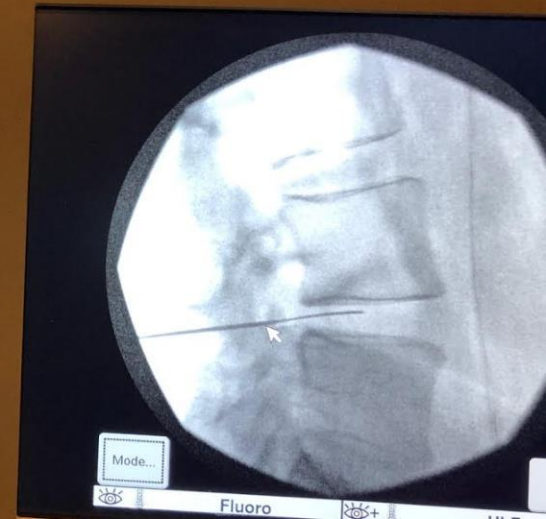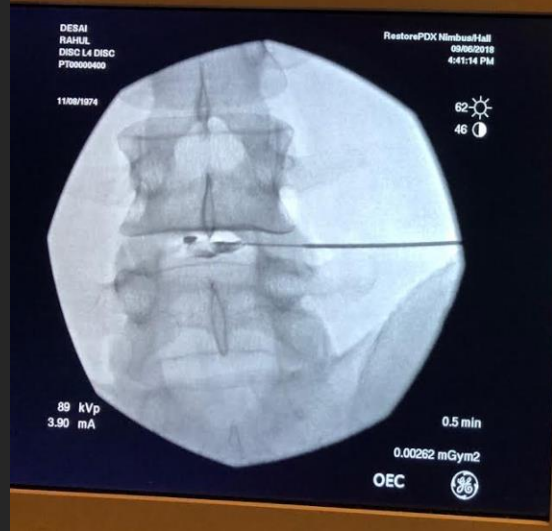


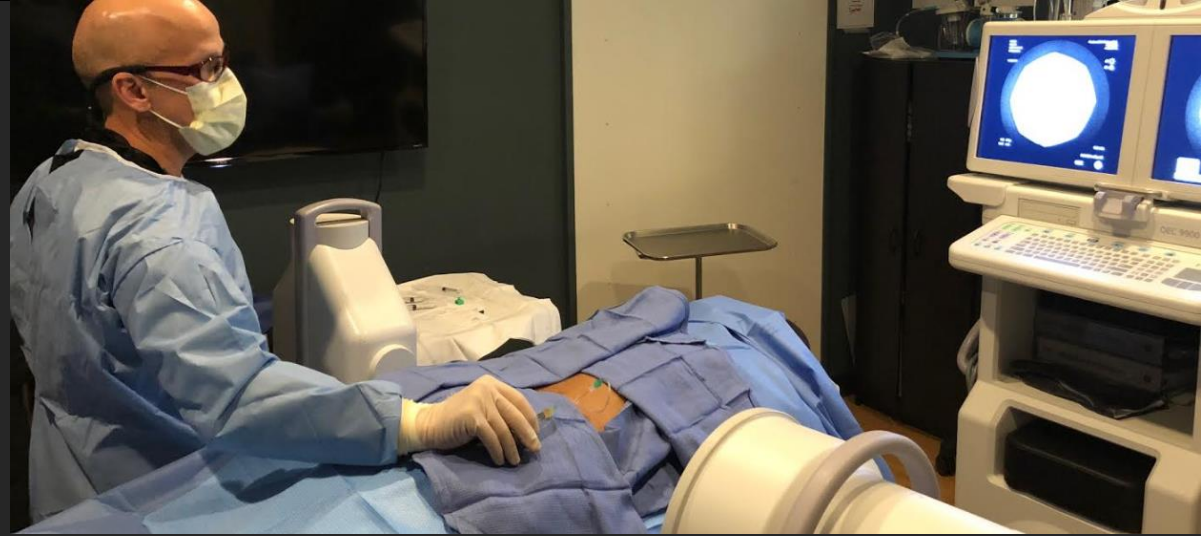Our Talk is about  
the  
**POSSIBILITIES!**

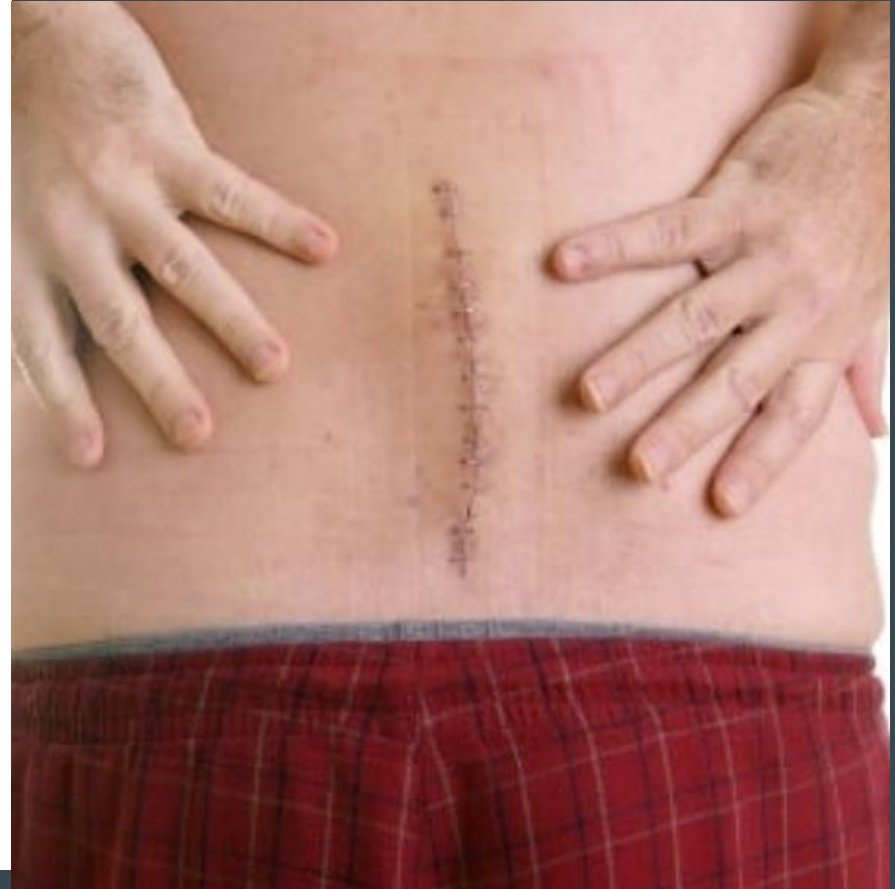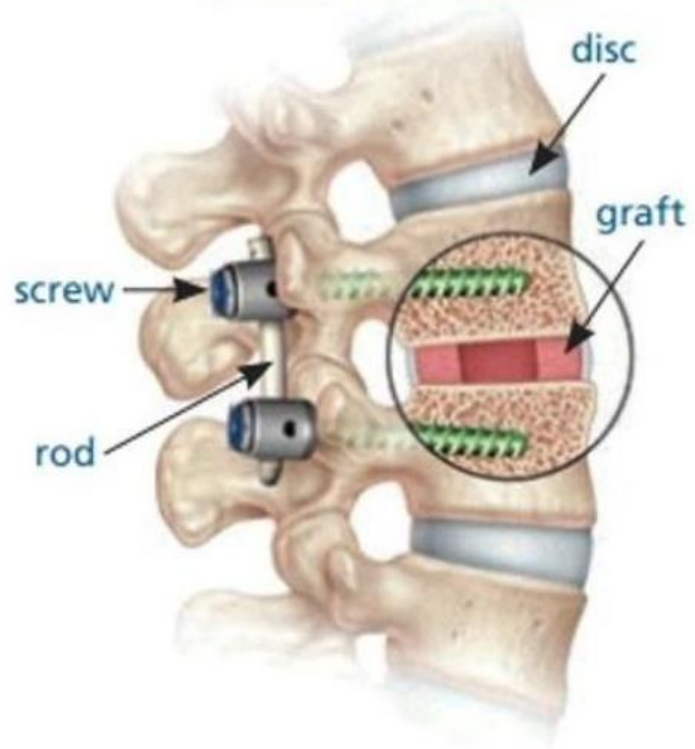


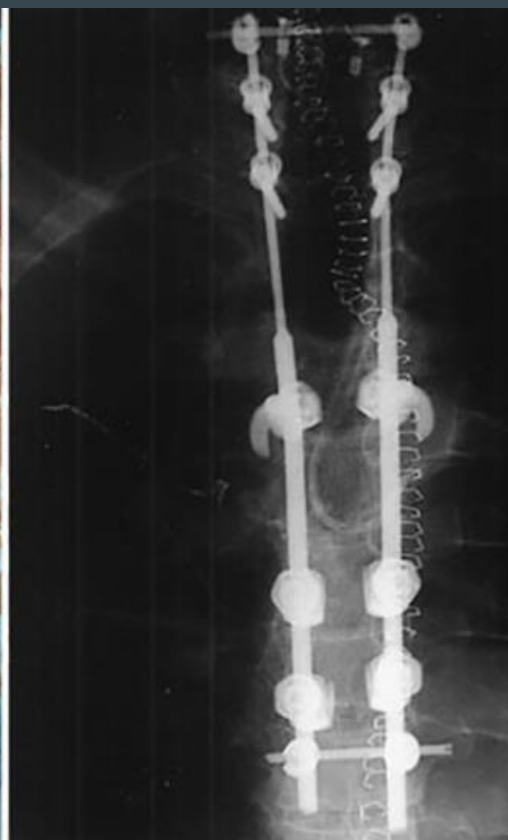
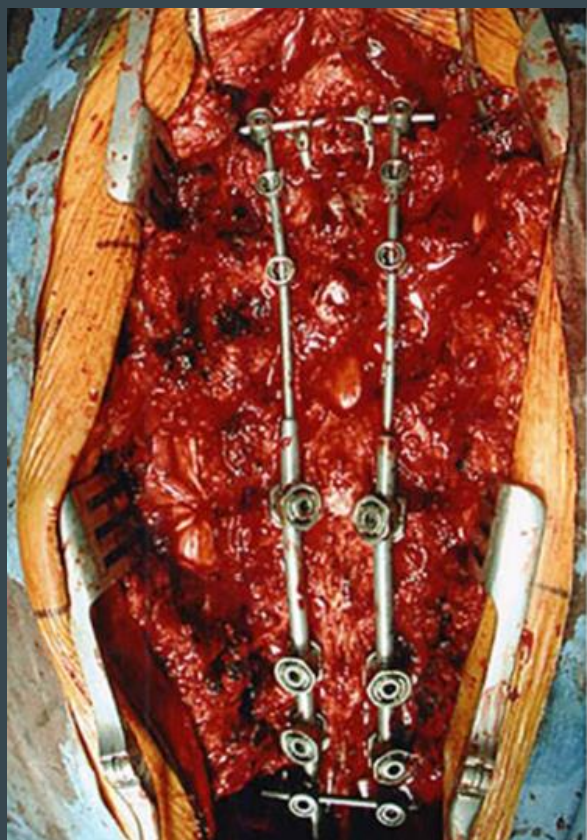
# Intra-Discal Therapy – The Game Changer

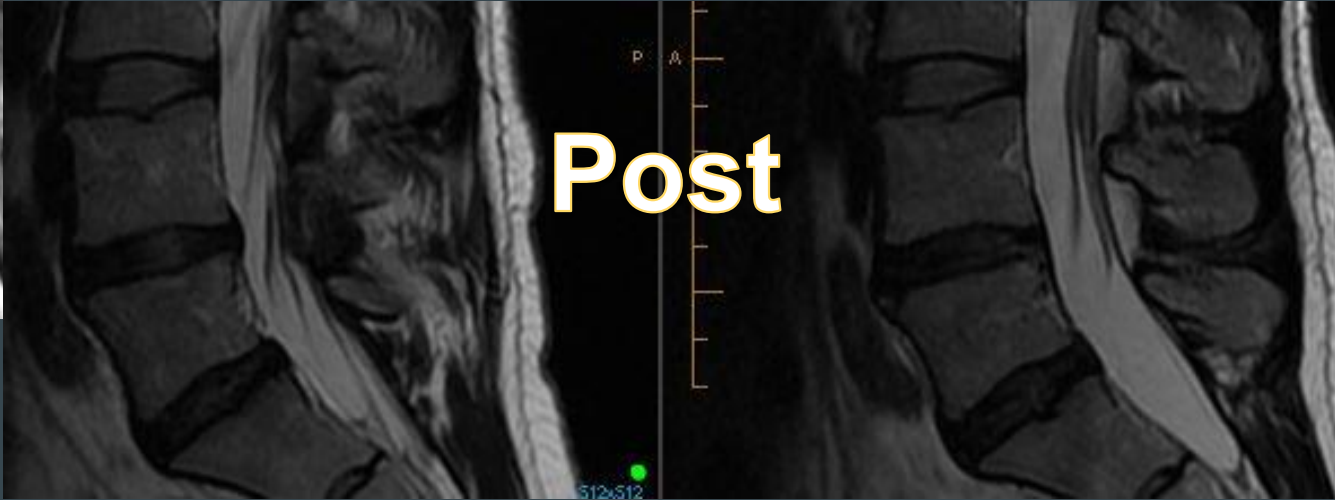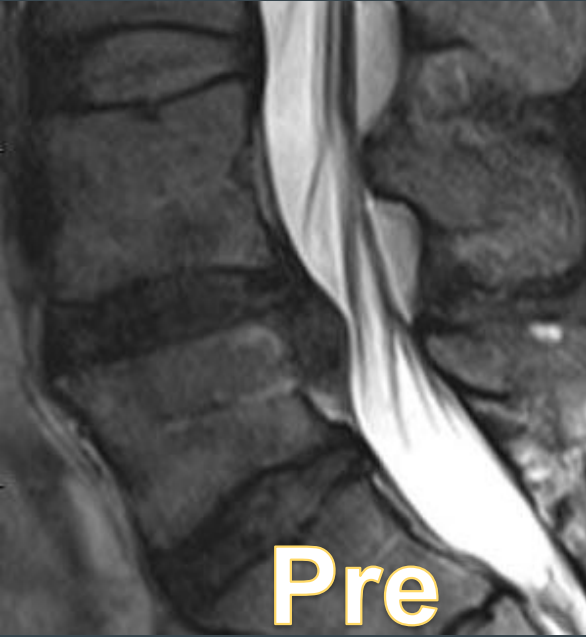---

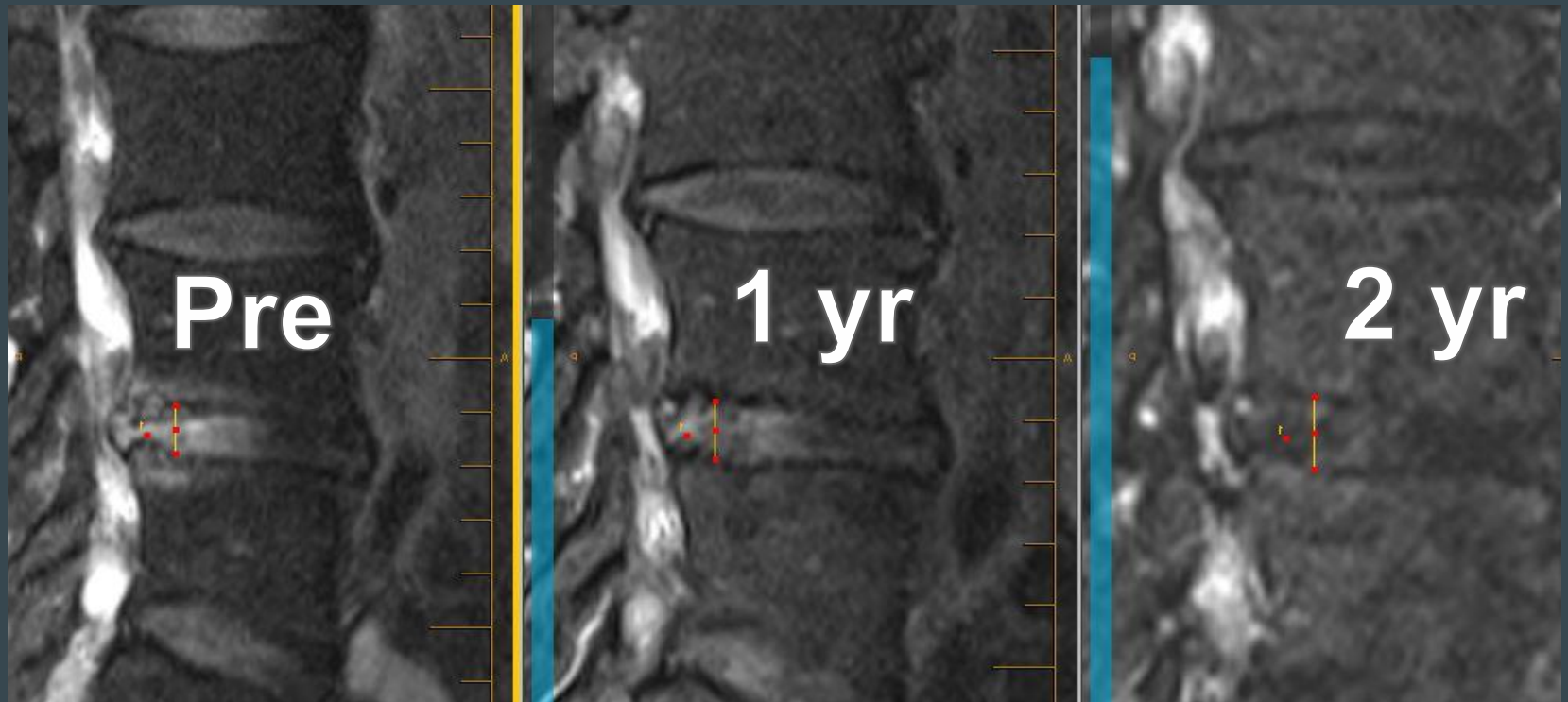


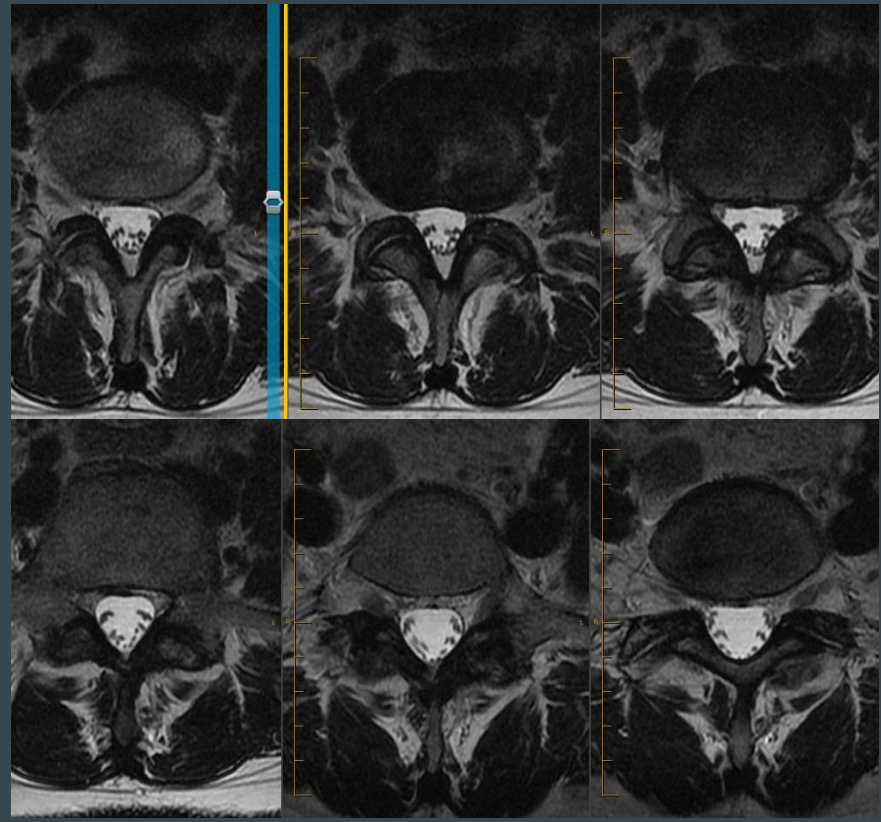
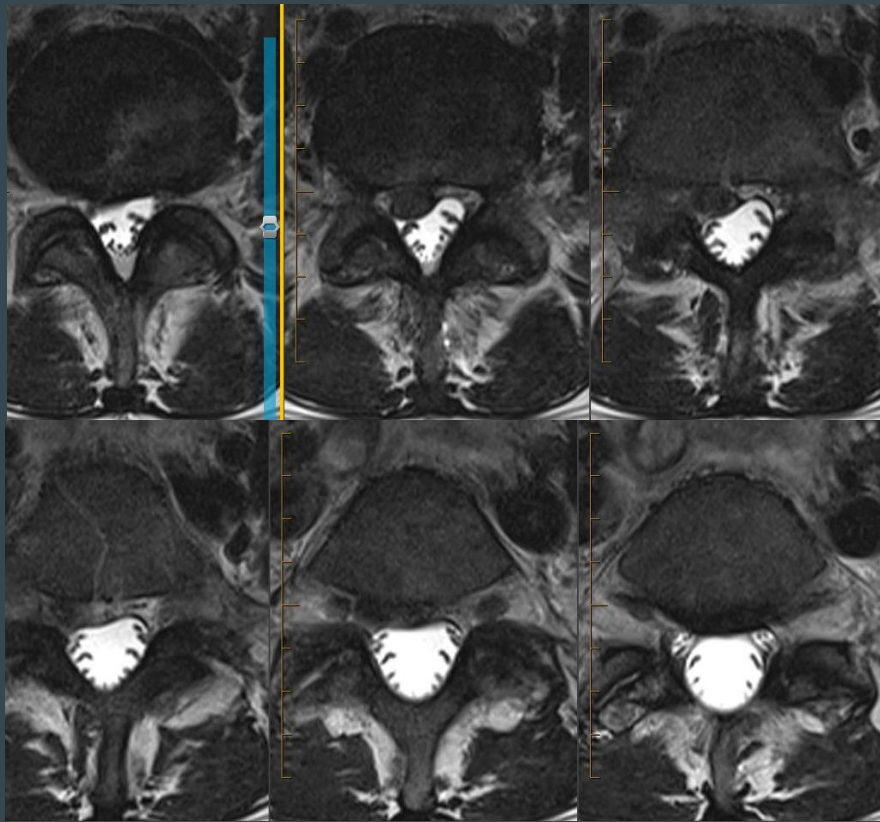
## LUMBAR FUSION

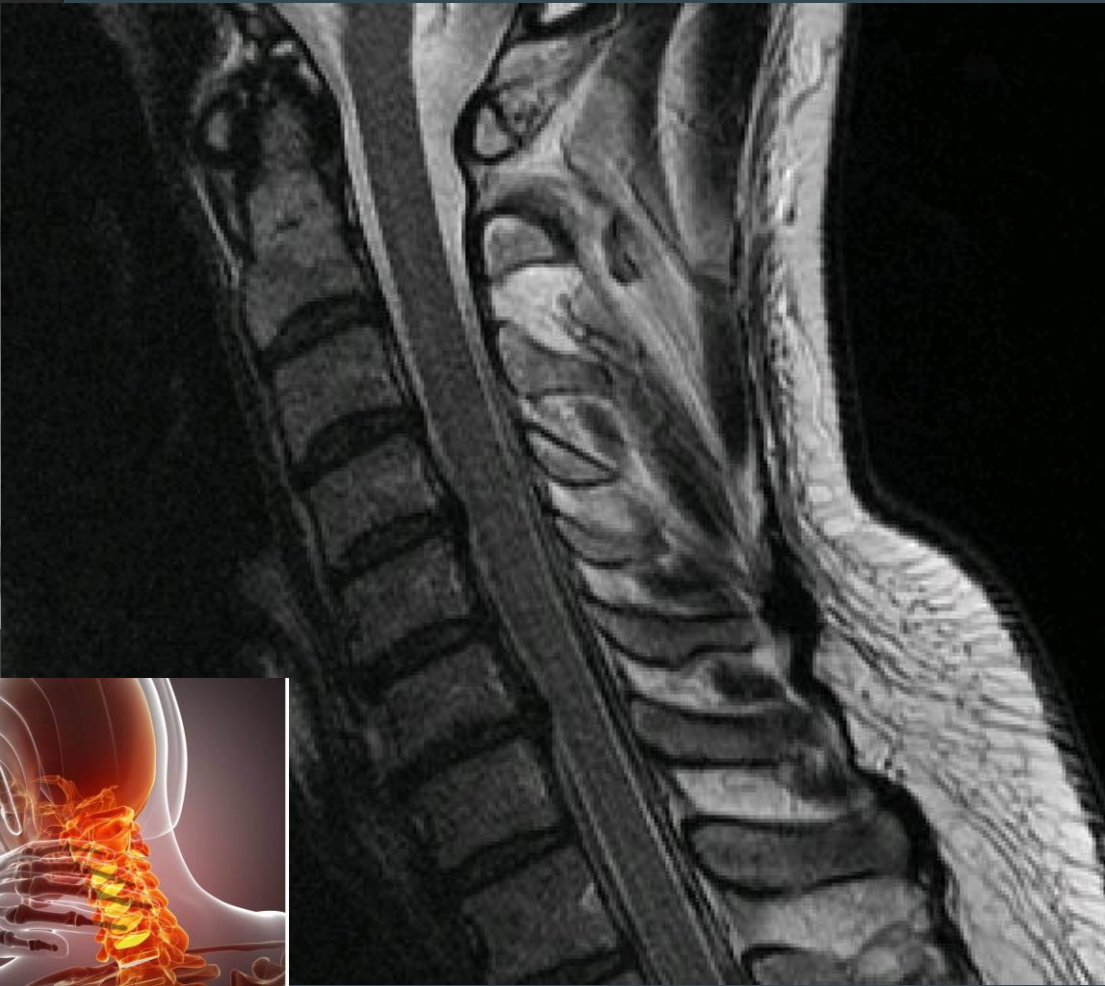
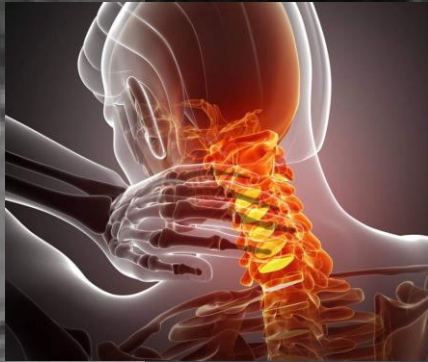
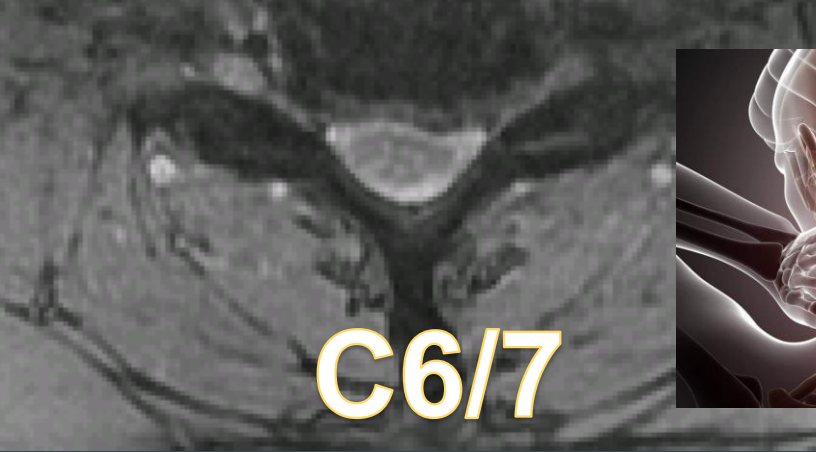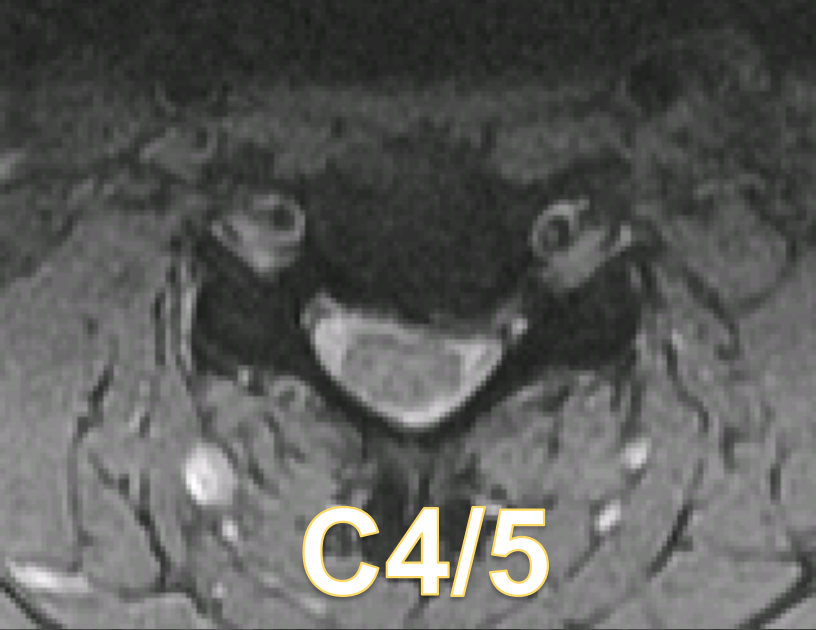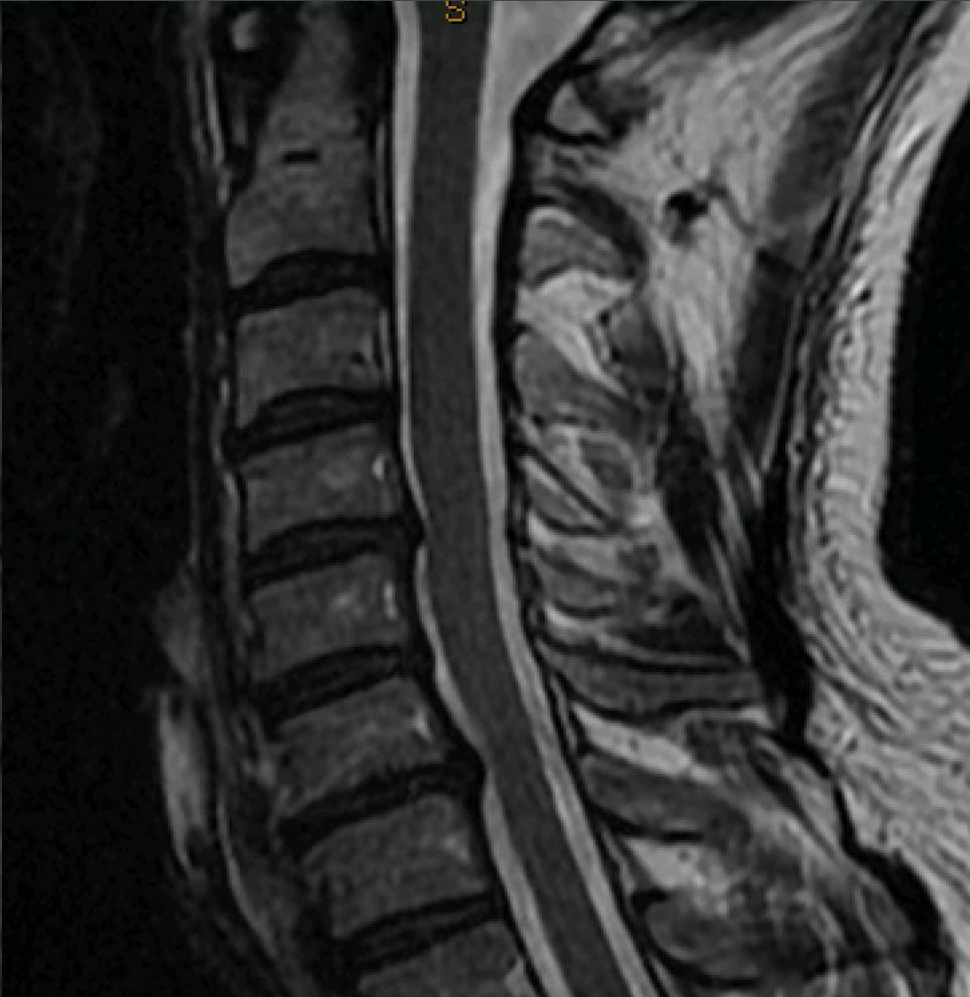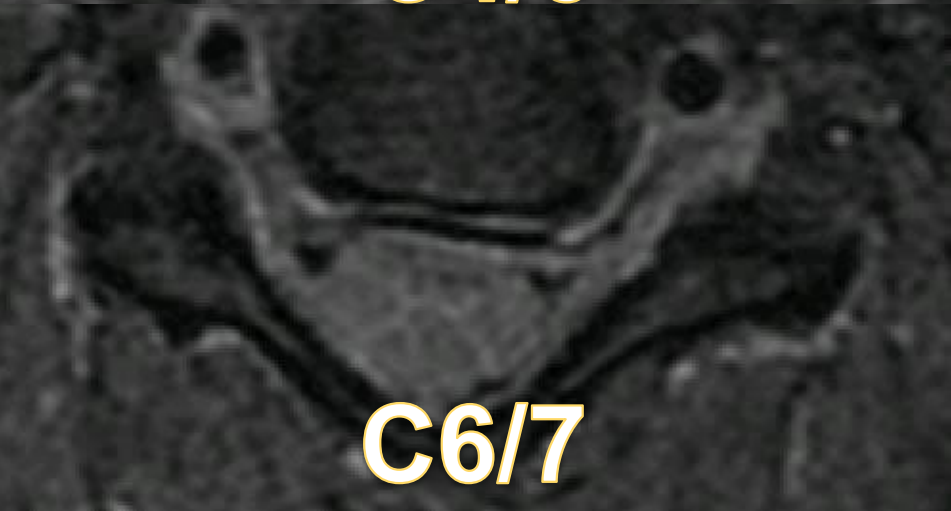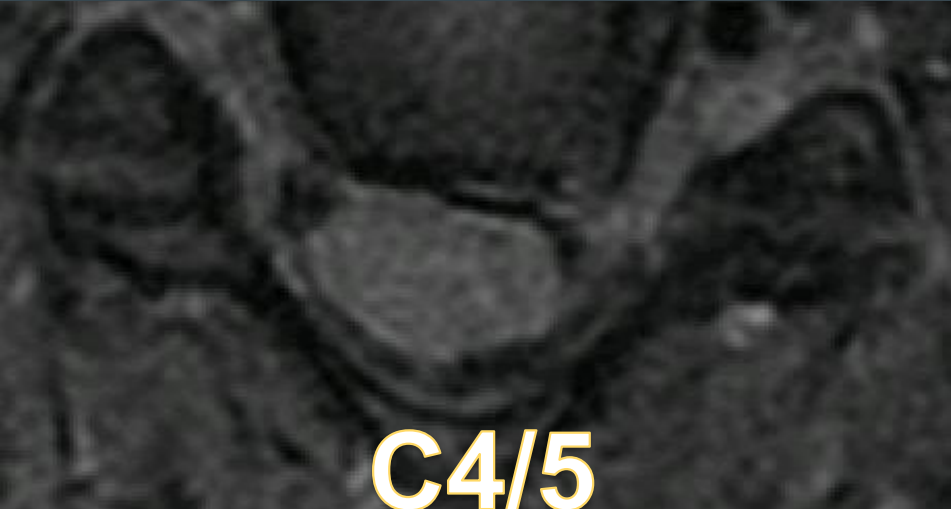


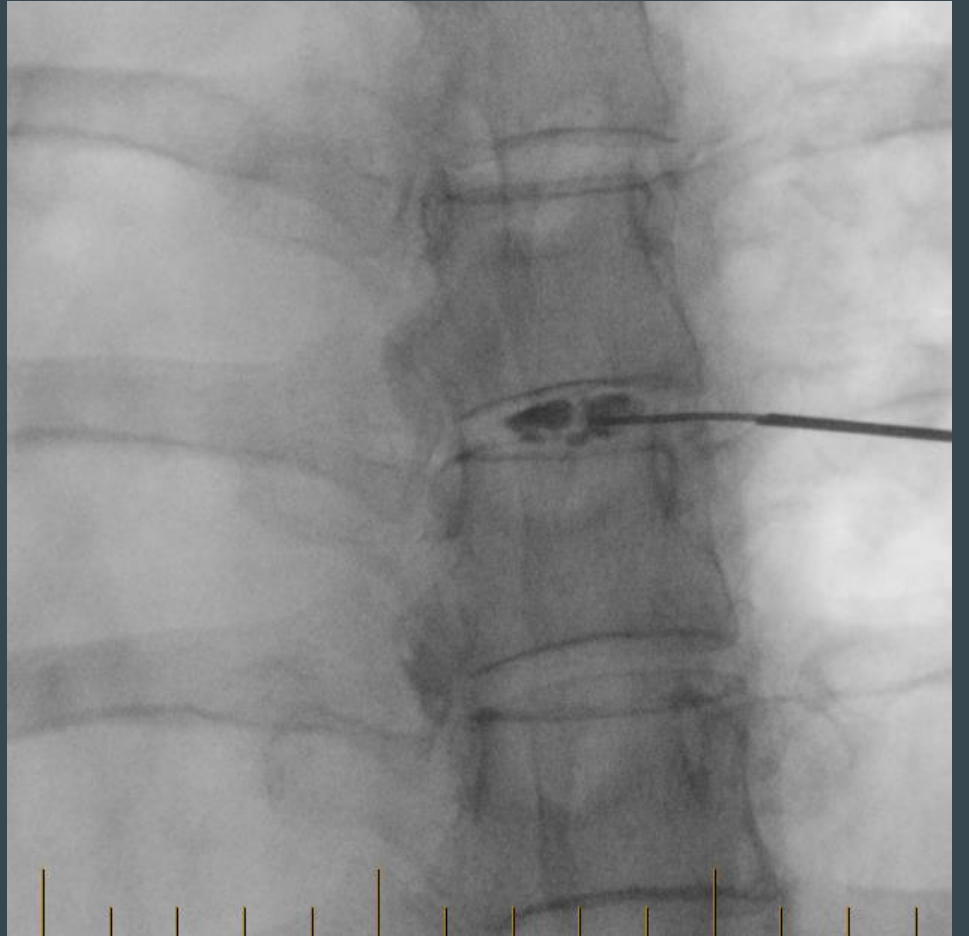
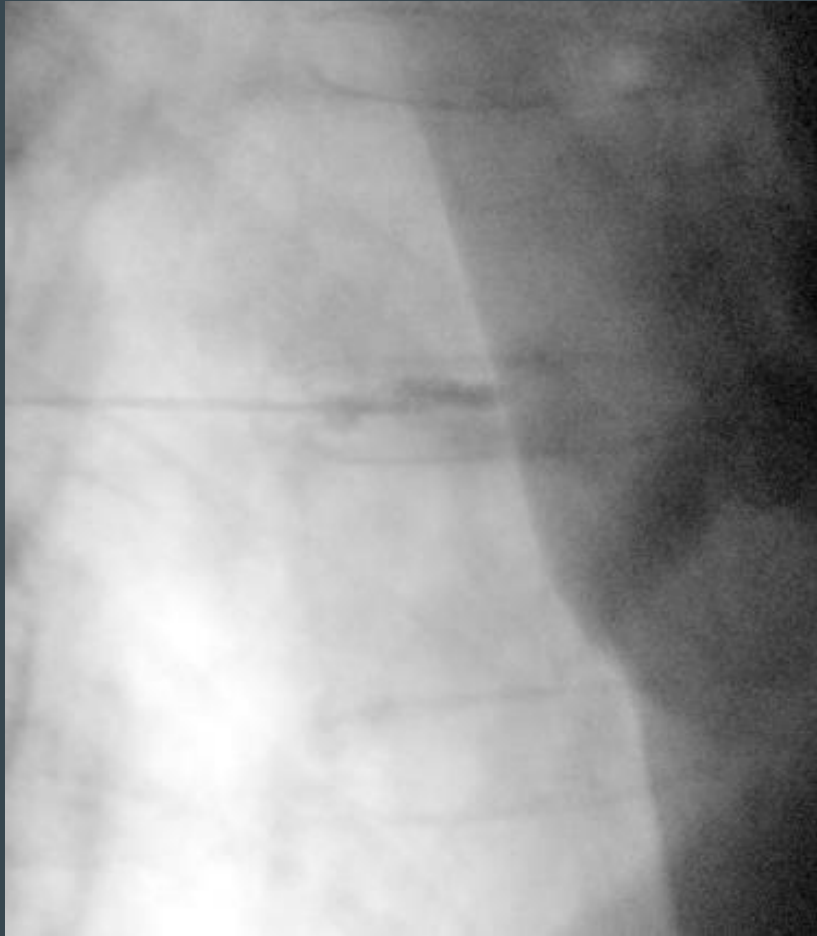










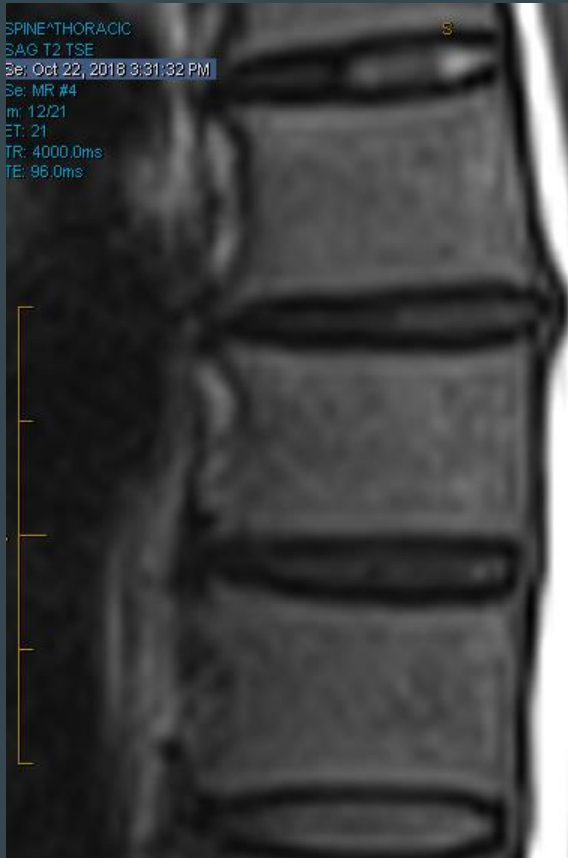

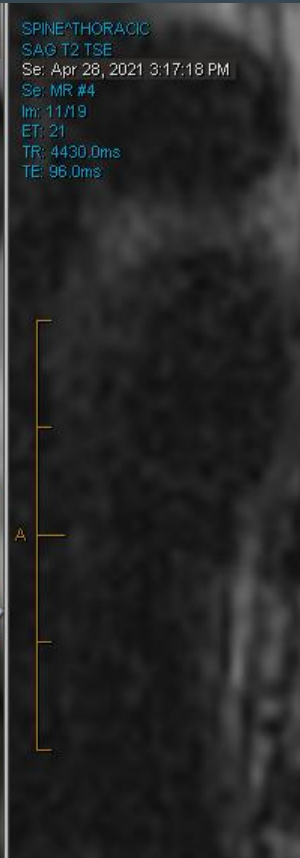
SPINE-THORACIC  
SAG T2 TSE  
Se: Oct 22, 2018 3:31:32 PM  
Se: MR #4  
m: 12/21  
ET: 21  
TR: 4000.0ms  
TE: 96.0ms



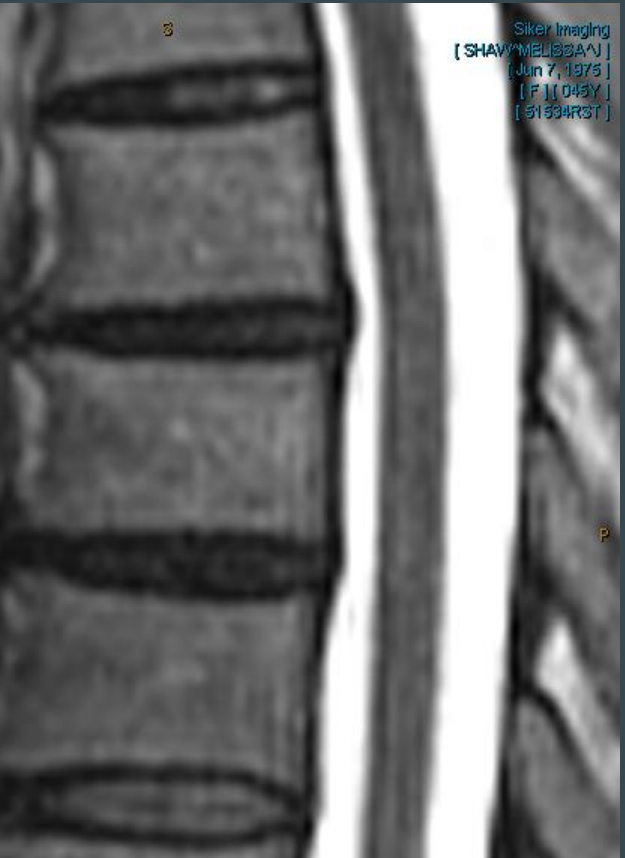Siker Imaging West  
[MELISSA\*MEISSA\*] LEWIS-HUTTON  
[Jun 7, 1975]  
[F][043Y]  
[51534RST]



SPINE-THORACIC  
SAG T2 TSE  
Se: Apr 28, 2021 3:17:18 PM  
Se: MR #4  
m: 11/19  
ET: 21  
TR: 4430.0ms  
TE: 96.0ms



Siker Imaging  
[SHAWY\*MEISSA\*]  
[Jun 7, 1975]  
[F][043Y]  
[51534RST]



# Rahul N. Desai, MD

